ISSN:0975-3583,0976-2833 VOL13,ISSUE 01,2022

Efficacy of Dexmedetomidine as an adjuvant to levobupivacaine in transverses abdominis plane block for gynaecological laparoscopic surgery-A randomised double blind study

Dr Sumita Mohanty[1], Dr Prajnyananda Das[2], Dr Asitkumar Sethi[3], Dr Sidharth Sraban Routray[4]

[1]Associate Professor, Department of Anaesthesiology, Pain and Palliative care.Acharya Harihar Postgraduate Institute of Cancer, Cuttack, Odisha,India

[2]Assistant Professor, Department of Anaesthesiology, Pain and Palliative care.Acharya Harihar Postgraduate Institute of Cancer, Cuttack, Odisha,India

[3]Associate Professor, Department of Surgery, Bhima Bhoi Medical College and Hospital, Balangir, Odisha, India.

[4]Associate Professor, Department of Anaesthesiology and critical care, S.C.B. Medical College Cuttack, Odisha,India

Corresponding author

Dr Sidharth Sraban Routray

Associate Professor,Dept of Anaesthesiology and critical care, S.C.B. Medical College Cuttack, Odisha,India

ABSTRACT

Background:α_2 agonists have been commonly used as additive to local anaesthetic agents in regional anesthesia. Transversus abdominis plane (TAP) block have been used for postoperative pain relief in abdominal surgeries.

Objectives: This trial was done to evaluate the analgesic potency of dexmedetomidine as additive to levobupivacaine in TAP block in patients after gynaecological laparoscopic surgery.

Materials and Methods: A randomised trial was done in 60 patients undergoing gynaecological laparoscopic surgery. All patients were randomised to two groups of 30 each. Group L received a total volume of 20ml of 0.25% levobupivacaine and group LD received 20 ml of 0.25% levobupivacaine with 1µg/kg dexmedetomidine in bilateral TAP block postoperatively. Time to first rescue analgesic was primary aim of our study. Secondary aims were total analgesic consumption,VAS score,hemodynmics and any complications.

Results: First analgesic demand was delayed in LD group (6.84± 0.62 hours) versus L group (3.5± 0.73hrs) which was statistically significant. Total analgesics(paracetamol) used in first 24 h was more in L group (2.9± 0.45 gm)compared to LD group(1.12± 0.6gm) which was statistically significant. VAS scores were low in LD group contrary to L group postoperatively which was statistically significant.

Conclusion: Dexmedetomidine as additive to levobupivacaine in TAP block prolongs the time to first rescue analgesic request and reduces the total analgesic used in postoperative period in gynaecological laparoscopic surgery.

Keywords: Dexmedetomidine, levobupivacaine, transverses abdominis plane block, gynaecological, laparoscopic

ISSN:0975-3583,0976-2833 VOL13,ISSUE 01,2022

INTRODUCTION

Postoperative pain is one of the worst fears of patient posted for gynaecological laparoscopic surgeries. Alleviation of postoperative pain is very important to provide early ambulation, decrease analgesic requirement, duration of hospitalization and to reduce postoperative morbidity. Many pharmacological and nonpharmacological methods are there to manage the postoperative pain but none has been found ideal.[1] In last few years transversus abdominis plane (TAP) block has been used for pain management after abdominal surgeries under general anaesthesia.[2] In a meta analysis by Sidiqui et al[3], they opined that TAP block provides prolonged analgesia and reduces the consumption of opioids in the postoperative period without any side effects. As bupivacaine is more cardio and neuro toxic, levobupivacaine, is the commonly used local anesthetic in regional anaesthesia.[4] But it has got shorter duration of action compared to bupivacaine.So adjuvants like opioids, dexamethasone, magnesium sulphate ,ketamine and dexmedetomidine have been used for prolonging the duration of blockade, but each one had its own side effects like sedation, nausea & vomiting etc.[5] α2 – adrenergic receptors agonist like dexmedetomidine have been used for its sedative, analgesic, and anesthesia sparing effects. Dexmedetomidine has proved its efficacy in prolonging the duration of local anaesthetics in various regional blocks.[6]There were few studies in literature using dexmedetomidine as additive to levobupivacaine in TAP block.Our trial was designed to measure the potency of dexmedetomidine when used as adjuvant to levobupivacaine in TAP block for pain management. Time to first rescue analgesic request was primary aim of our trial. Secondary aims were total analgesic consumption,VAS score,sedation and any complications.

MATERIALS AND METHODS

After approval from the institutional ethical committee, written informed consent from the patients were obtained. This prospective, randomized trial was done on 60 patients of ASA I & II, which were posted for lower abdominal gynecological surgeries at SCB medical college, Cuttack, Odisha from Aug 2019 to Nov 2021. Patient refused for inclusion, any history of allergy to local anaesthetic or dexmedetomidine, BMI >25kg/m^2,coagulation disorders, pregnancy, chronic renal diseases and local block site infection were excluded from the study. The study population were randomly divided using computer generated randomization in to 2 groups of 30 patients in each group. Allocation concealment was done by serially numbered opaque envelop method. Group L received 20 ml of levobupivacaine 0.25% and group LD received 20 ml of levobupivacaine0.25% + (1 µg/kg dexmedetomidine diluted upto 1ml of normal saline. During pre anaesthetic check up, patients were assessed for any illness and all required laboratory investigations were checked.TAP block procedure and visual analog scale(VAS) for pain assessment was explained to all the patients. The patients were given Tab Alprazolam 0.5 mg and Tab Ranitidine 150 mg at bed time on the night before surgery. Baseline pulse rate ,blood pressure and SPO2 were recorded. 18 G IV cannula was put and Ringers Lactate was started..All patients received standard general anaesthesia in supine position. Patients were premedicated with inj Glycopyrrolate 0.005mg/Kg IV, Inj Midazolam 0.05 mg/Kg IV and Inj Pentazocin 0.5 mg/Kg IV. Anesthesia was induced with Inj Propofol 2 mg/Kg IV and endotracheal intubation facilitated with Inj Vecuronium 0.1 mg/Kg IV. Anaesthesia was maintained with N2O,O2 and Isoflurane and surgery was allowed. At the end of surgery, TAP block was given using midaxillary approach in all patients. A high –frequency (5-10MHz) ultrasound linear probe was transversely located on the anterolateral abdominal wall in mid axillary line between the lower costal margin and the iliac crest. Neurovascular plane

ISSN:0975-3583,0976-2833 VOL13,ISSUE 01,2022

between the internal oblique and transverse abdominis muscle were identified. A 50 mm nerve block needle was introduced in the plane of ultrasound probe directly under the probe and advanced until it reaches the plane between internal oblique and transverse abdominis muscle. After negative aspiration study drug was injected. The study drug was observed on ultrasound to be distributed in a dark oval form and the plane appears as hypoechoic space. Then residual block was reversed with Inj Neostigmine 0.05mg/kg IV & Inj Glycopyrrolate 0.01mg/kg. After extubation, patients were transferred to the post anesthesia care unit (PACU). Time to request first analgesics, rescue analgesia requirements were recorded. Heart Rate (HR), MAP(mean arterial pressure) and SPO2 were assessed. Assessment of pain was done on visual analogue scale "VAS" (0=no pain and 10= worst possible pain). All the patients were administered IV Paracetamol (15mg/kg) as rescue analgesic when postoperative VAS score > 4 . It was recorded at 20min,40min,1hr,3hr,6hr,9hr,12hr,15hr,18hr,21hr and 24th hr in postoperarative period. All the patients sedation was assessed using Ramsay Sedation Score. Any complications like post operative nausea and vomiting were recorded. A MAP decrease of more than 20 percent from the baseline was taken as hypotension which was managed by reducing isoflurane concentration and injecting ephedrine 6mg iv. Heart rate less than 60 beats per minute was considered to be bradycardia, and 0.6 mg of atropine IV was administered in such cases. Sample size calculation was based on an initial pilot study involving ten patients with 'time needed for first rescue analgesic' as the primary end point of the study. Time to first analgesic request was 3.29 ± 0.51hrs in levobupivacaine group and 6.72 ± 0.49 hrs in levobupivacaine-dexmedetomidine group. With Ω± error of 0.05 and power of the study ($1- \Omega^2$) at 80%, to detect a minimum of 120 min difference in time needed for rescue analgesia between the two groups, the sample size was calculated to be approximately 28 in each group. We included thirty patients in each group to compensate for possible dropouts. The patients, who were part of the pilot study, were not included in the study. The patients' characteristics and block profile were categorized and analyzed appropriately using student's unpaired *t*-test and Chi-square test. A $P < 0.05$ was considered as statistically significant.

ISSN:0975-3583,0976-2833 VOL13,ISSUE 01,2022

RESULTS

Figure 1- flow chart of the study

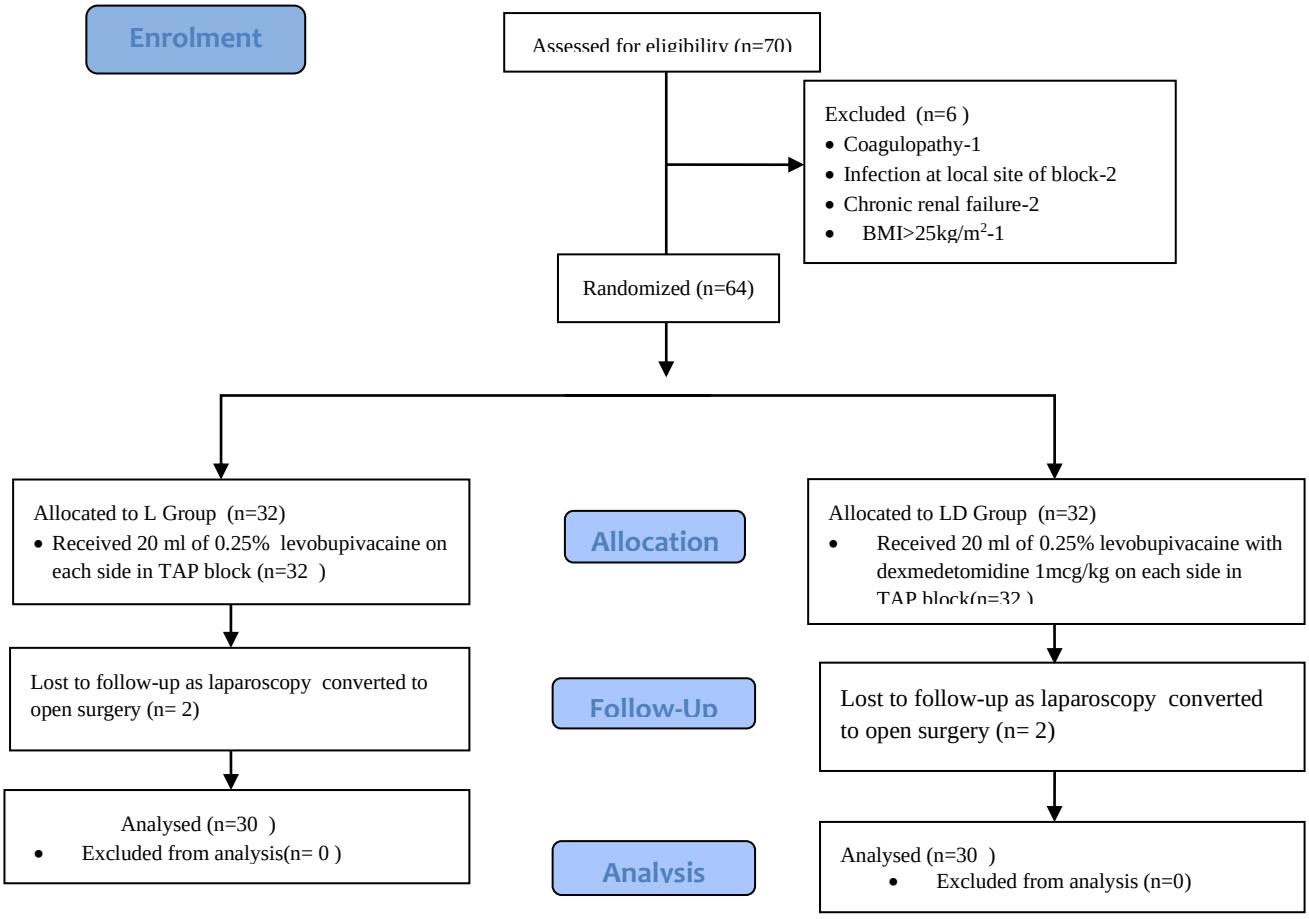

70 patients enrolled for gynaecological laparoscopic surgery were examined for eligibility. 6 patients were excluded for not fulfilling the inclusion criteria. 64 patients were enrolled in the study, out of which 2patients of each group were excluded again from analysis as they were converted to open surgery.(Fig1)The demographic profile, block performing time and duration of surgery were similar in both the groups. (Table1)The mean time to first analgesic request 3.5± 0.73hours hours in group L and 6.84± 0.62 hours in group LD.($P < 0.05$) The total dose of paracetamol consumed in 24 hours was2.9± 0.45 gm in group L group and 1.12± 0.6gm in group LD.($P < 0.05$) (Table 2)At different time intervals, VAS scores were significantly lower in the Group LD compared to the group L. ($p < 0.05$)(Table 3) There was no remarkable difference regarding nausea, vomiting, and sedation between the two groups. (Table 4)

ISSN:0975-3583,0976-2833 VOL13,ISSUE 01,2022

Table 1: Descriptive variables of groups.

Variables	Group L(n=30)	Group LD(n=30)	P value
Age(years)	56.36±13.83	54.21±12.96	0.217
ASA I/II (n)	25/5	24/6	0.221
Surgical time (mins)	92.47±21.28	94.33±22.16	0.198
Block performing time (mins)	8.22±1.37	9.13±1.52	0.176
BMI (kg/m^2)	23.86±1.12	22.78±2.12	0.182

Values expressed as Mean±SD and No, SD: Standard deviation. Student's t-test and Chi-square test applied. P<0.05 is significant

Table 2: Total analgesic consumption in 24 hrs and time to first analgesia request

Parameters	Group L(n=30)	Group LD(n=30)	P value
Time to 1st rescue analgesia request (hrs)	3.5± 0.73	6.84± 0.62	0.026
Total analgesic consumption(Paracetamol in gm)	2.9± 0.45	1.12± 0.6	0.029

Values expressed as Mean±SD, SD: Standard deviation. Student's t-test and Chi-square test applied. P<0.05 is significant

Table 3: Post operative VAS scores

Times of Measurement	Group L(n=30)	Group LD(n=30)	P value
20th min	1.19±1.23	1.45±1.12	0.127
40th min	1.43±1.57	1.67±1.37	0.156
1st h	1.59±1.11	1.88±1.69	0.174
3rd h	2.78±1.98	1.94±1.72	0.012
6th h	2.99±2.13	2.64±1.86	0.035
9th h	2.68±1.83	2.88±1.66	0.152
12th h	2.75±1.59	2.49±1.48	0.126
15th h	2.88±1.79	2.74±1.53	0.182
18th h	2.59±1.86	2.91±1.83	0.145
21st h	2.77±1.94	2.95±1.92	0.128
24th h	3.37±1.22	3.11±1.45	0.137

Values expressed as Mean±SD, SD: Standard deviation.

Table 4:Incidence of PONV and sedation

	GroupL (n=30)	Group LD (n=30)	P value
Nausea	2	2	0.219
Vomiting	1	1	0.247
Sedation	3	4	0.278

ISSN:0975-3583,0976-2833 VOL13,ISSUE 01,2022

DISCUSSION

Our study concluded that dexmedetomidine when used as adjuvant to levobupivacaine in TAP block produced prolonged analgesia,low VASscoreand reduced total requirement of rescue analgesic in postoperative period compared to levobupivacaine alone with fewer side effects. In a systematic review and meta-analysis, Abdallah et al.[7] studied the effect of TAP block on intravenous morphine consumption in the post operative period. They concluded that morphine consumption was reduced, VAS pain scores were low with prolonged analgesia in the TAP block. McDonnell et al.[8] studied efficacy of transversus abdominis plane(TAP) block in ceserian section on postoperative analgesia. They found low VAS scores,low total morphine requirement and lower incidence of sedation, in postoperative period.Singh et al, [9] used clonidine as adjuvant to bupivacaine for TAP block in cesarean delivery. They opined that, clonidine produced prolonged postoperative analgesia, lower consumption of rescue analgesia with higher satisfaction score compared to bupivacaine alone. Neethirajan et al.[10] in his study opined that the addition of dexmedetomidine to bupivacaine in TAP block delayed the requirement of rescue analgesia, and reduced rescue analgesic consumption in comparison with bupivacaine alone which was similar to our study.In another study, Chen et al,[11] analysed the analgesic efficacy of dexmedetomidine and fentanyl when added to ropivacaine as adjuvant in TAP block elective gynecological patients. They opined that dexmedetomidine provided prolonged postoperative analgesia along with better recovery compared to fentanyl. Almarakbi et al,[12] in his study of TAP block in abdominal hysterectomy found that dexmedetomidine as adjuvant to bupivacaine produced lesser VAS score and prolonged analgesia in comparison to bupivacaine alone in postoperative period which is in agreement with our study.Shehab et al,[13] in his trial of TAP block in abdominal and pelvic cancer surgery, revealed that dexmedetomidine with bupivacaine in TAP block provided prolonged analgesia and reduced analgesic consumption postoperatively which was in agreement with our study. Ramya et al,[14] studied TAP block after cesarean section and opined that the addition of dexmedetomidine as additive to bupivacaine in TAP block delayed the 1st request of analgesia.It also produced low VASscore and reduced the opioid requirement in the postoperative period which was in agreement with our study.Aksu et al.[15] studied the effect of dexmedetomidine as adjuvant to bupivacaine in TAP blockin abdominal surgery and opined that dexmedetomidine provided low VAS score in the 1st 8 hours after surgery. Dexmedetomidine also reduced the requirement of rescue analgesia in this period without any side effects which was in agreement with our study.Therefore, dexmedetomidine can be a effective adjuvant with levobupivacine in transversus abdominis plane(TAP) block for effective and prolonged analgesia postoperatively in gynecological laparoscopic surgeries.

Conclusion

Dexmedetomidine when used as additive to levbupivacaine in TAP block in gynecological laparoscopic surgeries delayed the time to 1st rescue analgesia requirement and reduced total analgesic consumption during postoperative 24 hours without any side effects.

References

1. Prabhakar A, Mancuso KF, Owen CP, Lissauer J, Merritt CK, Urman RD, et al. Perioperative analgesia outcomes and strategies. Best Pract Res Clin Anaesthesiol 2014;28:105-15.

2. Petersen PL, Mathiesen O, Torup H and Dahl JB. The transversus abdominis plane block: Avaluable option for postoperative analgesia? A topical review. Acta Anaesthesiol Scand 2010;54:529-35.
3. Siddiqui MR, Sajid MS, Uncles DR, Cheek L, Baig MK. A meta-analysis on the clinical effectiveness of transversus abdominis plane block. J Clin Anesth 2011;23:7-14.
4. Acharya R, Baksi R, Mohapatra P. Comparative analysis of duration of postoperative analgesia between levobupivacaine and levobupivacaine with clonidine after ultrasound-guided transversus abdominis plane block in patients undergoing lower segment cesarean section. Anesth Essays Res. 2018;12(4):943–8.
5. Imani F, Zaman B, De Negri P. Postoperative pain management: Role of dexmedetomidine as an adjuvant. Anesth Pain Med. 2021;10(6):e112176.
6. Xue Y, Yuan H, Chen Y. Effects of dexmedetomidine as an adjunct in transversus abdominis plane block during gynecological laparoscopy. Exp Ther Med. 2018;16(2):1131–6.
7. Abdallah FW, Halpern SH, Margarido CB. Transversus abdominis plane block for postoperative analgesia after caesarean delivery performed under spinal anaesthesia? A systematic review and meta-analysis. Br J Anaesth 2012;109:679-87.
8. McDonnell JG, Curley G, Carney J, Bentone A, Costello J, Maharaj CH, et al. The analgesic efficacy of transversus abdominis plane block after cesarean delivery: A randomized controlled trial. Anesth Analg 2008;106:186-91.
9. Singh R, Kumar N, Jain A, Joy S. Addition of clonidine to bupivacaine in transversus abdominis plane block prolongs postoperative analgesia after cesarean section. J Anaesthesiol Clin Pharmacol 2016;32:501-4.
10. Neethirajan SGR, Kurada S, Parameswari A. Efficacy of dexmedetomidine as an adjuvant to bupivacaine in ultrasound-guided transverse abdominis plane block for laparoscopic appendicectomy: A randomised controlled study. Turk J Anaesthesiol Reanim. 2020;48(5):364–70.
11. Chen Q, Liu X, Zhong X, Yang B. Addition of dexmedetomidine or fentanyl to ropivacaine for transversus abdominis plane block: evaluation of effect on postoperative pain and quality of recovery in gynecological surgery. J Pain Res. 2018;11:2897-2903.
12. Almarakbi WA, Kaki AM. Addition of dexmedetomidine to bupivacaine in transversus abdominis plane block potentiates post-operative pain relief among abdominal hysterectomy patients: A prospective randomized controlled trial. Saudi J Anaesth. 2014;8(2):161–6.
13. Shehab NN, El-Helaly MK, Ghoneim AA, Nabih GM. Comparative study between bupivacaine versus bupivacaine with dexmeditomidine in ultrasound guided transversus abdominis plane block for postoperative analgesia in cancer patients undergoing major pelviabdominal surgeries. Med J Cairo Univ. 2018;86(6):1955–62.
14. Ramya Parameswari A, Udayakumar P. Comparison of efficacy of bupivacaine with dexmedetomidine versus bupivacaine alone for transversus abdominis plane block for post-operative analgesia in patients undergoing elective caesarean section. J Obstet Gynaecol India. 2018;68(2):98–103.
15. Aksu R, Patmano G, Bicer C, Emek E, Coruh AE. Efficiency of bupivacaine and association with dexmedetomidine in transversus abdominis plane block ultrasound guided in postoperative pain of abdominal surgery. Rev Bras Anestesiol. 2018;68(1):49–56.