ISSN:0975-3583,0976-2833 VOL13,ISSUE02,2022

Original research article

Evaluation of pre-contoured LCP in the fixation of fracture of shaft of the clavicle-a prospective study

[1]Dr. Shivanna, [2]Dr. Manoj Bhagirathi Mallikarjuna swamy, [3]Dr. Krishnaprasad HS,[4]Dr. Yogesh, [5]Dr. Mahadevaprasad

[1]Associate Professor, Department of Orthopaedics, Chamarajanagar Institute of Medical Sciences, Chamarajanagar, Karnataka, India

[2,3]Assistant Professor. Department of Orthopaedics, Chamarajanagar Institute of Medical Sciences, Chamarajanagar, Karnataka, India

[4,5]Senior Resident, Department of Orthopaedics, Chamarajanagar Institute of Medical Sciences, Chamarajanagar, Karnataka, India

Corresponding Author:
Dr. Shivanna

Abstract

Background: To evaluate the outcomes of pre-contoured locking compression plate (LCP) in the fixation of midshaft fractures of the clavicle.

Methods: Sixty patients with fracture in the shaft of clavicle were treated by internal fixation with pre-contoured Locking compression plate. The radiological inion and clinical outcome results were evaluated according to the Quick Disability of the Arm, Shoulder and Hand (DASH) score.

Results: The mean time of 8.6 weeks was observed for the union. The mean score to Quick DASH was 18.17 points which was assessed at 6months follow up which reduced to 6.81 at the end of 1 year. Minimal complications were observed were superficial infection in 2 patients, terminal restriction of ipsilateral shoulder abduction was observed in 2 patients and pain in the ipsilateral shoulder joint was found in 3 patients.

Conclusions: This study showed that the patients with fracture of the shaft of the clavicle who were operated with pre-contoured locking compression plate had better radiological and clinical outcome. This study can be compared with other clinical studies which used Reconstruction plates, and other implants for the fixation of fractures of the shaft of clavicle and it can be concluded that the pre-contoured locking compression plates are the gold standard implants for the treatment of fracture of shaft of clavicle in the adults irrespective of the amount of comminution.

Keywords: Reconstruction plate, locking compression plate, clavicle, fracture

Introduction

Clavicle fractures accounts for 5% of all fractures in adults and about 44% of all shoulder fractures[1-3]. Undisplaced fractures at the midshaft of the clavicle have been usually treated with conservative measures[4,5]. However, fractures resulting from high energy injuries, such as motor vehicle accidents, industrial accidents and sporting injuries, the displaced, comminuted fractures were treated operatively to prevent shortening or angular deformities that can cause constant pain and the importance of obtaining functional satisfaction with early exercise has been emphasized[6,7]. Various methods for treating clavicle midshaft fractures, such as intramedullary K-wires or TENS fixation and plate fixation have been used[8-11]. Plate fixation can help to obtain firm anatomical reduction in severely displaced or comminuted fracture. Various plates being used were Sherman plates, dynamic compression plates and semi-tubular plates and reconstruction plates. This study analysed the clinical and radiological outcomes of the pre-contoured Locking Compression Plates for clavicle midshaft fractures in adult patients along with its efficacy.

Methods

Between January 2017 and December 2020, sixty cases of an open reduction and internal fixation with a pre-contoured LCP were performed for clavicle midshaft fractures. There were 42 males and 18 females with a mean age of 38.0 years (range, 20 to 70 years). The cause of the injury was road traffic accident in 39 cases, occupational household injuries in 9 patients, slip down in 8 cases and sports injury in 4 cases. Associated injuries were encountered in 25 cases: scapular fracture in 9 cases, haemothorax and rib fracture in 8 cases. As per Robinson's classification[12], there were 14 A2 type, 29 B1 type and 17 B2 fractures (fig 1&2). Fractures with lateral end extension and associated Acromio-Clavicular disruption were excluded from the study due to their strong influence on shoulder pain and movements of the shoulder

ISSN:0975-3583,0976-2833 VOL13,ISSUE02,2022

postoperatively. The mean interval from injury to operation was 3 days (range, 1 to 7 days). The mean follow-up period was 10 months (range, 7 to 24 months). The fractures included in this study were displaced fractures, comminuted fractures, fractures associated with scapular or humeral fractures, fractures with soft tissue interposition and associated with neuro vascular injuries.

Operative Technique and Rehabilitation: Under Inter scalene brachial plexus block, a transverse skin incision was made along the superior border of the clavicle, with meticulous soft tissue dissection fracture fragments exposed. Periosteal layer stripping was restricted only to fracture ends. Fracture reduction was then held temporarily by Allis clips and/or K wires. Pre-contoured locking compression plates with adequate working length was then placed over the reduced fracture and fixed with screws (fig 3). Inter fragmentary screws were used to fix the butterfly comminuted fragments if present. Bone grafting was not performed in any cases. After good haemostasis, wound was closed in layers with negative suction drain in place. An arm pouch was used for approximately 4 weeks after surgery, and pendulum exercise and shoulder active range of motion exercise were then started. X-rays were taken at every month postoperatively up to 3 months followed by every 3 months up to 1year. For the clinical assessment, the Quick Disability of the Arm, Shoulder and Hand (DASH) scores[13] suggested by the American Academy of Orthopedic Surgeons (AAOS) were evaluated using a patient interview and clinical examination.

Results

The patients' age, gender, cause of injury, fracture pattern, interval from injury to operation were recorded initially and follow up period, fracture union, complications and functional outcomes were recorded at each follow ups and analysed. The mean interval from injury to operation was 3 days (range, 1 to 7 days). The mean operative time was 40 minutes(range, 20 to 80 minutes). The mean follow-up period was 10 months (range, 7 to 24 months). Bony union (fig 4,5) was achieved in all cases after surgery at an average of 8 weeks (range, 5 to 14 weeks). In the clinical assessment, our study showed a mean score of 34.81 points (range,22.7 to 81.8 points). Postoperative complications observed were superficial infection in 2(3.33%) patients, terminal restriction of ipsilateral shoulder abduction was observed in 2(3.33%) patients and pain in the ipsilateral shoulder joint was found in 3(5%) patients.

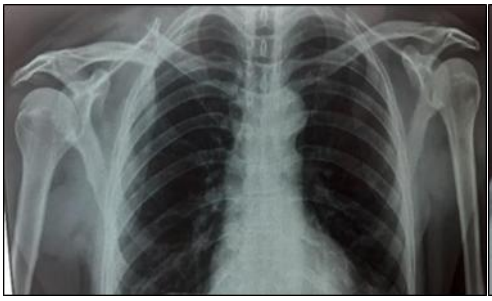

Fig 1

Fig 2

Fig 3

Fig 4

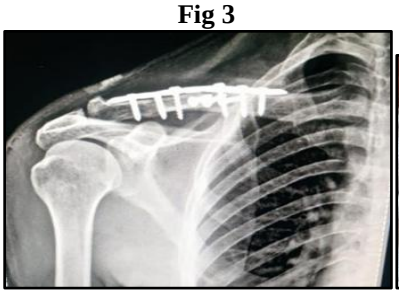

Fig 5

Fig 6

ISSN:0975-3583,0976-2833 VOL13,ISSUE02,2022

Discussion

Most of the midshaft clavicle fractures are treated conservatively by closed reduction and bracing. Neer[14]and Rowe[15],both concluded that clavicle fractures can be managed non-operatively with negligible rate of non-union. However, the extent of fragment displacement is closely associated with fracture union[12, 16]and anatomical restoration of the displacement is considered essential for successful recovery. Hence, there has been increasing trend in surgical intervention with open reduction and internal fixation. In recent times, operative treatments are preferred more often for the treatment of clavicle fractures due to the increasing incidences of displaced and comminuted fractures caused due to high velocity injuries in road traffic accidents, industrial & occupational accidents and sport injuries[6, 7].Shen *et al*. [11]and the Canadian Orthopaedic Trauma Society obtained satisfactory outcomes following surgical intervention in treating displaced clavicle midshaft fractures and reported that internal fixation with plates resulted in more rapid union, excellent clinical outcomes and lower complication rates[17]. Initially the surgical fixation for the treatment of clavicle midshaft fractures involved intramedullary K-wire or Steinmann pin and plates. The fixation using the K-wire or Steinmann pin resulted in low resistance to torque, carry risks of pin loosening and infection and require prolonged immobilization period[18, 19].Fixation with plates, such as dynamic compression plates and semi tubular plates, can be effective in achieving anatomical reduction, applying direct compression at the fracture site, and producing greater resistance to torque but these plates could be a failure in cases of severely comminuted fractures[20]. Reconstruction plates can be contoured to fit the shape of the clavicle to obtain firm fixation, but are lighter and thinner than dynamic compression plates and are vulnerable to mechanical stress imposed at the fracture site[11, 21].On the other hand, penetration of the opposite cortical bone for screw fixation may cause disastrous damage to the subclavian artery. And with these plates, a firm fixation can be difficult to maintain in osteoporotic patients over 50 years of age[23, 23].In this study, the use of Pre contoured Locking Compression plates did not result in any such complications like subclavian artery injuries or brachial plexus injuries. The main advantages of pre-contoured LCP are strong fixation due to locking between the screw and plate, and blood supply is preserved due to minimal contact between plate and cortical bone[24, 25].With conventional screws and plates, fracture site stability is provided only when the screws fixed to both the cortices. In contrast, when a Locking Compression Plate is used, a mechanical force is transferred from the cortical bone to the plate through the threaded plate hole because the screw head is firmly locked in the threaded plate hole. So, the plate need not to be compressed onto the cortical bone for stability, which results in better preservation of the blood supply[26, 27].With the use of LCPs to treat clavicle midshaft fractures, the risks of injury to the subclavian artery or brachial plexus are avoided because fixation can be achieved without the tip of the screw reaching out of the opposite bone cortex. Also, periosteal layer stripping is restricted only to fracture site so as to promote rapid union[26].The surgery time can be reduced using these pre-contoured LCPs because the plate is contoured to fit onto the curvature and bent of the clavicle. The mean score to Quick DASH was 18.17 points which was assessed at 6months follow up, which reduced to 6.81 at the end of 1 year. The longest follow up was upto 24 months. The Quick DASH score is found to better in our study compared to the previous studies which used other traditional plates to surgically fix the midshaft clavicle fractures (fig 6).

Conclusion

With the evolution of newer technologies and implants clavicle fractures which once managed conservatively mostly, are treated with the surgery now a days. Compared with the previous studies which used traditional implants to fix the clavicle midshaft fractures, the Pre-contoured Locking Compression Plates yield much better radiological and clinical outcome. In conclusion based on our study Pre-contoured Locking Compression Plates makes the implant of choice in treating displaced midshaft fractures of the clavicle irrespective of comminutions.

Conflict of interest

No potential conflict of interest relevant to this article was reported.

References

1. Johnson EW Jr., Collins HR. Non-union of the clavicle. Arch Surg. 1963;87(6):963-6.
2. Paffen PJ, Jansen EW. Surgical treatment of clavicular fractures with Kirschner wires: a comparative study. Arch Chir Neerl. 1978;30(1):43-53.
3. Richards RR, An KN, Bigliani LU, *et al*. A standardized method for the assessment of shoulder function. J Shoulder Elbow Surg. 1994;3(6):347-52.
4. Muller ME, Allgower M, Schneider R, Willenegger H. Manual of internal fixation: techniques recommended by the AO-ASIF group. 2nd ed. New York: Heidelberg, 1979, 166.
5. Stanley D, Norris SH. Recovery following fractures of the clavicle treated conservatively. Injury. 1988;19(3):162-4.
6. Lee CJ, Cho WH, Chang HG, Min BI. Operative treatment of the diaphyseal fracture of clavicle

ISSN:0975-3583,0976-2833 VOL13,ISSUE02,2022

(fresh fracture and symptomatic delayed union or non-union). J Korean Orthop Assoc. 1990;25(1):117-22.
7. Poigenfurst J, Rappold G, Fischer W. Plating of fresh clavicular fractures: results of 122 operations. Injury. 1992;23(4):237-41.
8. Chu CM, Wang SJ, Lin LC. Fixation of mid-third clavicular fractures with knowles pins: 78 patients followed for 2-7 years. Acta Orthop Scand. 2002;73(2):134-9.
9. Chuang TY, Ho WP, Hsieh PH, Lee PC, Chen CH, Chen YJ. Closed reduction and internal fixation for acute midshaft clavicular fractures using cannulated screws. J Trauma. 2006;60(6):1315-20.
10. Hill JM, McGuire MH, Crosby LA. Closed treatment of displaced middle-third fractures of the clavicle gives poor results. J Bone Joint Surg. Br. 1997;79(4):537-9.
11. Shen WJ, Liu TJ, Shen YS. Plate fixation of fresh displaced midshaft clavicle fractures. Injury. 1999;30(7):497-500.
12. Robinson CM, Court Brown CM, McQueen MM, Wakefield AE. Estimating the risk of non-union following non-operative treatment of a clavicular fracture. J Bone Joint Surg. Am. 2004;86(7):1359-65.
13. Beaton DE, Wright JG, Katz JN. Development of the Quick DASH: comparison of three item-reduction approaches. J Bone Joint Surg Am. 2005;87(5):1038-46.
14. Neer CS 2nd. Non-union of the clavicle. J Am Med Assoc. 1960;172(10):1006-11.
15. Rowe CR. An atlas of anatomy and treatment of midclavicular fractures. Clin Orthop Relat Res. 1968;58:29-42.
16. Kim SK, Kwon KW, Lee SW, Chung YS. The statistical analysis of factors influencing union of clavicle fractures. J Korean Fracture Soc. 1992;5(1):37-42.
17. Canadian Orthopaedic Trauma Society. Non-operative treatment compared with plate fixation of displaced midshaft clavicular fractures: a multicentre, randomized clinical trial. J Bone Joint Surg. Am. 2007;89(1):1-10.
18. Neer CS 2nd. Fractures of the distal third of the clavicle. Clin Orthop Relat Res. 1968;58:43-50.
19. Post M. Current concepts in the treatment of fractures of the clavicle. Clin. Orthop Relat. Res. 1989;245:89-101.
20. Lee YS, Lin CC, Huang CR, Chen CN, Liao WY. Operative treatment of midclavicular fractures in 62 elderly patients: knowles pin versus plate. Orthopedics. 2007;30(11):959-64.
21. Iannotti MR, Crosby LA, Stafford P, Grayson G, Goulet R. Effects of plate location and selection on the stability of midshaft clavicle osteotomies: a biomechanical study. J Shoulder Elbow Surg. 2002;11(5):457-62.
22. Howard FM, Shafer SJ. Injuries to the clavicle with neurovascular complications: a study of fourteen cases. J Bone Joint Surg. Am. 1965;47(7):1335-46.
23. Ring D, Perey BH, Jupiter JB. The functional outcome of operative treatment of ununited fractures of the humeral diaphysis in older patients. J Bone Joint Surg Am. 1999;81(2):177-90.
24. Haidukewych GJ. Innovations in locking plate technology. J Am Acad. Orthop Surg. 2004;12(4):205-12.
25. Perren SM. Evolution and rationale of locked internal fixator technology: introductory remarks. Injury. 2001;32(2): 3-9.
26. Gautier E, Sommer C. Guidelines for the clinical application of the LCP. Injury. 2003;34(2):B63-76.
27. Wagner M. General principles for the clinical use of the LCP. Injury. 2003;34(2):B31-42.