

Unusual Case of Congenital Aneurysm of Proximal Pulmonary Artery Causing Lung Collapse

Lt Col Sunita Dashottar¹, Col Ajay Kumar Singh*², Lt Col Virender Suhag³, Lt Col Sunita BS⁴, Brig (retd) Rajkumar Singh⁵

¹Department of Radio-diagnosis, Military hospital (Cardiothoracic Centre), affiliated to Armed Forces Medical College (AFMC), Pune, India

²Department of Radio-diagnosis, Army hospital R & R, Delhi, India

³Department of radiation Oncology, Army hospital R & R, Delhi, India

⁴Department of pathology, Base Hospital, Delhi Cantt, India

⁵Associate Professor in Anaesthesia, Udaipur, India

ABSTRACT

Pulmonary artery aneurysm is rare condition in neonates which usually presents with compression on the surrounding vital structures. By definition, an aneurysm is focal dilatation of a blood vessel that involves all three layers of vessel wall. Pulmonary artery aneurysm is defined as focal or fusiform dilatation of the PA beyond its maximum normal caliber. Early recognition and treatment are important for reducing morbidity and preventing mortality. The patients of PAA can be absolutely asymptomatic clinically and may be detected on radiograph or computed tomography or echocardiography. They may present as chest pain, dysnoea, or hemoptysis. It requires multidisciplinary approach for the diagnosis and treatment. It is very important to diagnose and manage the PAA as early as possible due to its high morbidity and mortality. Hence CTA is most important for the accurate evaluation of the PAA for its prompt diagnosis and treatment to reduce the risk of morbidity and mortality. Management of the PAA is surgical as well as medical depending upon the risk factors. The conservative management of PAA is serial follow up and periodic assessment of PAA. This is first case report of congenital aneurysm of pulmonary artery causing extrinsic compression over the left main bronchus leading to collapse. The case was successfully managed with surgical translocation of RPA in front of Ascending aorta, angioplasty of MPA & LPA and repair of the ASD; thereby relieving the compression over the left main bronchus and future complications.

Key words: Pulmonary artery aneurysm, Congenital, CT Scan, CT Angiography, Surgery.

INTRODUCTION

Pulmonary artery aneurysms are uncommon but are important to recognize because of the associated morbidity. By definition, an aneurysm is focal dilatation of a blood vessel that involves all three layers of vessel wall. Review of scientific literature shows that aneurysm as a medical condition was historically described by Bronson E and

Sutherland GA^{1,2} in 1918 and by Reid M in 1926. Focal dilatation of the pulmonary arteries can be congenital or acquired. Common causes include vasculitis, infection, neoplasm, and trauma, often iatrogenic. On radiographs, aneurysms may appear as hilar enlargement or a lung nodule. The diagnosis is usually confirmed with contrast-enhanced CT. CT provides useful information regarding the size, number, location, and extent of aneurysms. MRI also can show arterial wall thickening in connective tissue disease and provide information regarding blood flow direction in cases of poststenotic dilatation due to disease of the pulmonary valve. Early recognition and treatment are important for reducing morbidity and preventing mortality.¹

*Corresponding address:

Prof. Ajay Kumar Singh

Department of Radio-diagnosis, Army hospital R & R, Delhi, India.

E-mail: ltcolaksingh@gmail.com

DOI: 10.5530/jcdr.2015.1.6

We hereby report the first case of congenital aneurysm of pulmonary artery causing extrinsic compression over the left main bronchus leading to collapse.

CASE REPORT

01 yr old female presented with frequent episodes of cough, tachypnoea and dyspnoea since birth. With medication mild improvement was there but used to recur after few days. On examination she was found to have tachycardia with continuous harsh holosystolic murmur. She had tachypnoea with reduced air entry & crepitations on left side.

2D ECHO showed dilated right atrium (RA) and right ventricle (RV) with small left atrium (LA). Large second degree atrial septal defect (ASD) with bidirectional left to right shunt seen. Main pulmonary artery (MPA) was measuring 1.8 cm in caliber with pulmonary arterial hypertension noted. Pulmonary reflux was present. Patent ductus arteriosus (PDA) not visualized.

Initial radiograph of chest (Figure-1a) showed complete collapse of left lung. Non-contrast computerized tomography (NCCI) chest showed complete collapse of left lung with left main bronchus occlusion. Bronchoscopy was done to know the cause of collapse of left lung. It showed mucosal edema of the left main bronchus with inability of the bronchoscope to negotiate beyond left main bronchus.

Repeat radiograph of the chest showed gross cardiomegaly with grossly dilated pulmonary arteries and pulmonary plethora. The left lung re-expanded with persistent collapse of left lower lobe. Computerized tomography angiography (CTA, Figure-2, 4 ,5) of the cardio-pulmonary system was done to know the anatomy of the cardio-pulmonary vasculature and the cause of bronchial compression. It showed cardiomegaly with right chamber enlargement (RV/LV ratio was 1.88). There was 18x17 mm defect noted in inter-atrial septum. The MPA was dilated measuring 21 mm, right pulmonary artery (RPA) was 18 mm and left pulmonary artery (LPA) was 19.6 mm in width. The RPA was compressing and completely occluding 10 mm long segment of the left main bronchus against the descending thoracic aorta (approximately 07 mm distal to carina). The ascending aorta was measuring 11.6 mm in caliber. The aortic arch was forming a vascular sling over the RPA causing mild compression over the proximal portion. Collapse-consolidation of the left lower lobe noted.

During operation the chest was opened by median sternotomy. Operative findings were grossly dilated hypo-contracting right atrium with grossly dilated MPA, LPA & RPA. There was 3x2 cm ASD with normal left ventricle, mitral valve & tricuspid valve. Pericardial patch was harvested. MPA, LPA & RPA dissected. Heart arrested with antegrade cardioplegia. RA opened with autologous pericardial patch with 2.8 mm fenestration was used for the closure of ASD. RPA disconnected from its origin from MPA brought anterior to aorta and re-anastomosed. MPA

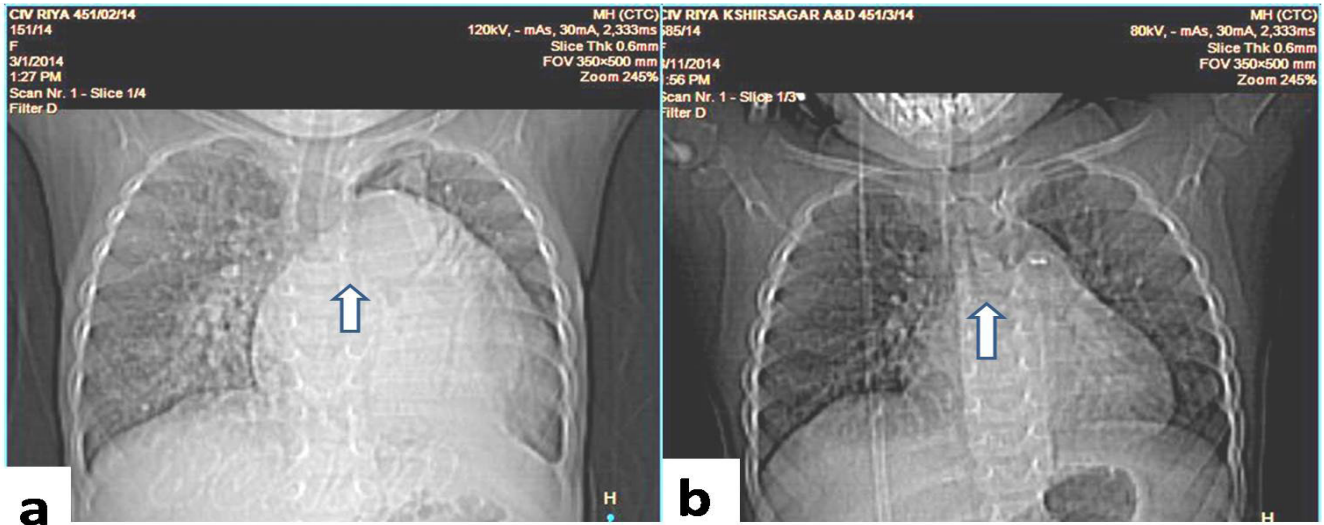


Figure 1: Radiograph of the chest

a) Pre operative radiograph shows gross cardiomegaly with grossly dilated pulmonary trunk and arteries. Bilateral significant pulmonary plethora noted. The proximal portion of the left main bronchus appears compressed (white arrow), however the distal portion appears normal. Collapse-consolidation of the left lower lobe and apico-posterior segment of Left upper lobe noted. **b) Post operative radiograph** (03months after the operation) shows significant reduction in the size of the heart, pulmonary trunk & arteries and pulmonary plethora noted. Entire left main bronchus is visualized with complete resolution of the collapse-consolidation of the left lung.

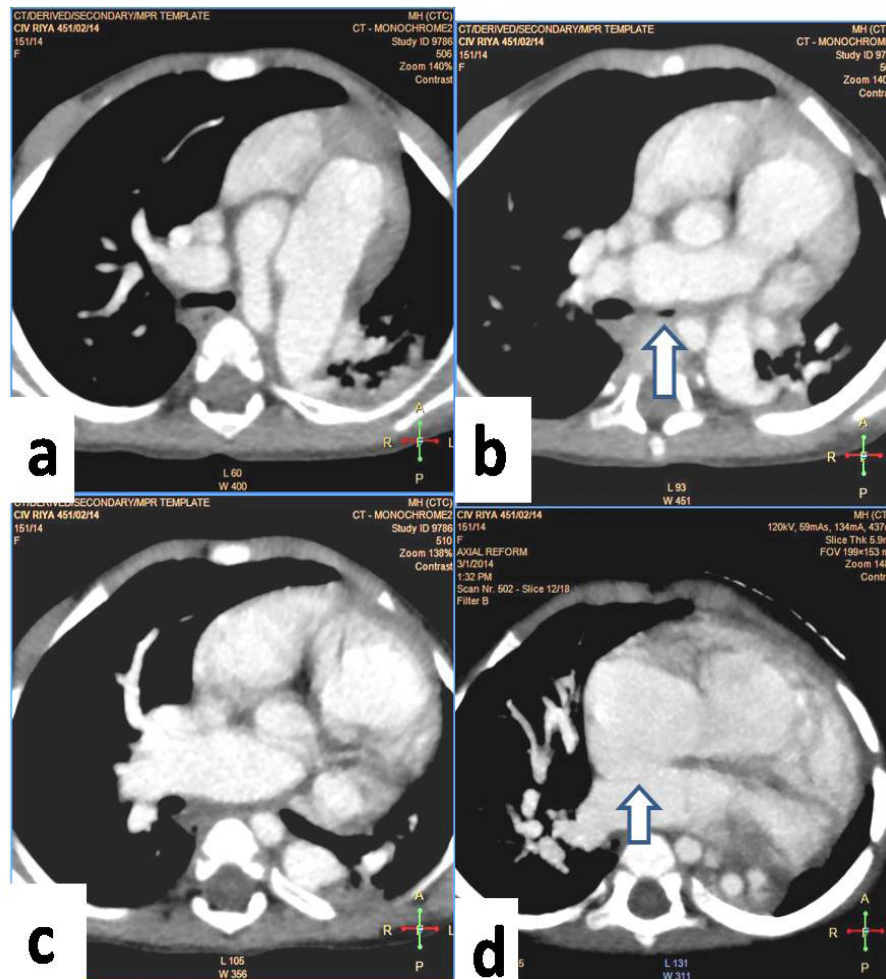


Figure 2: Pre operative CT Pulmonary Angiography axial sections :-

a) The CT Pulmonary Angiography axial section at the level of pulmonary artery shows grossly dilated main pulmonary artery and bilateral pulmonary arteries. The arch of aorta is arching over the RPA forming an arterial sling and causing mild compression over it. The left main bronchus is visualized at the level of carina. b) The scan is showing the left main bronchus is partially compressed in between the RPA & descending thoracic aorta. c) Left main bronchus is completely obliterated however the distal portion is normally visualized. d) Four chamber view shows cardiomegaly with dilated right atrial and right ventricular chambers. Large inter-atrial septal defect is seen (ASD)

& LPA reduction angioplasty was done. Patient had an uneventful post procedural recovery and was asymptomatic later on.

Post operative radiograph of the chest (Figure 1b) showed significant reduction in the size of the heart and pulmonary arteries. Pulmonary plethora had also significantly reduced. CT angiography (Figure 3-5) revealed reduced dimensions of the MPA, RPA & LPA; MPA was 19 mm at the root, RPA was 8.5 mm and LPA was 12 mm. RV/LV ratio was 19.6/19.2 with intermediate position of the inter-ventricular septum. The RPA was seen anterior to the ascending aorta and mild luminal narrowing at the origin of RPA from MPA as compared to the rest of the RPA. No obvious compression over the left main bronchus seen. Bilateral lung parenchymas were normal with complete resolution of the consolidation in the left lung noted. The patient is

on regular follow up and completely asymptomatic.

DISCUSSION

Pulmonary artery aneurysm is defined as focal or fusiform dilatation of the PA beyond its maximum normal caliber.³ The upper limit of normal dimensions of the MPA is 29 mm and the right descending pulmonary artery is 17 mm.⁴

In adults, dilatation of pulmonary artery more than 04 cm in caliber is known as aneurysm of pulmonary artery. The causes could be congenital or acquired. Congenital causes are pulmonary arterial hypertension, patent ductus arteriosus, and atrial & ventricular septal defects. Acquired causes are idiopathic, pulmonary valvular stenosis, traumatic, infectious like tuberculosis, syphilis and collagen vascular diseases.^{5,6}

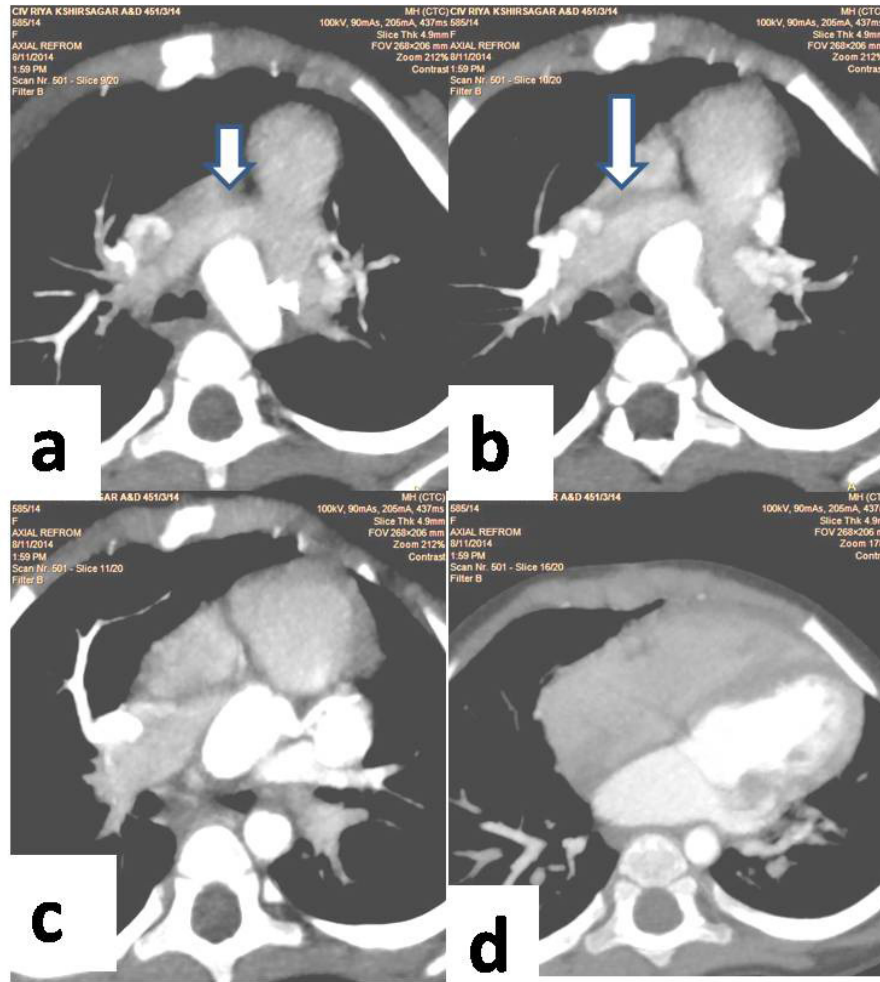


Figure 3: Post operative CT Angiography axial sections

a) b) & c) shows transposition of RPA in front of the ascending aorta with post plasty status of the MPA & LPA. The caliber of the MPA & LPA has reduced with residual dilatation of MPA seen. The left main bronchus is well visualized with no evidence of compression over it. d) Four chamber view shows reduced cardiac size, right atrial and right ventricular chambers. No evidence of ASD seen.

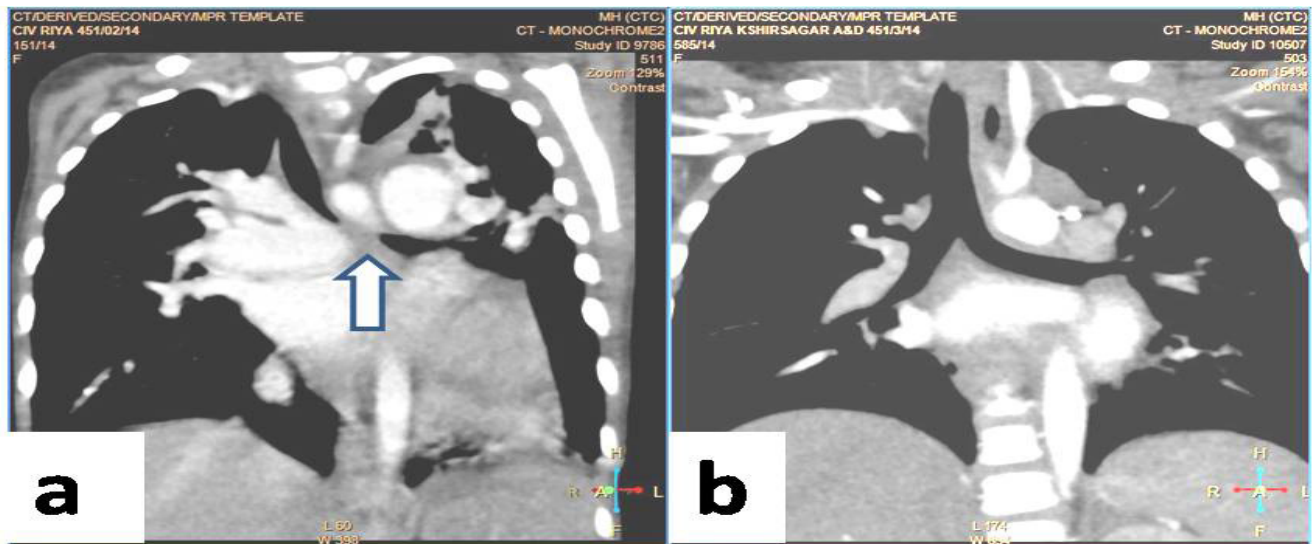


Figure 4: Pre & Post operative CT Angiography coronal views

a) Pre operative coronal oblique view shows compressed portion of the left main bronchus just distal to the carina (as shown by the arrow). Distal bronchus is normally visualized. b) Post operative coronal view shows entire left main bronchus with no evidence of compression seen.

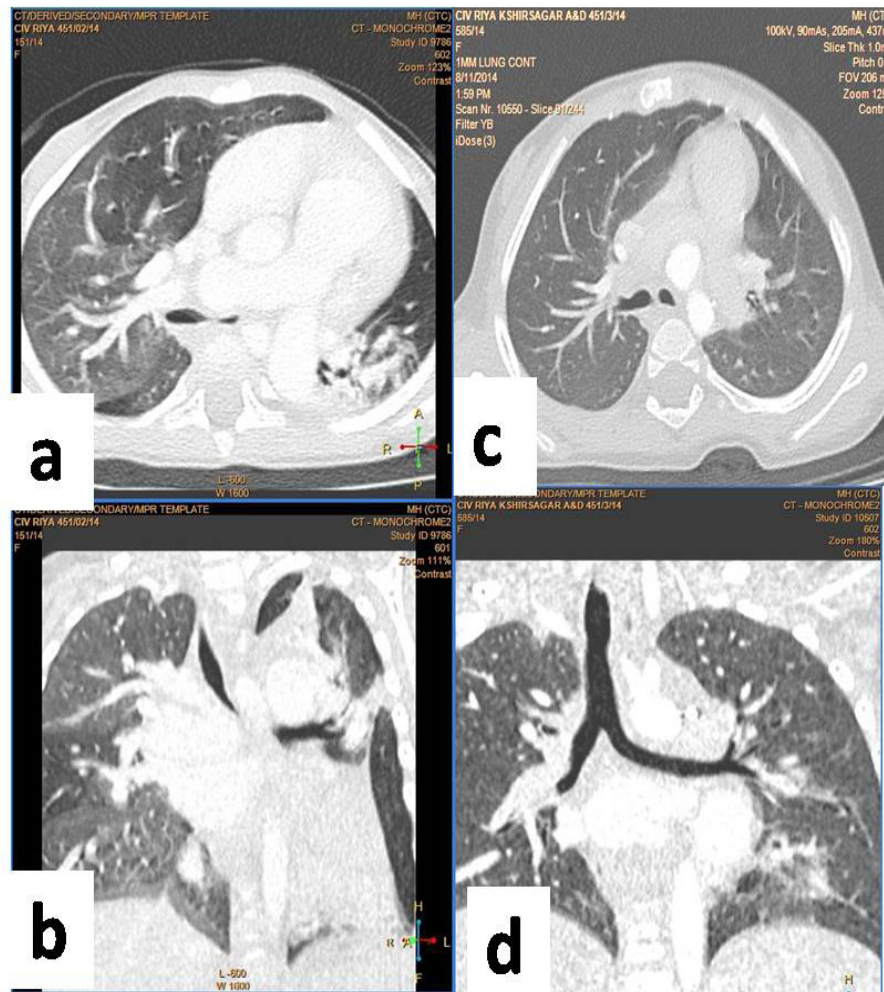


Figure 5: Pre and post operative scans in lung window -:

a) Pre operative scan in lung window axial section shows compressed left main bronchus. Collapse consolidation of the apical segment of the Left lower lobe. b) Pre operative scan in lung window coronal oblique view shows compressed portion of left main bronchus. Collapse-consolidation of the apico-posterior segment of the Left upper lobe and entire left lower lobe. c) Post operative scan in lung window axial section shows no evidence of compression over left main bronchus with normal lung parenchyma. d) Post operative scan in lung window coronal view shows normal caliber of the entire left main bronchus

The patients of PAA can be absolutely asymptomatic clinically and may be detected on radiograph or computed tomography or echocardiography. They may present as chest pain, dysnoea, or hemoptysis.^{5,7} The various complications of the PAA due to progressive increase in the size causing airway compression, thrombus formation, in one third cases may lead to fatal complications like dissection or rupture.^{8,9}

The diagnosis of PAA is by 2D echocardiography, computed tomography and magnetic resonance imaging. 2D echocardiography can estimate the size of PAA, condition of the pulmonary valves, pulmonary artery pressure, and presence or absence of shunt. CT angiography not only provides more accurate 3 dimensional views of the PA and the cardiac chambers but also its relation with other mediastinal structures. The 3 dimensional images of the cardio-pulmonary vasculature mimic the view after the

chest is opened.

Management of the PAA is surgical as well as medical depending upon the risk factors. The conservative management of PAA is serial follow up and periodic assessment of PAA done in asymptomatic patient with size less than 6 cm, low pulmonary artery wedge pressure and absent congenital right to left shunt. Surgical management PAA is aneurysmorrhaphy when PAA presents with hemoptysis or size >06 cm.¹⁰ It could be either aneurysmorrhaphy with replacement by using a prosthetic graft or a homograft replacement of the pulmonary trunk. The repaired artery can lead to recurrent aneurysm later on.¹¹

One case report has mentioned the PAA associated with PAH causing extrinsic compression over the left coronary artery and it was surgically corrected.¹² On radiograph

PAA is diagnosed as loss of concavity or bulge is noted in the pulmonary bay region with hilar enlargement. But it is difficult to differentiate from mediastinal/hilar mass lesions. CTA gives more accurate information regarding the size, location and extent of aneurysm.¹³ In addition to this MRI can show compatibility and movement of the valves, direction of blood flow and cardiac muscle movement.¹⁴ three cases on congenital vascular causes of airway compression. 44 days old baby who presented with weak cry and respiratory distress since birth. CTA showed double aortic arch was found forming vascular ring which was compressing the trachea & esophagus. The left aortic arch was divided and PDA was ligated. Another 5 months old baby who presented with stridor and feeding difficulties and 03 months later developed respiratory distress. CTA showed double aortic arch with left dominance with right arch was atretic. Right aortic arch was divided distal to the origin of the right subclavian artery. His stridor was resolved completely. Third case is of 10 months old female child presented with vomiting and choking with solid food at 06 months of her age. CTA showed vascular ring due

to aberrant right subclavian artery arising from aortic arch distal to the origin of left subclavian artery. The aberrant artery was divided which relieved the compression. The recent advances in the surgical technique is Video-assisted thoracoscopic vascular ring division which has added advantages of smaller surgical incision, early post operative recovery and reduced possibility of chest wall deformity.¹⁵⁻¹⁷

CONCLUSION

This is first case report of congenital aneurysm of pulmonary artery causing extrinsic compression over the left main bronchus leading to collapse. With the surgical translocation of RPA in front of Ascending aorta, angioplasty of MPA & LPA and repair of the ASD has relieved the compression over the left main bronchus and future complications. It is very important to diagnose and manage the PAA as early as possible due to its high morbidity and mortality. Hence CTA is most important for the accurate evaluation of the PAA for its prompt diagnosis and treatment to reduce the risk of morbidity and mortality.

REFERENCES

1. Bronson E, Sutherland GA. Ruptured aortic aneurysm in childhood. *Brit J Child Dis.* 1918; 15(16): 241-58.
2. Reid MR. Aneurysms in the John Hopkin's Hospital. *Arch Surg.* 1926; 12(1): 1-74.
3. Nguyen ET, Silva CI, Seely JM, *et al.* Pulmonary Artery Aneurysms and Pseudoaneurysms in Adults; Findings at CT and Radiograph. *AJR.* 2007; 188(2): W126-34.
4. Fraser RS, Müller NL, Colman N, *et al.* Pulmonary hypertension and edema. *Diagnosis of diseases of the chest.* Philadelphia. PA: Saunders 1999; 1935-7.
5. Vistarini N, Aubert S, Gandjbakhch I, Pavie A. Surgical treatment of a pulmonary artery aneurysm. *Eur J Cardiothorac Surg.* 2007; 31(6): 1139-41.
6. Veldtman G, Dearani J, Warnes C. Low pressure giant pulmonary artery aneurysms in the adult: natural history and management strategies. *Heart* 2003; 89(9): 1067-70.
7. Deb S, Zehr K, Shields R. Idiopathic pulmonary artery aneurysm. *Ann Thorac Surg* 2005; 80(4): 1500-02.
8. Sakuma M, Demachi J, Suzuki J, *et al.* Proximal Pulmonary Artery Aneurysms in Patients with Pulmonary Artery Hypertension: Complicated Cases. *Intern Med.* 2007; 46(21): 1789-93.
9. Butto F, Lucas JRV, Edwards JE. Pulmonary arterial aneurysm. A pathologic study of five cases. *Chest* 1987; 91(2): 237-41.
10. Vural AH, Tu'rk T, Ata Y, *et al.* Idiopathic asymptomatic main pulmonary artery aneurysm: surgery or conservative management? A case report. *Heart Surg Forum* 2007; 10(4): E273-5.
11. Muthialu N, Raju V, Muthubaskaran V, *et al.* Idiopathic Pulmonary Artery Aneurysm with Pulmonary Regurgitation. *Ann Thorac Surg.* 2010 Dec; 90(6): 2049-51.
12. Araujo I, Escribano P, Gude MJ, *et al.* Giant pulmonary artery aneurysm in a patient with vasoreactive pulmonary hypertension: a case report. *BMC Cardiovascular Disorders* 2011; 11(1): 64.
13. Remy-Jardin M, Remy J. Spiral CT angiography of the pulmonary circulation. *Radiology* 1999; 212(3): 615-36.
14. Thallaj A. Congenital Vascular Causes of Airway Compression: A Report of Three Cases. *The Internet Journal of Anesthesiology* 2004; Volume 10 Number 1.
15. Burke RP. Video-assisted thoracoscopic vascular ring division in an infant: a new operative technique. *J Card Surg.* 1993; 8(5): 537-40.
16. Geva T, Keane JF. Video-assisted thoracoscopic vascular ring division in infants and children. *Heart Surgery Forum* 2002; 5: s195.
17. Kussman BD. Cardiovascular causes of airway compression. *Pediat Anes* 2004; 14(1): 60.