

# Five tachycardia mechanisms in a structurally normal heart

Pranil Gangurde<sup>1\*</sup>, Anirudhha Vyas<sup>2</sup> and Yash Lokhandwala<sup>3</sup>

<sup>1</sup>Department of Cardiology, DNB Cardiology Registrar, LTMMG Hospital, Sion, Mumbai-400022, India.

<sup>2</sup>Department of Cardiology, EP Fellow, Holy Family Hospital, Mumbai, India.

<sup>3</sup>Department of Cardiology, DM Cardiology, LTMMG Hospital, Mumbai-400022, India.

## ABSTRACT

A 22 year old man with WPW syndrome and a structurally normal heart was admitted for the treatment of recurrent paroxysmal tachycardia. Induction protocols gave interesting clues for existence of more than one tachycardia mechanism. Five different tachycardia were demonstrated, the substrates being a right free wall accessory pathway (AP), a left lateral AP and dual AV nodal physiology. Successful ablation at 3 sites (lateral tricuspid annulus, lateral mitral annulus and slow pathway) in the same session led to complete elimination of these tachycardia mechanisms.

**Key words :** AVRT, His refractory, Outflow VT, Fascicular VT, Slow pathway.

### Correspondence:

Dr. Pranil Bhalchandra Gangurde, Department of Cardiology, DNB Cardiology Registrar, LTMMG Hospital, Sion, Mumbai-400022, India.

Phone no: 919823871970

Email: pranil.bjmc@gmail.com

DOI : 10.5530/jcdr.2015.4.6

## INTRODUCTION

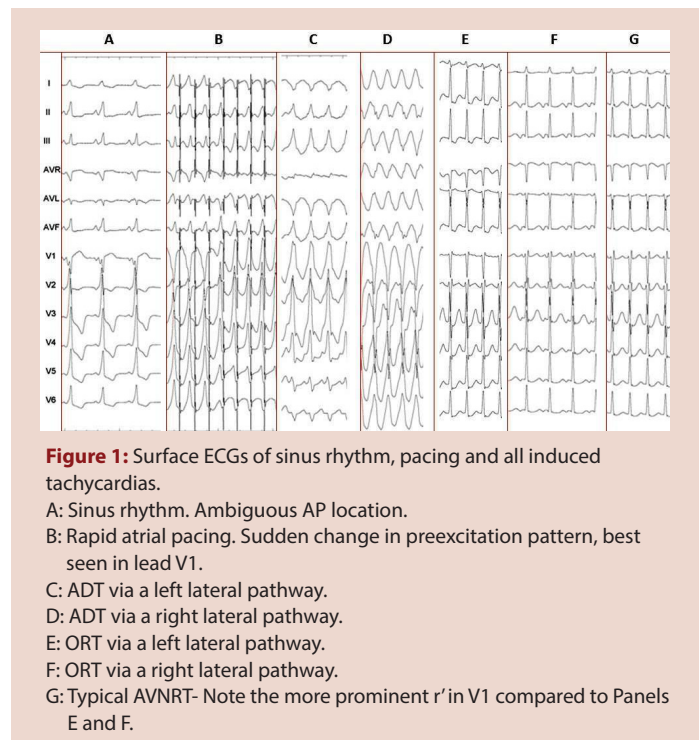
Multiple tachycardia mechanisms in structurally normal hearts have been previously reported.<sup>1-2</sup> Usually these are in the form of i) Orthodromic tachycardia (ORT) and Atrioventricular nodal re-entrant tachycardia (AVNRT), ii) Fascicular ventricular tachycardia (VT) and AVNRT and iii) Idiopathic right ventricular outflow VT and AVNRT. More than 2 tachycardia mechanisms with normal hearts is a rarity. Five different mechanisms in this setting has not been reported.

## CASE REPORT

A 22 year old student presented with multiple episodes of fast regular palpitations since 1 year. During the episodes he felt fatigued but had no presyncope. Physical examination and echocardiography revealed a structurally normal heart. His ECG in sinus rhythm showed manifest preexcitation with negative delta waves and rS complexes in lead V1, with transition to positive delta wave and Rs complexes in lead V2; there were positive delta waves in leads II, III and aVF. The overall preexcitation pattern was not fitting into a single AP location (Figure 1A). The tachycardia episodes were usually narrow QRS complex, terminated by intravenous adenosine or verapamil. On one occasion the tachycardia ECG showed a RBBB-like pattern with inferior axis @ 212/min, was refractory to adenosine and verapamil and was terminated with a biphasic DC shock of 100 J.

He underwent an electrophysiology study. Rapid atrial pacing revealed maximal preexcitation and a sudden change in QRS morphology. The initial pattern suggesting a right sided pathway, suddenly changed to a pattern suggesting a left sided pathway (Figure 1B). The antegrade refractory period of the right sided AP was 300ms and that of the left sided AP was 240ms. With atrial extrastimuli, an antidromic tachycardia (ADT) using the left sided pathway as antegrade limb was induced (Figure 1C). The retrograde limb was the right sided accessory pathway: a His-refractory premature ventricular depolarisation (PVD) advanced and reset the tachycardia (Figure 2A). An earlier PVD terminated tachycardia without conduction to the atria (Figure 2B).

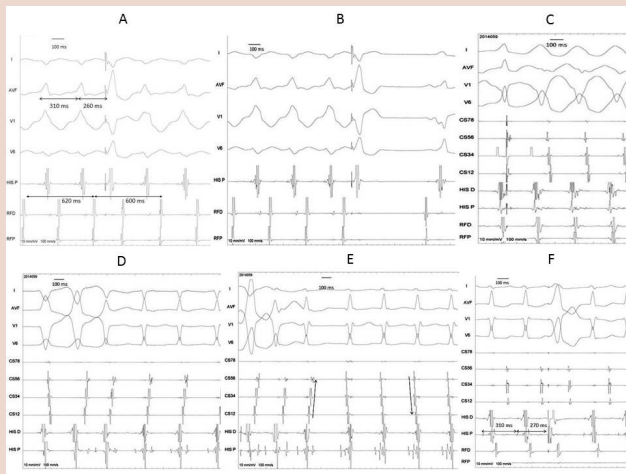
With atrial extrastimuli, an ORT using the left lateral pathway was also induced (Figures 1E, 2D). This ORT spontaneously changed to typical AVNRT with change in retrograde atrial activation pattern from eccentric to concentric, shortening of VA interval and appearance of a promi-



nent r' in lead V1 (Figures 1G, 2E). The left lateral pathway was ablated under the lateral mitral annulus during atrial pacing (Figures 3A - D).

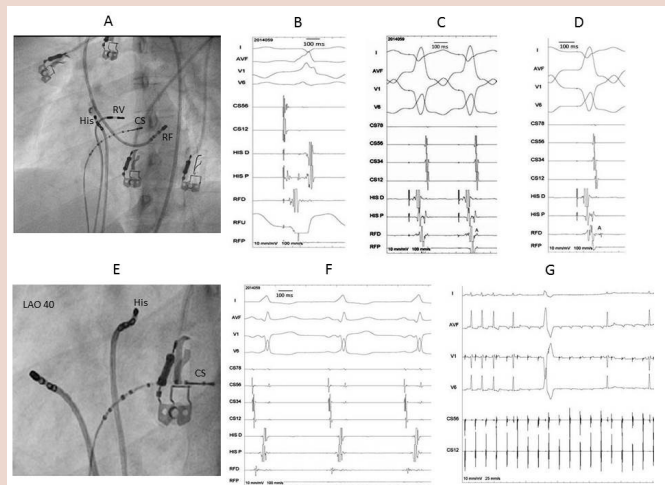
After this, an ADT (Figures 1D, 2C) and ORT (figure 1E, 2F) using the right free wall pathway were induced by atrial extrastimuli; a right ventricular PVD advanced the ORT (Figure 2F). The right free wall pathway was ablated at lateral tricuspid annulus (Figures 3E, 3F) in sinus rhythm.

At this stage, typical AVNRT was inducible by atrial extrastimuli. Slow-fast AVNRT diagnosis was confirmed by the following: 1) The A during tachycardia was earliest in the His region and was within the QRS complex and 2) His-refractory VPDs during tachycardia did not change atrial activation.



**Figure 2:** Intracardiac traces of all induced tachycardias.

A,B: ADT via the left lateral pathway. A: The tachycardia is advanced and reset by a His-refractory ventricular extrastimulus. The extrastimulus comes within 50 ms of the onset of the next QRS; since the His is buried in the QRS, this stimulus would be in the His-refractory period. B: An earlier stimulus terminates tachycardia without conduction to the atrium.  
 C: ADT via a right lateral pathway. The retrograde limb is the AV node.  
 D: ORT via a left lateral pathway  
 E: ORT via a left lateral pathway changes to typical AVNRT. Note the reversal in activation sequence in the CS channels.  
 F: ORT via a right lateral pathway. A His-refractory PVD advances the next atrial activation.



**Figure 3:** Ablation of all tachycardia mechanisms.

A-D: Left lateral pathway ablation. A: Ablation site; B: Atrial pacing- Early V in RFD channel; C: RV pacing- Early A in RFD channel. The retrograde conduction is a fusion between the AV node (CS pattern) and the AP (early A in RFD); D: RV pacing after ablation- Late A in RFD channel.  
 E: Right lateral pathway ablation site.  
 F: Continuous electrical activity in RFD channel  
 G: Adenosine after ablation- no preexcitation, complete AV block.

The slow pathway was ablated in the right midseptal region; accelerated irregular junctional complexes with retrograde atrial complexes were seen during energy.

Concentric and decremental retrograde AV nodal conduction was seen after ablation. Intravenous adenosine bolus led to transient AV (Figure 3G) and VA blocks. Despite waiting for 30 minutes after ablation, vigorous stimulation protocols using both intravenous isoprenaline and atropine could not induce any tachycardia. In 10 months follow up patient was asymptomatic.

## DISCUSSION

Multiple tachycardia mechanisms in structurally normal hearts have been previously reported.<sup>1-2</sup> Our patient had a unique combination of five different tachycardias (ADT with pathway to pathway conduction, ADT with AV node as retrograde limb, two ORTs using left and right sided pathways and typical AVNRT) in a structurally normal heart. Multiple APs have been linked to developmental defects in AV valve rings. Usually they are on the same side. Dual AV nodal physiology

exists in as many as 8-40% of patients with APs but inducible AVNRT is present in only a minority.<sup>3</sup>

The coexistence of ORT and AVNRT with change of one tachycardia mechanism to another during a single episode has been described previously.<sup>4,5</sup> Failure to identify multiple substrates of tachycardia may be responsible for recurrence of symptoms. Our case highlights various clues which may suggest existence of multiple tachycardia substrates. The 12 lead surface ECG was not fitting into a single AP location, possibly due to summated preexcitation from right and left sided pathways. A sudden change in QRS morphology with rapid atrial pacing due to switch in AP conduction from right to left was due to difference in refractory periods; the right sided pathway had a longer refractory period. Advancement and resetting of ADT through left sided pathway by a His-refractory PVD confirmed the retrograde limb to be a right free wall pathway. An abrupt change in retrograde activation pattern during ORT<sup>5</sup> from eccentric to concentric and shortening of VA interval gave the first suggestion of AVNRT. An ADT with precordial pattern simulating baseline preexcitation of the right sided pathway, along with an ORT using this pathway (getting advanced by a right ventricular PVD) completed the picture.

Multiple tachycardia mechanisms can be rarely encountered. Detailed analysis of the ECG, intracardiac recordings and appropriate manoeuvres are paramount for their identification and successful ablation.

## REFERENCES

- Chen SA, Cheng CC, Chiang CC, et al. Radiofrequency ablation in a patient with tachycardia incorporating triple free wall accessory pathways and atrioventricular nodal reentrant tachycardia. *Am Heart J.* 1994; 127: 1656-61.
- Varotto L, Storti C, Salerno-Uriate JA. Radiofrequency ablation in two patients with typical and atypical atrioventricular nodal re-entrant tachycardias, associated with atrioventricular re-entrant tachycardias. *ItalCardiol.* 1999; 29: 1030-33.
- Zardini M, Leitch JW, Guiraudon GM, Klein GJ, Yeer R. Atrioventricular nodal reentry and dual atrioventricular node physiology in patients undergoing accessory pathway ablation. *Am J Cardiol.* 1990; 66: 1388-89.
- John B, Lokhandwala YY, Pati PK, Jose VJ. "A bird in hand or two in the bush?" *JCardiovascElectrophysiol.* 2004 Dec; 15(12): 1465-6.
- Vora A, Lokhandwala Y. Adulterous tachycardia: what is the mechanism? *Pacing ClinElectrophysiol.* 1998 May; 21(5): 1146-7.