

## Refractory vasospastic angina

Rajiv Ananthakrishna\* and Manjunath Cholenahally Nanjappa

Department of Cardiology, Sri Jayadeva Institute of Cardiovascular Sciences & Research, Bangalore, India.

### ABSTRACT

Vasospastic angina, a form of angina pectoris due to coronary artery spasm responds to nitrates and calcium antagonists in majority of the cases. Rarely, they are unresponsive to conventional treatment, and recurrent ischemia can lead to ventricular arrhythmias, myocardial infarction and sudden death. We report a patient with multi-vessel coronary artery spasm and recurrent ST segment elevation in anterior leads, which was successfully managed with intravenous administration of nicorandil.

**Key words :** Coronary spasm, Coronary artery disease, Vasospastic an-

gina, Nicorandil, Imaging.

### Correspondence:

Dr. Rajiv Ananthakrishna, Sri Jayadeva Institute of Cardiovascular Sciences & Research, Jaya Nagar 9<sup>th</sup> Block, BG Road, Bangalore 560069, India.

Phone no: +919845906245; Fax no: +918026534477

Submission Date: 29-07-2015; Review completed: 2-10-2015;

Accepted Date: 10-10-2015

Email: rajiva.ms@gmail.com

DOI: 10.5530/jcdr.2015.4.7

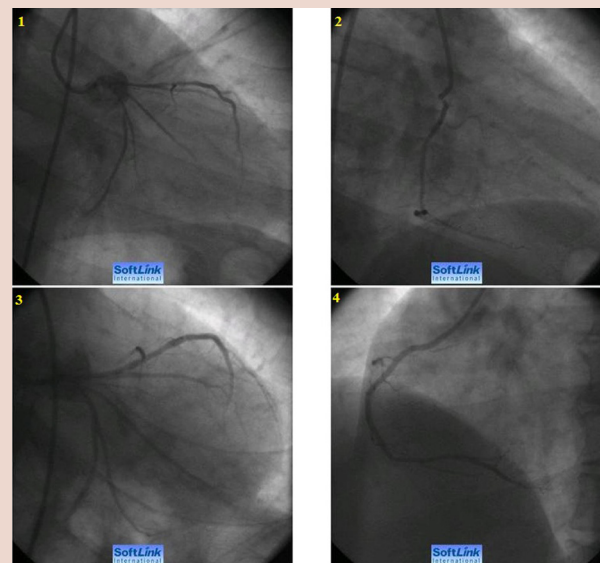
### INTRODUCTION

Vasospastic angina (VSA) is usually well controlled with calcium channel blockers and nitrates. 5% to 30% of patients fail to respond to standard therapy.<sup>1</sup>

Therefore, refractory cases are not uncommon in clinical practise and present a therapeutic challenge. In addition, there are no standard guidelines regarding the most appropriate treatment strategy in such situations. Treatment options include escalating the doses of recommended drugs, alternative agents like prazosin, nicorandil, bosentan and invasive treatment options like percutaneous coronary intervention, brachytherapy or thoracic sympathectomy. We highlight a patient with multi-vessel coronary artery spasm and recurrent angina which was successfully managed with intravenous administration of nicorandil.


### CASE REPORT

A 47-year-old male was referred for evaluation of effort angina (CCS class II) of 2 months duration. He was detected to have type II diabetes mellitus 4 years prior, on oral hypoglycemic agents. Resting electrocardiogram and two-dimensional transthoracic echocardiography were normal. Treadmill test was positive for inducible ischemia (workload of 8 METS). He was scheduled for coronary angiogram. Patient developed severe anginal chest pain with ST segment depression in precordial leads during angiogram. Evaluation of coronary anatomy revealed vasospastic coronaries (ostial RCA, LMCA, proximal LAD and proximal LCX), which resolved following intracoronary administration of nitroglycerin (Figure A, Videos 1-4). There was immediate symptomatic relief and resolution of electrocardiographic changes. A diagnosis of vasospastic angina was considered and treatment initiated with oral nitrates and calcium channel blockers. One hour after the coronary angiogram, patient experienced anginal chest pain at rest with ST segment elevation in leads V1-V4 (Figure B). There was prompt resolution of symptoms and electrocardiographic changes with sublingual nitroglycerin. In addition to standard acute coronary syndrome protocol, he was started on intravenous infusion of nitroglycerin. However, he continued to have recurrent episodes of angina with re-elevation of ST segment in precordial leads. The infusion of nitroglycerin and oral diltiazem were escalated to the maximum tolerated dose (40 µg/min of nitroglycerin and 180 mg / day of diltiazem). As the symptoms were refractory, intravenous infusion of nicorandil (2mg/hour) was started. After 30 minutes, the chest pain

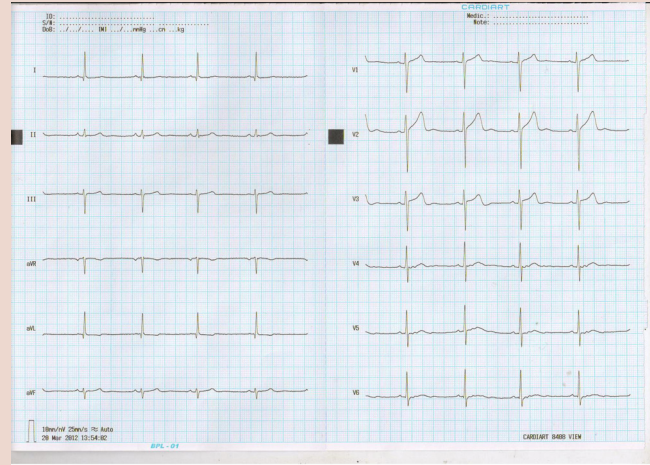


- A. 1) Coronary angiogram in right anterior oblique, caudal view showing narrowing of left main coronary artery, proximal left anterior descending artery and proximal left circumflex artery.  
2) Coronary angiogram in right anterior oblique view illustrating narrowing of ostial right coronary artery.  
3) Repeat angiogram following administration of intra-coronary nitroglycerin: no flow limiting lesions in the left system  
4) Ostial right coronary artery spasm relieved following administration of intra-coronary nitroglycerin.

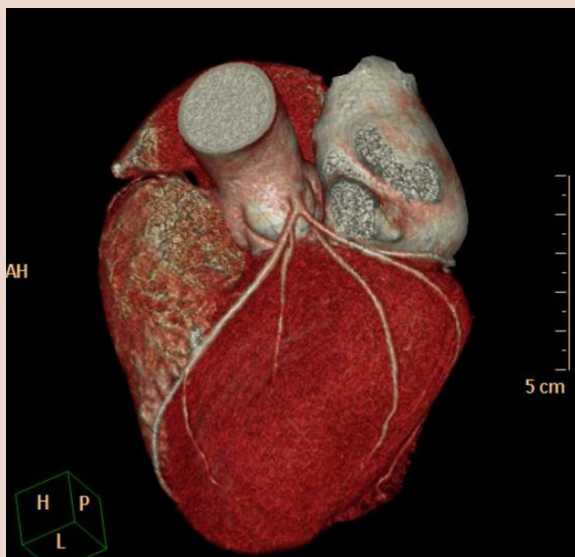
and ST segment elevation completely disappeared, and the response was sustained. Nitroglycerin and nicorandil infusion were continued for 24 hours and subsequently switched to oral nicorandil (15 mg/day) and long acting nitrate. Troponin T was negative and hs-CRP was 3.2 mg/dl. He was observed in the hospital for 72 hours, with no further episodes of angina. A CT coronary angiogram on the 3<sup>rd</sup> day revealed normal epicardial coronaries (Figure C). Pre-discharge electrocardiogram (Figure D) and echocardiography were normal. He was discharged on dual antiplatelets (aspirin and clopidogrel), long acting nitrate, diltiazem



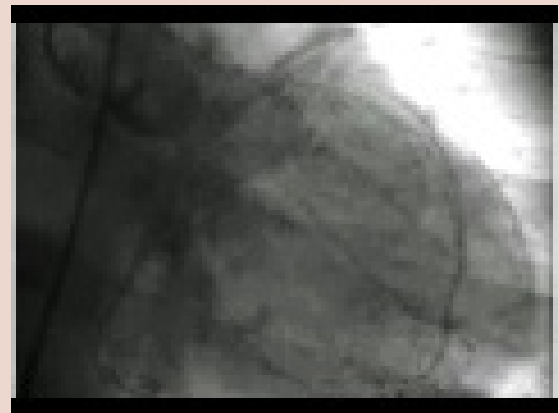
B. Electrocardiogram during an episode of rest angina showing ST segment elevation in V1-V4 and reciprocal ST segment depression in lateral leads.



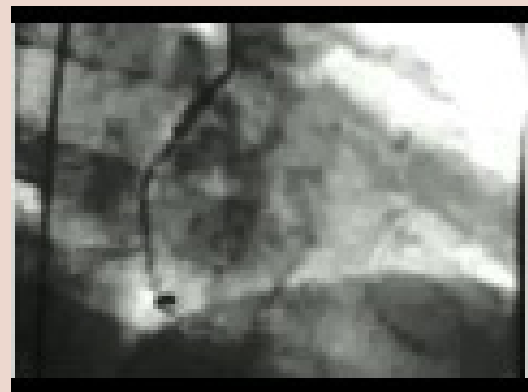
D. A normal electrocardiogram at the time of discharge.



C. Computed tomography angiogram showing a normal left main coronary artery, left anterior descending artery and left circumflex artery.



Video 1) Coronary angiogram in right anterior oblique, caudal view showing narrowing of left main coronary artery, proximal left anterior descending artery and proximal left circumflex artery. Click the link below for video <https://youtu.be/eErNUqz5GzI>

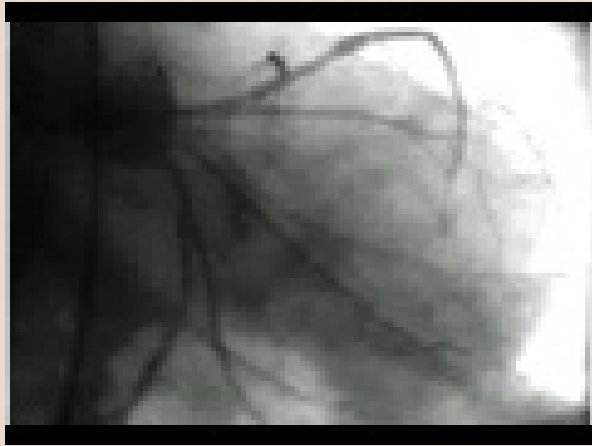


Video 2) Coronary angiogram in right anterior oblique view illustrating narrowing of ostial right coronary artery. Click the link below for video <https://youtu.be/wOrvjGGhICg>

(180 mg/day), nicorandil (15 mg/day), ramipril and statins. Patient is asymptomatic at 6 months follow-up.

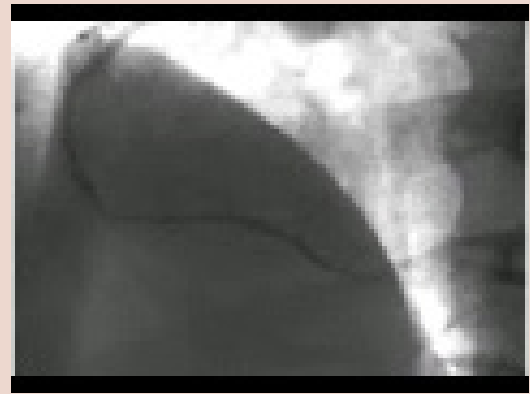
## DISCUSSION

Vasospasm of an epicardial coronary artery typically presents as episodes of spontaneous ischemic rest pain, with ST segment elevation. The mechanisms of vasospasm have not been fully established. Various hypothesis include alteration of autonomic nervous tone<sup>2,3</sup> or an imbalance between endothelial derived relaxing and contracting factors.<sup>4</sup> The mainstay of therapy in VSA is a combination of calcium antagonist and long acting nitrates. Cases of VSA refractory to optimal standard therapy are not infrequent, and therapeutic modalities in such a scenario are difficult. Sustained relief of vasospasm is critical, as recurrent episodes of ischemia



Video 3) Repeat angiogram following administration of intra-coronary nitroglycerin: no flow limiting lesions in the left system.

Click the link below for video <https://youtu.be/LTofatQOAZY>



Video 4) Ostial right coronary artery spasm relieved following administration of intra-coronary nitroglycerin.

Click the link below for video <https://youtu.be/HL6X0iSWVcE>

can result in infarction, cardiac arrhythmias and sudden death. Various therapies which have been tried include prazosin<sup>5</sup>, bosentan<sup>6</sup>, corticosteroids<sup>7</sup>, nicorandil<sup>8</sup>, brachytherapy<sup>9</sup> and stenting.<sup>1</sup> Thoracic sympathectomy is emerging as an attractive alternative in refractory cases.<sup>10</sup>

In the present report, we highlight the presence of multivessel coronary artery spasm and the role of nicorandil in variant angina. Presence of multivessel coronary artery spasm is often mistaken for significant stenotic lesions, leading to inappropriate revascularization. If vasospasm were not to be excluded in our case, patient would have been referred for coronary artery bypass surgery. Hence, it is important to administer intracoronary nitroglycerin to exclude spasm of coronary arteries. Coronary spasm can be induced during catheter cannulation of both right and left coronary arteries. However, our patient continued to have recurrent episodes of spontaneous ischemic rest angina with ST elevation – initially responsive to nitroglycerin and subsequently nicorandil. Hence, it represents a classic case of vasospastic angina and should not be mistaken solely as iatrogenic coronary artery spasm. It is also important not to selectively engage the ostium of coronary vessels, if there is

vasospasm during initial cannulation. Repeat cardiac catheterization and intravascular imaging were avoided, as it may provoke further episodes of vasospasm. A pre-discharge CT coronary angiogram was done to exclude obstructive coronary artery disease. A positive treadmill test could be either due to coronary microvascular disease or a false positive result. There were no episodes of ST segment elevation during treadmill test.

The role of nicorandil in stable ischemic heart disease is well established. Though reported,<sup>8</sup> this case reinforces the role of nicorandil in refractory vasospastic angina. Nicorandil, a nicotinamide derivative is underutilized in this setting. It is an ATP sensitive potassium channel opener and causes dilatation of both conductive and resistance vessels. In comparison to nitrates and calcium antagonists, nicorandil is unique as it possesses no significant hemodynamic effect on heart rate, blood pressure or cardiac contractility and at the same time yielding antianginal effects. In VSA, it is believed to reduce the increased vasomotor tone.

To conclude, intravenous nicorandil is a safe and effective therapy for management of VSA, refractory to conventional treatment.

## REFERENCES

1. Gaspardone A, Tomai F, Versaci F, *et al.* Coronary artery stent placement in patients with variant angina refractory to medical treatment. *Am J Cardiol* 1999; 84: 96-8.
2. Tsuchiya T, Okumura K, Yasue H, Kugiyama K, Ogawa H. Heart period variability in patients with variant angina. *Am J Cardiol*. 1996; 77: 932-6.
3. Yoshida K, Utsunomiya T, Morooka T, *et al.* Mental stress test is an effective inducer of vasospastic angina pectoris: comparison with cold pressor, hyperventilation and master two-step exercise test. *Int J Cardiol*. 1999; 70:155-63.
4. Mayer S, Hillis LD. Prinzmetal's variant angina. *Clin Cardiol*. 1998; 21: 243-6.
5. Tzivoni D, Keren A, Benhorin J, Gottlieb S, Atlas D, Stern S. Prazosin therapy for refractory variant angina. *Am Heart J*. 1983; 105: 262-6.
6. Krishnan U, Win W, Fisher M. First report of the successful use of bosentan in refractory vasospastic angina. *Cardiology*. 2010; 116: 26-8.
7. Takagi S, Goto Y, Hirose E, *et al.* Successful treatment of refractory vasospastic angina with corticosteroids: coronary arterial hyperactivity caused by local inflammation? *Circ J*. 2004; 68: 17-22.
8. Lee KH, Kim SH, Lim HE, *et al.* Effectiveness of intravenous administration of nicorandil in a patient with variant angina refractory to continuous intravenous nitroglycerin. *Int J Cardiol*. 2007; 120: e9-12.
9. Erne P, Jamshidi P, Juelke P, Hafner HP, Thum P, Resink T. Brachytherapy: potential therapy for refractory coronary spasm. *J Am Coll Cardiol*. 2004; 44: 1415-9.
10. Yoshida K, Inoue T, Hirakawa N, Node K. Endoscopic thoracic sympathectomy as a novel strategy for vasospastic angina refractory to medical treatments. *J Cardiol*. 2008; 52: 49-52.