

***Mycobacterium abscessus* bacteremia in an immunocompetent patient following a coronary artery bypass graft**

Smita Sarma, Sunil Sharma¹, Usha K Baweja¹, Yatin Mehta²

Departments of Microbiology and, ¹Clinical Lab, ²Medanta Institute of Critical Care and Anaesthesiology, Medanta - The Medicity, Gurgaon, Haryana, India

Address for correspondence: Dr. Smita Sarma, Department of Microbiology, Medanta - The Medicity, Sector 38, Gurgaon 122 001, Haryana, India. E-mail: sarma.smita@rediffmail.com

ABSTRACT

Sternal osteomyelitis with bacteremia due to *Mycobacterium abscessus* is rarely seen in immunocompetent hosts. Routine pyogenic cultures in these cases are often negative causing a delay in diagnosis and treatment. Clinicians and microbiologists should rule out the possibility of infection due to nontuberculous mycobacteria while managing cases of nonhealing culture-negative wounds with conventional antibiotic therapy. We report a case of bacteremia secondary to a nonhealing sternal wound due to *M. abscessus*. A combination of radical debridement and prolonged antimicrobial therapy helped in the complete eradication of the infection.

Key words: Bacteremia, *Mycobacterium abscessus*, nontuberculous mycobacteria, sternal osteomyelitis

INTRODUCTION

Deep sternal wound infections occur in approximately 0.5–8% of cases following cardiac surgery.^[1] Earlier reported infections were mainly of bacterial (pyogenic) or fungal origin. However, recently, nontuberculous mycobacteria (NTM) have emerged as one of the important etiological agents of nonhealing postsurgical wounds. The present case report describes the occurrence of bacteremia secondary to a nonhealing sternal wound due to *Mycobacterium abscessus*. A combination of radical debridement and prolonged antimicrobial therapy helped in the complete eradication of the infection. *M. abscessus* belongs to a group of rapidly growing NTM which are ubiquitous environmental pathogens, and have been isolated from natural water, tap water, water used in showers, surgical solutions, and soil. These NTM

are probably transmitted by aerosol, soil, dust, water, ingestion, or by skin inoculation. Person-to-person spread is rare.^[2] The chance of overlooking these organisms is high unless there is a strong clinical suspicion along with microbiological confirmation.

CASE REPORT

A 75-year-old male belonging to the upper middle class presented with a history of a nonhealing sternal wound following a coronary artery bypass graft (CABG) in June 2010. CABG was done in the early part of May and the patient was discharged with the intact wound with an 8-h dose of amoxicillin and clavulanic acid combination (625 mg). The chest wound gradually progressed in size with a serosanguinous discharge despite the antibiotic cover. The patient was a known case of atherosclerotic heart disease with a history of myocardial infarction and chronic obstructive pulmonary disease. He had undergone percutaneous transluminal coronary angioplasty in March 2010. The patient was normotensive and nondiabetic with a family history of Koch's spine for which his wife was under antitubercular therapy (ATT).

The patient at admission was afebrile with a heart rate

Access this article online

Quick Response Code:



Website:

www.jcdronline.com

DOI:

10.4103/0975-3583.78604

of 96 beats/min and BP of 120/80 mmHg. The chest was bilaterally clear, and clinically, all the systems were normal. Laboratory investigations revealed the following: hemoglobin: 10.6 gm%; total white blood cell (WBC) count: $10.39 \times 10^3/\text{mm}^3$; differential WBC count: neutrophils 67%, lymphocytes 20%, monocytes 2%, eosinophils 0.2%, and basophils 0.3%; platelet count 4.4 lakhs/ mm^3 . Tests for HbsAg, HCV, and HIV 1 and 2 antibodies were found to be nonreactive. Liver function tests and renal function tests were normal. Blood, pus from the wound, and sputum were sent for aerobic culture.

Blood cultures (BacT Alert; bioMeriux) sent in duplicate showed the presence of faint Gram-positive beaded, rod-shaped organisms after 4 days of incubation. Ziehl–Neelsen (ZN) staining of smears from signal positive blood culture bottles showed the presence of beaded acid-fast bacilli in chains. The blood was then inoculated onto blood agar, MacConkey agar, and Lowenstein–Jensen (LJ) medium. Blood and MacConkey agar did not show any growth till 48 h after aerobic incubation. The LJ medium showed the presence of tiny creamish colonies on the third day after incubation. ZN staining of the smears from these colonies showed the presence of acid-fast bacilli. The isolate was provisionally identified as atypical mycobacteria (rapid grower).

Gram staining of the pus smear showed plenty of Gram-variable bacilli. No growth was seen on blood and MacConkey agar till 2 days of aerobic incubation. Since the blood culture was positive for atypical mycobacteria, the pus sample was also subjected to ZN staining and mycobacterial culture. ZN staining of the pus smear showed the presence of numerous acid-fast bacilli. The culture on the LJ medium grew tiny creamish colonies on the fourth day of incubation. ZN staining of these colonies also showed the presence of acid-fast bacilli. This isolate was also provisionally identified as atypical mycobacteria (rapid grower).

The aerobic culture of the sputum on blood and MacConkey agar did not grow any respiratory pathogen. The sputum culture was negative for *Mycobacterium tuberculosis* after 6 weeks of incubation in the LJ medium, and PCR for the MTB complex of the sputum sample came negative.

The patient was started on second-line ATT comprising IV azithromycin 500 mg every 12 h, IV amikacin 1 g once daily, and tab ciplox 500 mg every 12 h. Sternal wound debridement was done 2 days later under general anaesthesia along with omentoplasty. The tissue was sent for aerobic culture, histopathological examination and

MTB complex PCR to rule out *M. Tuberculosis* presence. The aerobic culture did not show any growth till 3 weeks after incubation and PCR for the MTB complex came negative. The mycobacterial culture grew similar colonies as mentioned above 7 days after incubation.

A histopathological examination of the biopsy sample showed chronic necrotizing, granulomatous osteomyelitis of the sternum compatible with tuberculosis.

The atypical isolates (rapid growers) were later identified as *M. abscessus* by using the Genotype Mycobacterium CM kit (Hain Lifescience, Germany). This test is based on the DNA strip technology and permits the identification of common atypical mycobacteria along with the *M. tuberculosis* complex [Figure 1]. Antimicrobial sensitivity testing was done on Mueller–Hinton agar by the Kirby–Bauer disc diffusion method for amikacin, doxycycline, imipenem, ciprofloxacin, sulfonamide, erythromycin, cefoxitin, and clarithromycin. The strains were found to be sensitive to amikacin, erythromycin, ciprofloxacin, and clarithromycin.

Repeat blood and swab cultures for mycobacterium from the incision site sent 1 week after starting antibiotic therapy were negative. The sternal wound had completely healed and the patient was discharged on the 18th postoperative day with an advice to continue with the prescribed antibiotics for 6 months with regular follow-up.

DISCUSSIONS

Disseminated infection due to nontuberculous mycobacteria is rare in immunocompetent individuals. Reports of *M. abscessus* causing native valve endocarditis have been

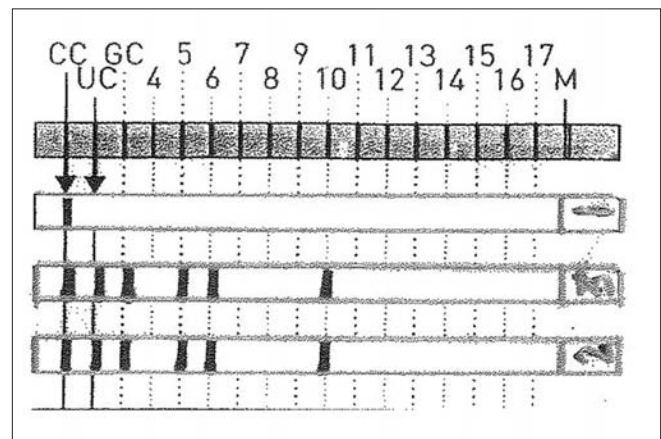


Figure 1: The Genotype Mycobacterium CM (HAIN Lifescience) hybridization pattern for isolates from blood and pus samples (strip 3 and 4 from the top) with template (strip 1) for evaluation. Band 1 (CC): conjugate control; band 2 (UC): universal control; band 3 (GC): genus control; bands 5, 6, and 10: probes specific for *M. abscessus*

documented in a few studies with poor prognosis. However, there are very few reports of *M. abscessus* causing sternal osteomyelitis with associated bacteremia.^[3,4] A PubMed search of the published literature showed that no such case has been reported from India till date. Infection due to rapidly growing mycobacteria is often iatrogenic resulting from surgery or injection.^[2] In our case, the mode of transmission could not be identified as it was the first case in our setup.

The species-specific identification of rapid growers by conventional methods is difficult and time consuming, whereas molecular methods are more reliable and faster. The mycobacterial isolates from our patient were identified by the line immunoassay, and the process of identification was completed within a day.

A combination of early diagnosis, radical debridement, and treatment with appropriate drugs is essential to minimize morbidity and mortality as NTM are usually resistant to the conventional antitubercular drugs.^[5] It is reported that antibiotics with the maximum *in vitro* activity against *M. abscessus* isolates include amikacin, clarithromycin, tigecycline, and cefoxitin.^[4,6] Our patient was put on amikacin, azithromycin, and ciprofloxacin to which he fully responded.

CONCLUSION

It is important to be aware of infections caused by NTM both from diagnostic and therapeutic points of view. All culture-negative nonhealing lesions should be processed to rule out atypical mycobacterial infection by both acid fast staining and culture. Conventional ATT should not be started based only on direct microscopic finding of acid-fast bacilli from clinical samples.

REFERENCES

1. Barnea Y, Carmeli Y, Kuzmenko B, Navon-Venezia S. Staphylococcus aureus mediastinitis and sternal osteomyelitis following median sternotomy in a rat model. *J Antimicrob Chemother* 2008;62:1339-43.
2. Katoch VM. Infection due to non tuberculosis mycobacteria (NTM). *Indian J Med Res* 2004;120:290-304.
3. Tsai WC, Hsieh HC, Su HM, Lu PL, Lin TH, Sheu SH *et al.* Mycobacterium abscessus endocarditis: A case report and literature review. *Kaoshiung J Med Sci* 2008;24:481-6.
4. Al-Benwan K, Ahmad S, Mokaddas E, Johny M, Kapoor MM. Diagnosis of endocarditis caused by Mycobacterium abscessus. *Ann Saudi Med J* 2010;30:408-11.
5. Sarma S, Thakur R. Cutaneous infection with Mycobacterium fortuitum: An unusual presentation. *Indian J Med Microbiol* 2008;26:388-90.
6. Teo YR, Tay KY, Poh TW. Sporotrichoid nodules caused by Mycobacterium abscessus. *Acta Dermato Venerologica* 2008;88:625-6.

Source of Support: Nil, Conflict of Interest: None declared.

Announcement

Android App



Download
Android
application

A free application to browse and search the journal's content is now available for Android based mobiles and devices. The application provides "Table of Contents" of the latest issues, which are stored on the device for future offline browsing. Internet connection is required to access the back issues and search facility. The application is compatible with all the versions of Android. The application can be downloaded from <https://market.android.com/details?id=comm.app.medknow>. For suggestions and comments do write back to us.