



Clinical case report based study

Successful management of Ellis type III left anterior descending artery perforation following percutaneous coronary intervention by a covered stent: Successfully resolved the dramatic complication



Sunil Kumar Srinivas, Soumya Patra*, Rangaraj Ramalingam, Navin Agrawal, Tanveer Syed, Ravindranath K. Shankarappa, Cholenahalli Nanjappa Manjunath

Department of Cardiology, Sri Jayadeva Institute of Cardiovascular Sciences & Research, Bangalore, Karnataka 560069, India

ARTICLE INFO

Article history:

Received 8 May 2013

Accepted 12 January 2014

Available online 18 February 2014

Keywords:

Coronary artery

Perforation

Pericardial tamponade

Percutaneous coronary intervention

Covered stent

ABSTRACT

Coronary artery perforation is a rare but catastrophic complication of percutaneous coronary intervention (PCI). Grade III coronary perforation and rupture invariably results in pericardial effusion and tamponade requiring urgent pericardiocentesis. Advances in coronary intervention have increased the opportunity to treat coronary artery perforation. We are reporting a case of 55 years old hypertensive female who presented with effort angina. Coronary angiogram revealed significant stenosis in the left anterior descending coronary artery. Post PCI, she had Ellis type III coronary perforation and pericardial tamponade and cardiogenic shock. The patient was resuscitated, pericardiocentesis done, autologous blood transfusion given and covered stent deployed.

Copyright © 2014, SciBiolMed.Org, Published by Reed Elsevier India Pvt. Ltd. All rights reserved.

1. Introduction

Percutaneous coronary intervention (PCI) is now undoubtedly an indispensable option for the treatment of coronary artery disease (CAD).¹ Current advances in stenting technique have allowed interventional cardiologists to bail out most complications. Coronary perforation (CP) is still a dreaded complication of PCI.² Ellis type 3 rupture is especially associated with high morbidity and mortality; adequate and prompt treatment often amounting to the requirement for pericardiocentesis is essential to rescue such severe cases.³ Here, we are reporting a case of Ellis type III CP of left anterior descending coronary artery (LAD) immediately following PCI with development of hypotension, pericardial tamponade and cardiac arrest. Patient was successfully resuscitated, pericardiocentesis done, autologous blood transfusion given and urgent implantation of a polytetrafluoroethylene (PTFE)-covered stent.

2. Case report

A 55-year-old female presented with effort angina of Canadian Cardiovascular Society (CCS) scale II for the last two months. She was obese and hypertensive without any history of diabetes.

Electrocardiogram was suggestive of left ventricular hypertrophy (LVH) with strain pattern. Echocardiogram showed concentric LVH with normal bi-ventricular function. Treadmill test was positive at 7.1 METS. She had undergone coronary angiogram (CAG) which revealed two tandem lesion of 90% stenosis in the mid segment of LAD (Fig. 1; video 1) and right coronary has proximal total occlusion with retrograde filling from LAD. Due to her symptoms along with significant CAD, she was planned for PCI and stenting to LAD because the occlusion of the RCA appeared to be chronic and was adequately collateralised from the left system therefore it was planned to manage the LAD lesion as the first priority. A 3 × 38 mm Zotarolimus eluting stent (Endeavor Resolute; Medtronic, Inc.) was deployed at 12 atm in LAD covering the two lesions after adequate pre-dilatation. The pressure used for the inflation was below the burst pressure recommended by the manufacturer for the stent. Immediately after stent deployment, she complained severe chest pain and became drowsy and dyspneic. The patient developed significant hypotension and bradycardia at that time. Immediately, cardio-pulmonary resuscitation (CPR) was started, she was intubated and put on mechanical ventilator. After putting her into mechanical ventilator, check CAG revealed an Ellis type III CP in the mid LAD (Fig. 2, Video 2). Echocardiogram also confirmed the presence of large pericardial effusion with pericardial tamponade. So, immediate pericardiocentesis done and 250 ml of blood aspirated from the pericardial cavity. This blood had been given to her as autologous transfusion. At the same time, we had decided to

* Corresponding author.

E-mail address: dr_soumyapatra@rediffmail.com (S. Patra).

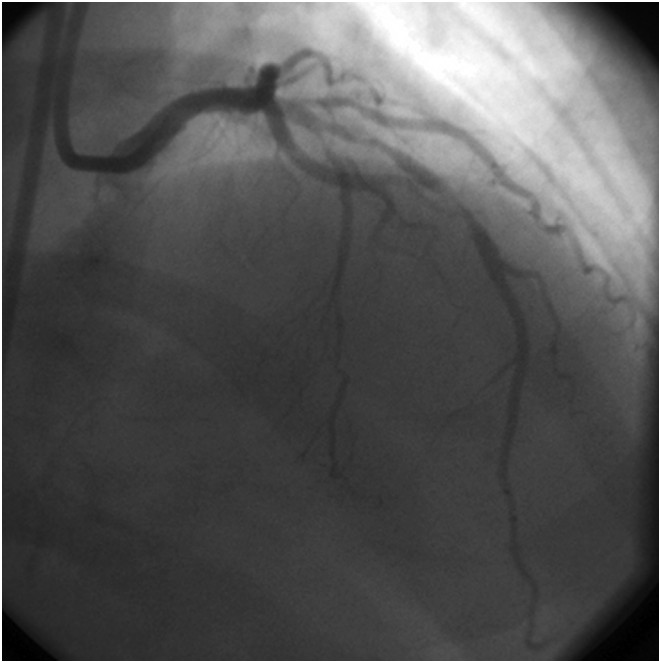


Fig. 1. CAG (RAO cranial view) showed two tandem lesion of 90% stenosis in the mid segment of LAD.

close this perforation by using a PTFE covered stent. A 3.5×16 mm Graftmaster covered stent (Abbott Vascular) was deployed at 12 atm in the mid LAD to close the perforation (Fig. 3, Video 3). Post stent deployment, there was complete sealing of the CP. Later, proximal part of drug eluting stent (DES) and its overlapping part with covered stent were post dilated by using a non compliant (Sprinter RX, Medtronic) balloon at 14 atm. After post dilatation, there was TIMI III flow without any residual leak in the LAD (Fig. 4, Video 4). Her vitals became stable after the procedure and she was

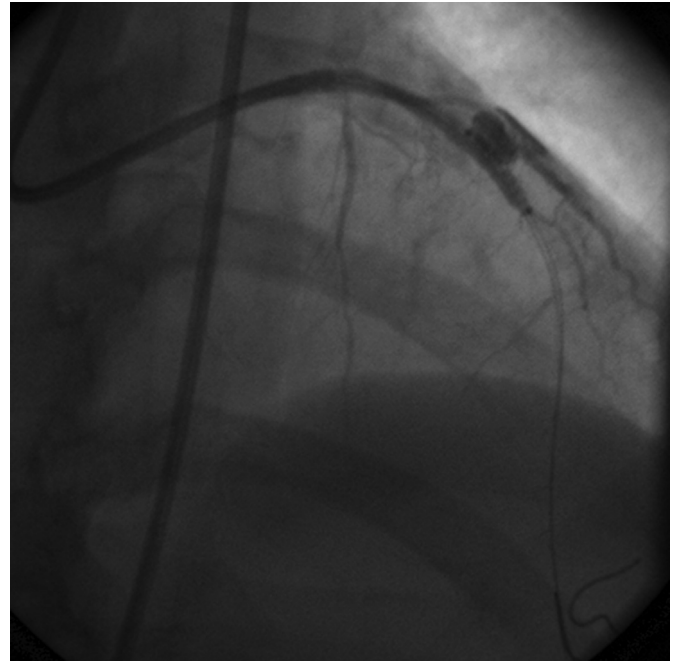


Fig. 3. A PTFE covered stent was deployed in the mid LAD to close CP.

extubated on the very next day and discharged 5 days after the procedure. Follow-up over last 6 months, she is doing well and without having any effort angina.

Supplementary video related to this article can be found online at <http://dx.doi.org/10.1016/j.jcdr.2014.01.003>.

3. Discussion

Grade III CP or coronary rupture although is extremely rare but well recognized complication of PCI.⁴ Grade III CP is defined by the Ellis criteria as a perforation resulting in extravasation of blood

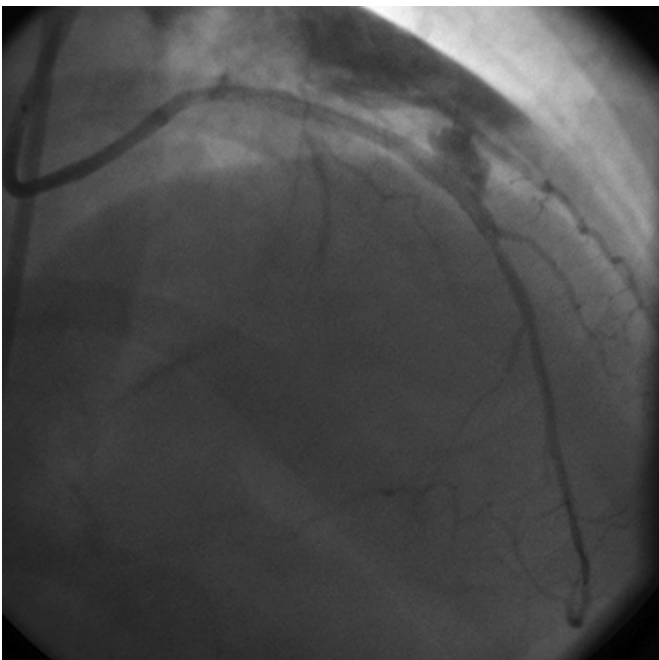


Fig. 2. Check CAG revealed an Ellis type III CP in the mid LAD.

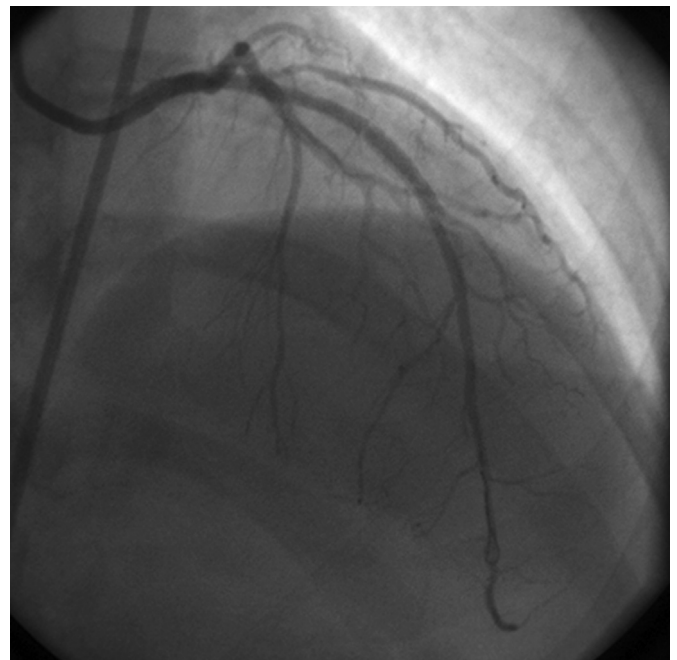


Fig. 4. Final result showed TIMI III flow without any residual leak in the LAD.

through a frank perforation (>1 mm) or spilling into an anatomic cavity.⁵ The incidence of grades I to III coronary perforation range from 0.1% to 3.0%.⁴ The key risk factors which are considered to predispose to the causation of perforation are advanced patient age, female gender and the use of ablative devices.⁵ Grade III CP is the most serious form of perforation with a high incidence of mortality rates which may range from 7% to 44% of cases. It is also associated with very high rates of cardiac tamponade which may be as high as 40% and the need for emergency coronary artery bypass grafting (CABG) ranges between 20% and 40%.⁷ Type 1 and 2 perforations are predominately caused by hydrophilic and stiff wires and the course of these is usually mildly symptomatic and does not require pericardial drainage or surgical intervention.⁸ Type 3 perforations are more often associated with stent placement by over dilatation or oversized stent placement as might be the cause in our case or during aggressive usage of athero-ablative devices. Most cases of grade III CP can be managed with percutaneous methods.⁷ Treatment modalities include prolonged balloon inflation, PTFE covered stent implantation with or without the requirement of pericardiocentesis for cardiac tamponade. Rare cases may require an emergency CABG and microcoil embolization. Reversal of heparin anticoagulant antglycoprotein IIb/IIIa inhibitors (GPI) activity is often required as a part of the therapeutic strategy.⁹ Often a combination of these techniques is required to achieve adequate hemostasis. Newer techniques such as covered stent deployment have led to a decrease in the requirement of emergency CABG.⁹

The incidence of CP with a higher proportion of grade III perforation appears to be increasing because of higher rates of PCI in complex patient and lesion subgroups and the aggressive usage of atheroablative strategies with the widespread use of GP IIb-IIIa inhibitors.^{10,11} Though covered stent have been reported to increase thrombogenicity, there are now several reports of the use of covered stents to seal CP with good and lasting results.^{5,6} This strategy is more effective if the perforation is located in the proximal or mid-portion of the index vessel and the guidewire is correctly positioned distally in the true lumen.⁶

In our case, though we had deployed the stent at a high pressure but the pressure was lower than the burst pressure recommended by the manufacturer and it seemed that oversizing of stent was the cause CP as the index vessel diameter was probably less than 3 mm. We performed immediate resuscitation, urgent pericardiocentesis, autologous transfusion and immediate covered stenting with a PTFE stent to close the perforation which eventually proved to be successful in the management of CP in our case. The activated clotting time in our case was 225 s and injection of protamine was not given to revert the anticoagulant action of heparin as performed immediate stenting to seal the perforation. Though patient was intubated and put on mechanical ventilator to tide over the

crisis period but her vitals became stable after covered stenting. Finally, she was successfully extubated on next day and discharged 5 days after admission.

4. Conclusion

Though grade III CP is a dramatic, dreaded and lethal complication of PCI but it can be managed successfully by immediate diagnosis and prompt treatment which involves sealing of the perforation by a covered stent.

Contributors

SKS, SP, RR & ST were involved in the management of this patient. SKS & SP & NA reviewed the literature and drafted the manuscript. RR & CNM corrected the manuscript.

Conflicts of interest

All authors have none to declare.

References

- Goel PK, Moorthy N. Successful conservative management of coronary artery rupture: role of post pericardiotomy adhesions as a protective barrier. *Cardiovasc Interv Ther.* 2013;28:131–134.
- Ziakas A, Economou F, Feloukidis C, Kiratlidis K, Stiliadis I. Left anterior descending artery perforation treated with graft stenting combining dual catheter and side branch graft stenting techniques. *Herz.* 2012;37:913–916.
- Komatsu I, Hirano K, Takimura H, et al. A case of coronary artery perforation with successful hemostasis using over-the-wire balloon and autologous blood perfusion. *Cardiovasc Interv Ther.* 2013;28:197–201.
- Shirakabe A, Takano H, Nakamura S, et al. Coronary perforation during percutaneous coronary intervention. *Int Heart J.* 2007;48:1–9.
- Sardella G, Mancone M, Fedele F. Coronary artery perforation during primary PCI: an easily resolved case for a dramatic complication. *Eur Heart J.* 2007;28:2109.
- Totsugawa T, Kuinose M, Yoshitaka H, et al. Surgical treatment for Ellis type 3 coronary perforation during percutaneous catheter intervention. *Circ J.* 2012;76:377–381.
- Meguro K, Ohira H, Nishikido T, et al. Outcome of prolonged balloon inflation for the management of coronary perforation. *J Cardiol.* 2013;61:206–209.
- Copeland KA, Hopkins JT, Weintraub WS, Rahman E. Long-term follow-up of polytetrafluoroethylene-covered stents implanted during percutaneous coronary intervention for management of acute coronary perforation. *Catheter Cardiovasc Interv.* 2012 Jul 1;80:53–57.
- Kini AS, Rafael OC, Sarkar K, et al. Changing outcomes and treatment strategies for wire induced coronary perforations in the era of bivalirudin use. *Catheter Cardiovasc Interv.* 2009;74:700–707.
- Kiernan TJ, Yan BP, Ruggiero N, et al. Coronary artery perforations in the contemporary interventional era. *J Interv Cardiol.* 2009;22:350–353.
- Al-Lamee R, Ielasi A, Latib A, et al. Incidence, predictors, management, immediate and long-term outcomes following grade III coronary perforation. *JACC Cardiovasc Interv.* 2011;4:87–95.