

A STUDY ON LENGTH OF MESOAPPENDIX AND ITS CLINICAL IMPLICATION

Dr Manisha Chaudhari 1 Dr bhadresh p vagela 2 ,Dr Urmila patelia 3

1 Associate professor, Department Of anatomy Dr M K SHAH Medical Collage, Chandkeda ,Ahmedabad, India

2 Associate Professor NAMO Medical collage,Silvasa

3Gmers medical collage,Vadnagar.

Corresponding author:Dr Manisha Chaudhari,

emailid:drmanishachaudhari6@gmail.com.plot no 1362/2,Sector 4 D, Gandhinagar,Gujarat.

ABSTRACT:

Introduction: Appendix is connected by a short mesoappendix to the lower part posterior (left)layer of the ileal mesentery. This fold is usually triangular, extending almost to the appendicular tip along the whole tube. The mesoappendix has a free border which carries the blood supply to the organ, by the appendicular artery; a branch from the ileocolic artery. This study has been undertaken to investigate certain anatomical features such as the extent of the mesoappendix

Material and method: This study was conducted on 91 cases from the dissection laboratory with an age range of 50-90 years, The dissection was performed in dissection hall of various medical collage of Ahmedabad.

Result: In present study mesoappendix was not reach at tip of vermiform appendix in 50cases (54.95%) and mesoappendix is reach at tip of vermiform appendix in 65cases (45.05%).

CONCLUSION: Appendix is supplied by aend artery which is one of cause of occurrence of appendicitis.Appendicular artery which is branch of inferior division of iliocolic artery which goes through appendix along mesoappendix. In the present study variation in length of mesoappendix was seen from which we can understand about blood supply and vascularity of appendix. The appendicular artery runs first in the free margin of the mesoappendix and then. close to the appendicular wall, where it may be thrombosed in appendicitis ,leading to ischemic necrosis and perhaps rupture of the appendix, there is no collateral circulation for appendicular artery is an end artery.

KEY WORDS: Mesoappendix, appendix,

INTRODUCTION: The appendix was probably first noted as early as the Egyptian civilization (3000 BC).Aristotle and Galen did not identify the appendix because they both dissected lower animals, which do not have appendices. Celsus,2nd century Greek philosopher however, probably discovered the appendix because he was allowed to dissect criminals. In 1492 Leonardo da Vinci first depicted the appendix in anatomic drawings.In1521 Jacopo Beregari da Capri, a professor of anatomy in Bologna, identified the appendix as anatomical structure. Phillipe Verheyen in 1710 coined the term appendix vermiformis. Embryologically, the appendix is a continuation of the cecum and is first delineated during the fifth month of gestation. The appendix does not elongate rapidly as the rest of the colon, thus forming a wormlike structure.

Appendix is connected by a short mesoappendix to the lower part posterior (left) layer of the ileal mesentery. This fold is usually triangular, extending almost to the appendicular tip along the whole tube. The mesoappendix has a free border which carries the blood supply to the organ, by the appendicular artery; a branch from the ileocolic artery. This study has been undertaken to investigate certain anatomical features such as the extent of the mesoappendix

Mesoappendix

The mesentery of the appendix is a triangular fold of peritoneum around the vermiform appendix. It is attached to the posterior surface of the lower end of the mesentery of the small intestine close to the ileocecal junction. It usually reaches the tip of the appendix but sometimes fails to reach the distal third; in that case a vestigial low peritoneal ridge containing fat is present over distal third. It encloses the blood vessels, nerves and lymph vessels of the vermiform appendix, and usually contains a lymph node.

Blood Supply

The main appendicular artery, a branch from the lower division of the ileocolic artery, runs behind the terminal ileum and enters the mesoappendix a short distance from the appendicular base. Here it gives off a recurrent branch, which anastomoses at the base of the appendix with a branch of the posterior caecal artery. The anastomosis is sometimes extensive. The main appendicular artery approaches the tip of the organ, at first near to, and then in the edge of, the mesoappendix. The terminal part of the artery lies on the wall of the appendix and may be thrombosed in appendicitis, which results in distal gangrene or necrosis. Accessory arteries are common, and many individuals may possess two or more arteries of supply.

Mesoappendix appear at 8th week of intrauterine life with the appearance of appendix and its extension occur after birth by differential growth of caecum¹

The extent of mesoappendix not related with age, height and weight of the person²

MATERIAL AND METHOD

This study was conducted on 91 cases from the dissection laboratory with an age range of 50-90 years. The cadavers were embalmed through carotid and femoral arterial perfusion of formaldehyde solution, spirit, water and glycerine and preserved in a weak formalin solution before dissection. The dissection was performed in dissection hall of various medical collage of Ahmedabad. Ahmedabad in 91cadavers The cadavers were donated material. Dissection is done "According to Cunningham’s Manual of Practical Anatomy, Fifteenth edition".

RESULT

MESOAPPENDIX

Serial number	Mesoappendix	Male	Female	Total	%
1	Mesoappendix not reach at tip of appendix	40	10	50	54.95%
2	Mesoappendix reach at tip of appendix	29	12 Type equation	41	45.05%
Total		69	32	91	100%

In present study mesoappendix was not reach at tip of vermiform appendix in 50cases (54.95%) (Figure: 1.) and mesoappendix is reach at tip of vermiform appendix in 65cases (45.05%).(Figure:2)

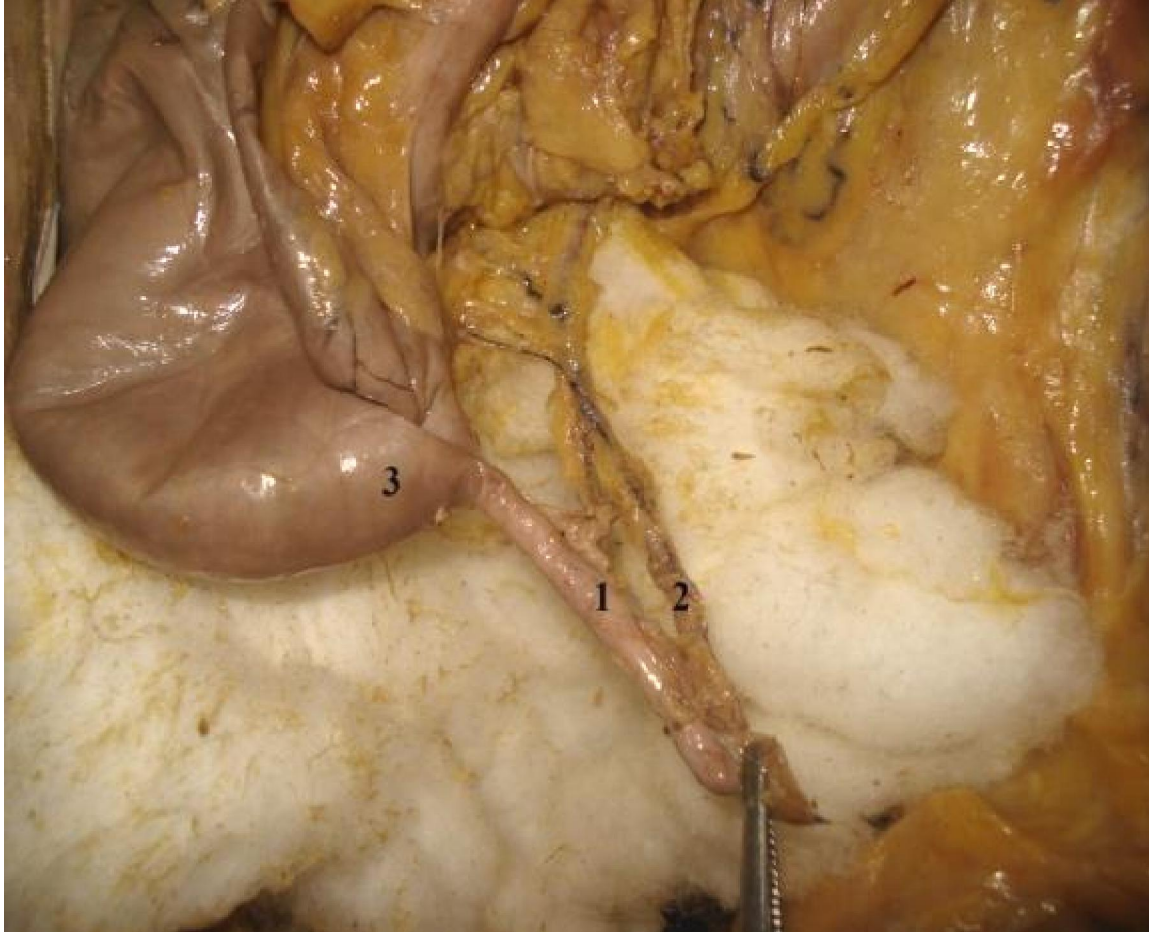


FIGURE NUMBER; 1

In this above figure appendicular artery reach at tip of vermiform appendix.

1. Vermiform appendix.
2. Appendicular artery.
3. Caecum.

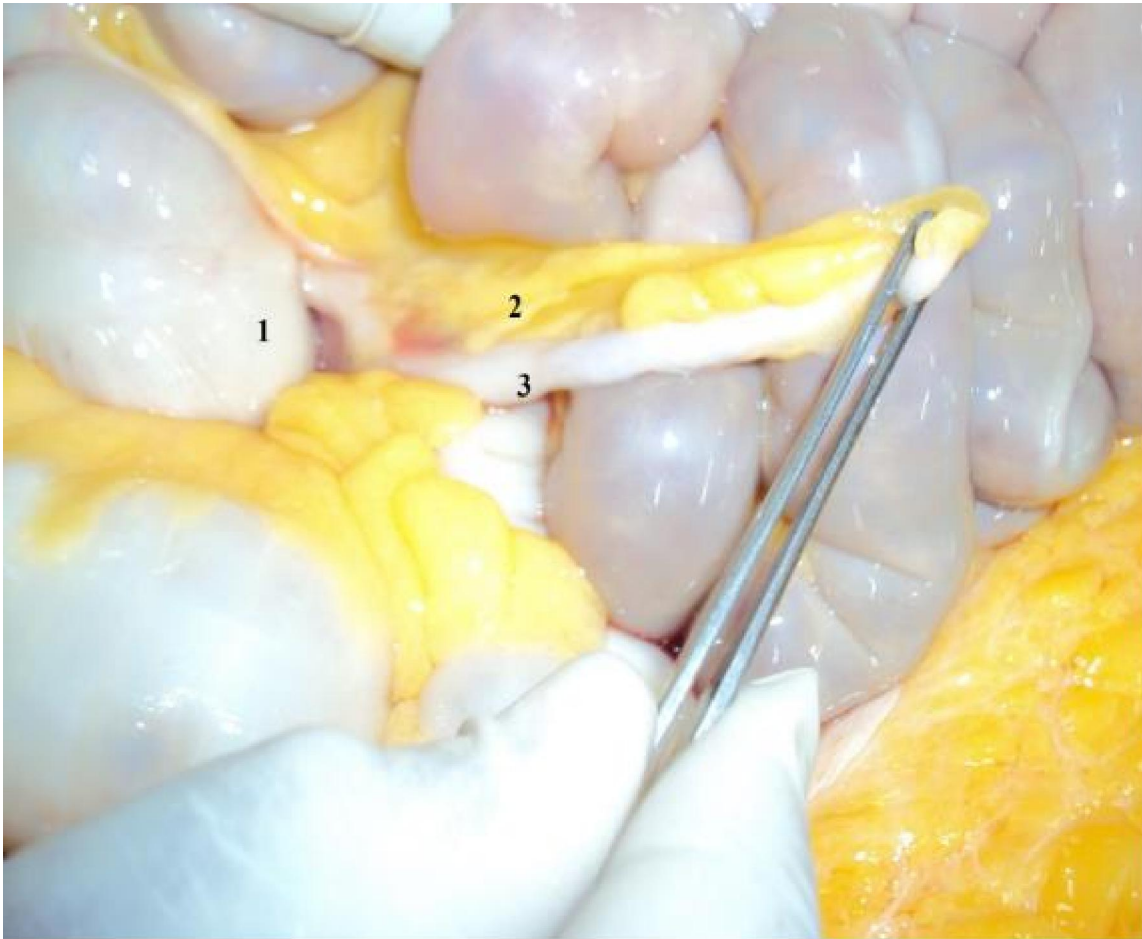


FIGURE NUMBER: 2

Above figure showing mesoappendix reach at tip of vermiform appendix.

1. Caecum.
2. Mesoappendix.
3. Vermiform appendix.

DISCUSSION

In present study mesoappendix was not reach at tip of vermiform appendix in 50cases (54.95%) (Figure: 1.) and mesoappendix is reach at tip of vermiform appendix in 65cases (45.05%).(Figure:2)

This cross sectional study was carried out to advance our knowledge regarding the extent of mesoappendix in Bangladeshi people and also to find out the variations in the anatomical positions of the vermiform appendix in Bangladeshi population and their distribution according to the sex. A total of 100 (60 male and 40 female) specimens of vermiform appendix were collected of different age and sex during postmortem examination in the morgue of Mymensingh, Medical College from July 2006 to June 2007. Data was collected by convenient sampling technique The two thirds extension of mesoappendix was found in 45% cases where as in pelvic position it was 26 (14male and 12 female) cases. Half and whole extension of

mesoappendix were found in 31% and 24% cases respectively. Among half extension of mesoappendix, retrocaecal position were found to be more (12) than other positions. In whole extension of vermiform appendix pelvic position were found to be common (16) than others³

We hypothesize that the vermiform appendix is a mobile organ that is important for immune response. It can be named as “policeman of the abdomen”, just like the greater omentum. The appendix is mobile due to the presence of mesoappendix and probably it tries to move in the direction of any infection in the abdomen. Its position may not be fixed in the living person. It may keep changing according to the immunological needs of the abdominal cavity. Though the appendix cannot move as much as the greater omentum, it might sense the areas of infections by moving in that direction (in this regards we can call it “antenna” or “radar” of the abdomen). The information gathered by vermiform appendix might be transferred through the blood to the greater omentum and then the greater omentum might move to the direction of infection and seal it off. Probably the commonest position of the appendix (retrocaecal) is its resting position. It might rest in this position if there is no infection in the abdomen. A surgeon or an anatomist can see the position of the appendix only during the surgery or dissection. There are no studies on various positions of the appendix in the same individual on different days/weeks/months/years. Studies of the positions of appendix every month in an individual using a scanner might confirm the hypothesis that vermiform appendix keeps changing its position according to the presence of infection.⁴

This cross sectional study was done in 52 cadavers used for routine dissection for undergraduates. Mesoappendix reached the tip in 69.23% of cases.

The appendix is supplied by a small artery that does not anastomose with other arteries. The blind end of the appendix is supplied by the terminal branches of the appendicular artery. Inflammatory oedema of the appendicular wall compresses the blood supply to the appendix and often leads to thrombosis of the appendicular artery. These conditions commonly result in necrosis or gangrene of the appendicular wall, with perforation⁶

Failure of the mesoappendix to reach the tip probably reduces the vascularization of the tip of the organ making it more liable to become gangrenous and hence early perforation during inflammation⁷

Failure of the mesoappendix to reach the tip reduces the vascularization to the tip of the organ making it more liable to become gangrenous and hence early perforation occurs during inflammation⁸

CONCLUSION

Appendix is supplied by end artery which is one of cause of occurrence of appendicitis. Appendicular artery which is branch of inferior division of iliocolic artery which goes through appendix along mesoappendix. In the present study variation in length of mesoappendix was seen from which we can understand about blood supply and vascularity of appendix. The appendicular artery runs first in the free margin of the mesoappendix and then close to the appendicular wall, where it may be thrombosed in appendicitis ,leading to ischemic necrosis and perhaps rupture of the appendix, there is no collateral circulation for appendicular artery is an end artery.

Ethical statement

Ethical committee approval taken from institute.

Financial disclosure

This research did not receive any specific grant from funding Agencies in the public, commercial, or not-for-profit sectors.

Declaration of competing interest

The authors report no conflicts of interest.

REFERENCE:

1. Ross MH, Koye GI, Pawlina W, editors. Histology: A text and atlas, 5th ed. Baltimore: Willims and Wilkins; 2005. P. 528-574
2. Snell RS. Clinical Anatomy. 7th ed. Baltimore: Lippincott William and Wilkins; 2004. P. 215 – 7.
3. 3.Rahman MM Khalil M Khalil M Sultana SZ Mannan S Nessa A et al. Extent of Mesoappendix of Vermiform Appendix in Bangladeshi People.Journal Bangladesh Soc Physiol. 2009 June; 4(1): 20-23.
4. 4.B. Satheesha Nayak. Why the tip of vermiform appendix has variable position? Med Hypotheses. 2010 Dec;75(6):682-3. Epub 2010 Sep 9.
5. Geethanjali HT, Lakshmi Prabha Subhash, Tumkur Anatomica A Study of Variations in the Position of Vermiform Appendix. Karnataka, Vol-5, (2) Page 17-23 (2011)
6. Borley NR. Editor, Microstructure of the large intestine. In: Berkovitz KBB, Borley NR, Crossman AR, Davis MS, Fitzgerald MJT, Glass J, et. al editors. Grays anatomy: the anatomical basis of clinical practice. 39th edi, Edinburgh: Elsevier Churchill Livingstone; 2005, P. 1173-86.
7. Das S. A concise Text book of surgery. 1st ed. Calcutta; S.D. Publishers; 1996, P.966.
8. Anderson, R.E.; Houganer, A. and Thalin, A.J.D. (1992):Diagnostic accuracy and perforation rate in appendicitis :Association with age and sex of the patients and with appendicectomy rate. European Journal of Surgery. 158 :37-41.