

An Insight of Treatment Modalities of Distal Radius fractures

Abdulbari Sulayman Al Mabrouk, Hossam Fathi Mahmoud, Mohamed Abdallah M. Abdelsalam, and Riad Mansour Megahed

Orthopedic Surgery Department, Faculty of Medicine - Zagazig University

Corresponding author: Abdulbari Sulayman Al Mabrouk

E-mail: abdelbareedres7@gmail.com

Abstract

Background: Distal radius fracture is one of the most common fractures in adults, predominantly in white and older populations in high income countries. Patient usually reports falling on outstretched hand (FOSH). Other mechanisms include: RTA (road traffic accident), direct trauma, and FFH (fall from height). Specific mechanisms imply greater or lesser degrees of injury. After (FOSH) the prominent thenar eminence takes most of the force, and the fracture of the distal end radius occurs, while the TFCC is still intact, unless there is a rotatory element. If radius rotates into supination and if the force continues the ulnar styloid is avulsed. There are numerous treatment modalities available to orthopedic surgeons for distal radius fracture; these include closed reduction and casting, closed reduction and percutaneous pinning.

Keywords: Distal radial fracture

Introduction

The distal radius fracture can be caused by fall on outstretched arms or by direct trauma of distal radius. A fracture with mal position will typically leave patients with wrist deformities and disability (1).

Treatment of distal radius fracture

The basic principal treatment of these fractures is to obtain accurate fracture reduction and then to use a method of immobilization that will maintain and hold the reduction. A number of options for treatment are available to prevent the loss of reduction in an unstable fracture of the distal radius.

■ Factors affecting treatment include:

Local factors: bone quality, soft tissue injury, fracture comminution, fracture displacement, and energy of injury.

Patient factors: patient age, lifestyle, occupation, hand dominance, associated medical conditions, associated injuries, and compliance

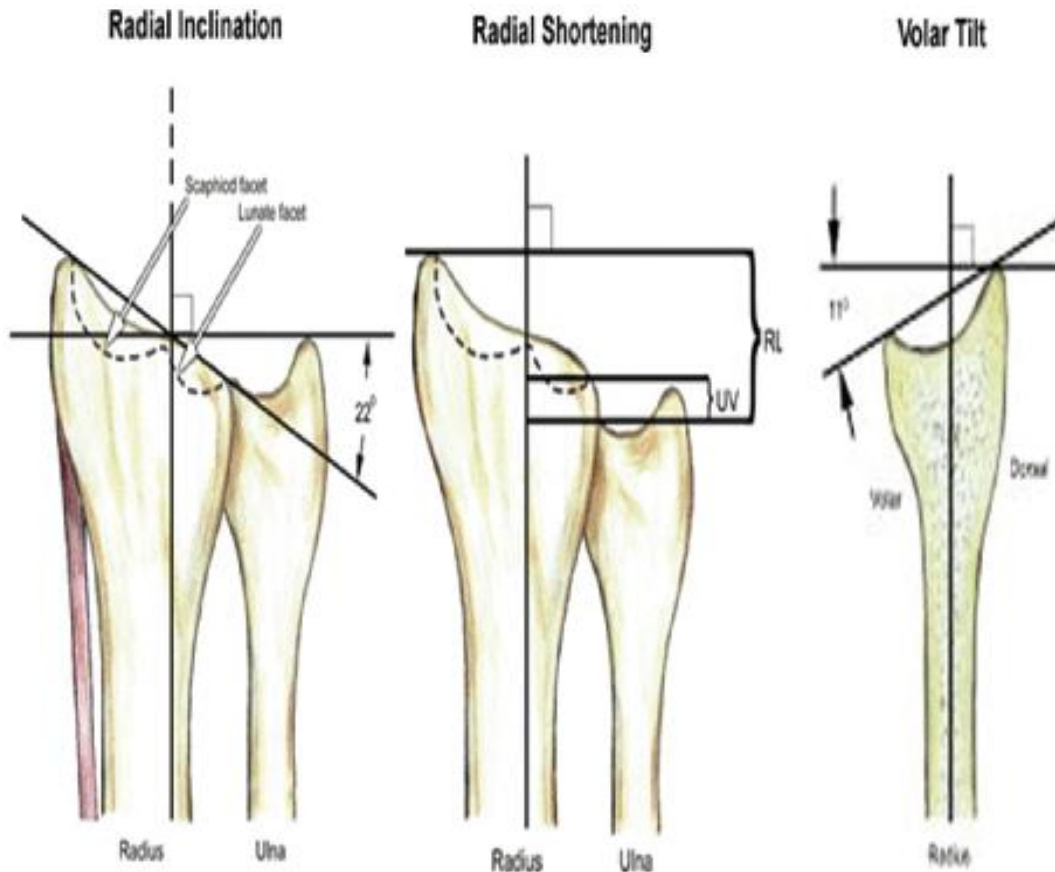
■ **Radiographic alignment parameters** for acceptable reduction in an active, healthy patient include:

Radial length: within 2 to 3 mm of the contralateral wrist

Volar tilt: neutral tilt (0 degrees), but up to 10 degrees dorsal angulation

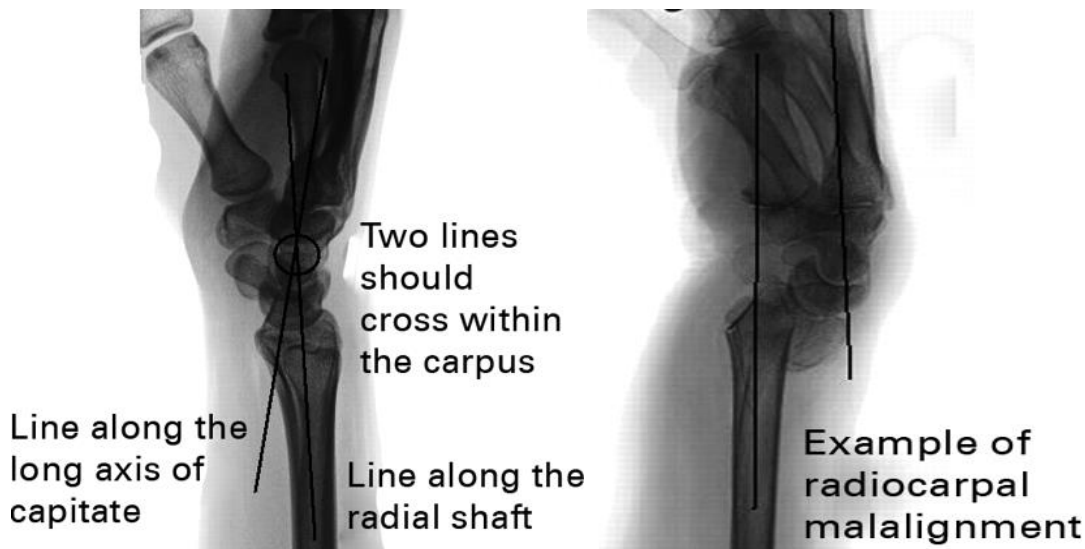
Intra-articular step-off: < 2 mm

Radial inclination: < 5-degree loss



(Figure 1). Tilt and angles at distal radius. (2)

Carpal alignment: after distal radius fracture, it may have the most influence on outcome following distal radius fracture. Carpal alignment is measured by the intersection of two lines on the lateral radiograph: one parallel and through the middle of the radial shaft and the other through and parallel to the capitate. If the two lines intersect within the carpus, then the carpus is aligned. If the two lines intersect out with the carpus, then the carpus is mal aligned. (2)



(Figure 2) carpal alignment. (2)

Types of management:

A) Non operative:

All displaced fractures need closed reduction, even if it is expected that surgical management will be used. Reduction of the fracture helps to limit post injury swelling, provides pain relief, and relieves compression on the median nerve. Cast immobilization is indicated for: nondisplaced or minimally displaced fractures, displaced fractures with a stable fracture pattern expected to unite within acceptable radiographic parameters and low-demand elderly patients in whom future functional impairment is less of a priority than immediate health concerns and/ or operative risks. (3)

■ Technique of closed reduction (dorsally tilted fracture):

The distal fragment is hyperextended. Traction is applied to reduce the distal to the proximal fragment with pressure applied to the distal radius. A well-molded long arm splint is applied, with the wrist in neutral to slight flexion. One must avoid extreme positions of the wrist and hand. The cast should leave the metacarpophalangeal joints free. Once swelling has subsided, a well-molded cast is applied. (3)

The ideal forearm position, duration of immobilization, and need for a long arm cast remain controversial; no prospective study has demonstrated the superiority of one method over another. Extreme wrist flexion should be avoided, because it increases carpal canal pressure (and thus median nerve compression) as well as digital stiffness. Fractures that require extreme wrist flexion to maintain reduction may require operative fixation. The cast should be worn for approximately 6 weeks or until radiographic evidence of union has occurred. Frequent radiographic examination is necessary to detect loss of reduction. (4)

B) Operative:

■ Indications

1) Articular step-off : It has become apparent through the work of several authors that restoration of articular congruency is potentially of greater importance than other criteria. It has been reported that the development of post-traumatic osteoarthritis in 100% of wrists with articular incongruities of 2.0 mm or more. However, other investigators found that displacement of even 1.0 mm resulted in pain and stiffness of wrist. (5)

2) Secondary loss of reduction : Several factors have been associated with re-displacement following closed manipulation of a distal radius fracture:

-The initial displacement of the fracture: the greater the degree of displacement, the more energy is imparted to the fracture making closed treatment most likely will be unsuccessful.

-The patient's age: Elderly patients with osteopenic bones tend to displace, particularly late.

-The extent of metaphyseal comminution (the metaphyseal defect).

Displacement following closed treatment is a predictor of instability, and repeat manipulation is unlikely to result in a successful radiographic outcome. (3)

3) Metaphyseal comminution or bone loss.

4) DRUJ incongruity.

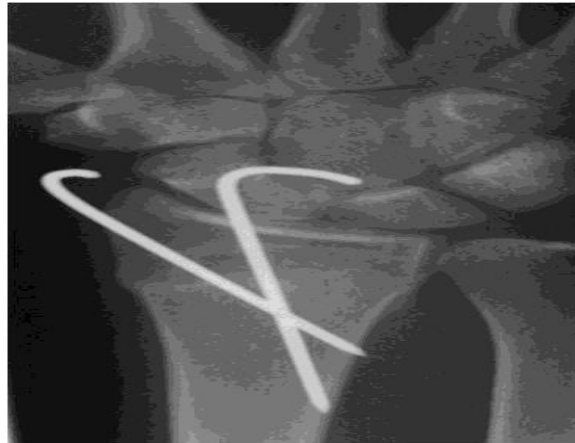5) Open fractures.

Operative Techniques :

1- Percutaneous pinning:

This is primarily used for extra-articular fractures or two-part intra-articular fractures. It may be accomplished using two or three Kirschner wires placed across the fracture site, generally from the radial styloid, directed proximally and from the dorsoulnar side of the distal radial fragment directed proximally. Trans-ulnar pinning with multiple pins has also been described. Percutaneous pinning is generally used to supplement short arm casting or external fixation. The pins may be removed 6 to 8 weeks postoperatively, with the cast maintained for an additional 2 to 3 weeks. (6)

Kapandji “intrafocal” pinning: This is a technique of trapping the distal fragment by buttressing to prevent displacement. (7)

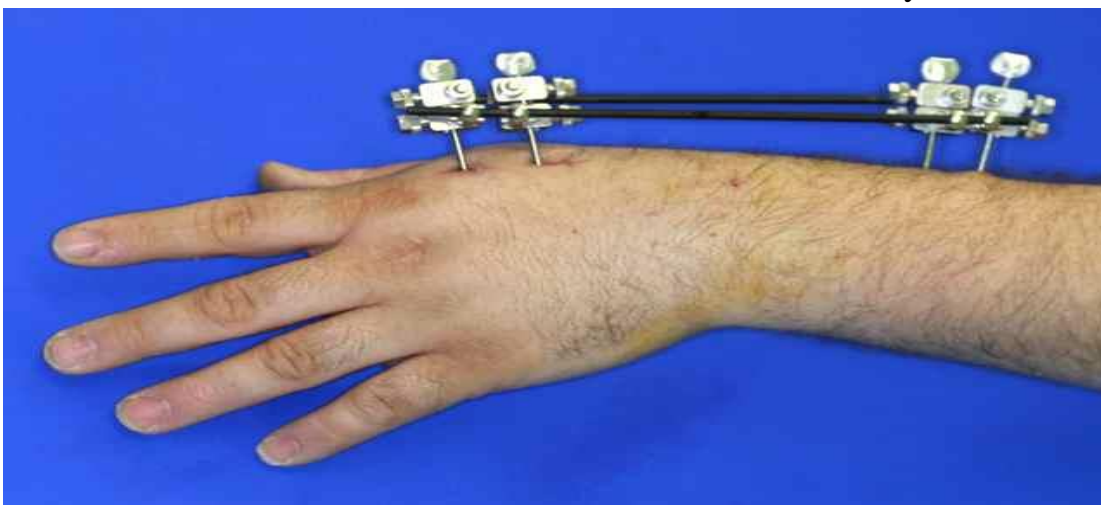


(Figure 3): Pinning of distal radius fracture. (6)

2-External fixation:

External fixation is generally accepted as superior to plaster immobilization in the young patients with an intra-articular comminuted fracture of the distal radius. Other indications for external fixation include some unstable extra-articular fractures with significant comminution and failure to maintain reduction after an initial attempt at closed management in a cast, certain situations of multiple trauma, presence of dysfunctional contralateral limb, severe open fractures with significant soft tissue injury and neurovascular compromise, and bilateral injuries. (8)

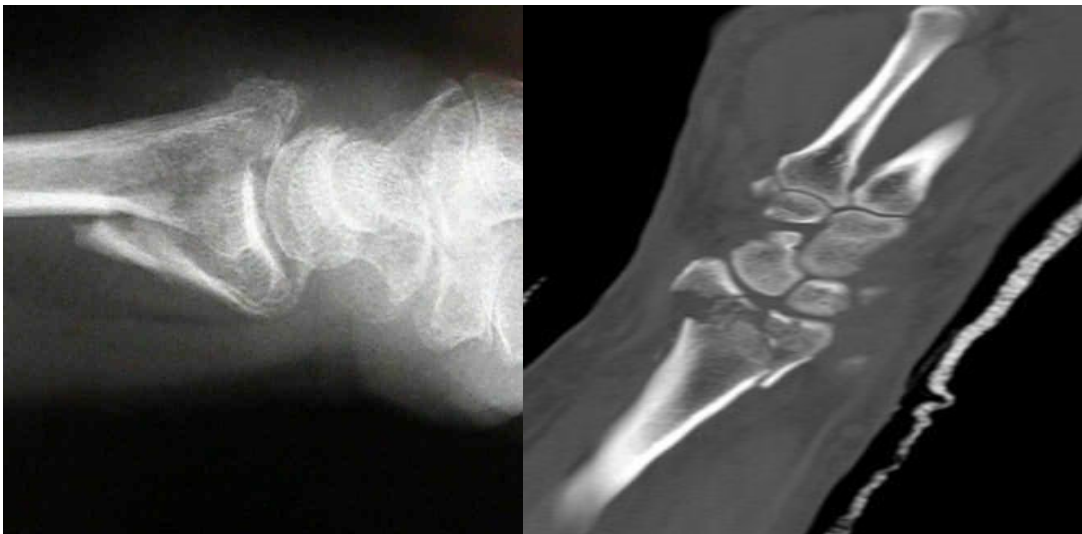External fixation relies upon the principle of ligamentotaxis to apply traction and restore displacements. The use of an external fixation device is the only practical means of overcoming the force of the muscles of the forearm that pull comminuted distal radial fractures into a collapsed position. The use of an external fixator in the treatment of unstable intra-articular fractures of the distal radius has recently received support (9).



(Figure 4): External fixator for distal radius fracture. (8)

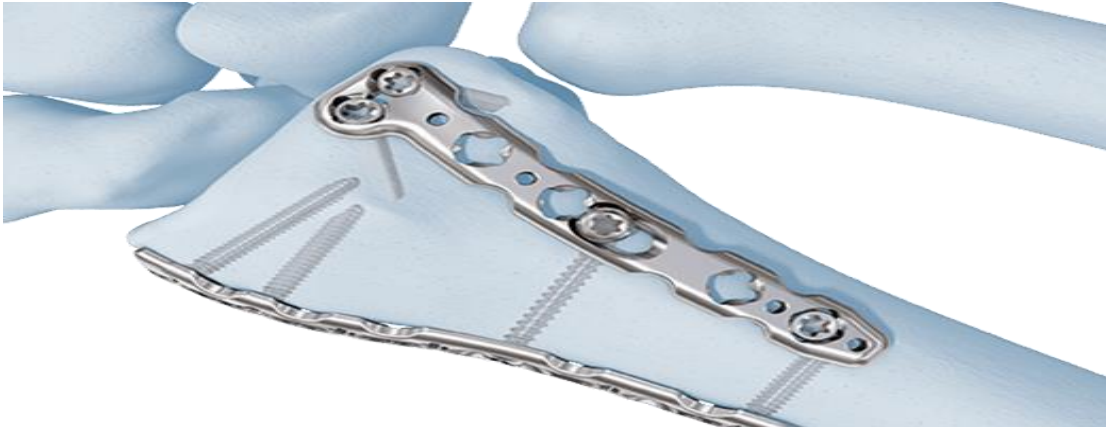
3-Open reduction and internal fixation:

There are two groups of fractures for which open reduction and internal fixation is advisable. The first group includes the two-part shear fracture (Barton fracture), which actually is a radio-carpal fracture dislocation. Although anatomical reduction is possible by closed means in some cases, these fractures are very unstable and difficult to control in plaster. The second group includes complex intra-articular fractures in which the articular fragments are displaced, rotated or impacted and are not amenable to reduction through a limited operative exposure (10)



(Figure 5): Right: volar Barton fracture Left: intra-articular distal radius fracture. (58)

a)Dorsal plating: This has several theoretic advantages. It is technically familiar to most surgeons, and the approach avoids the neurovascular structures on the palmar side. The fixation is on the compression side of the fracture and provides a buttress against collapse. Initial reports of the technique demonstrated successful outcomes with the theoretic advantages of earlier return of function and better restoration of radial anatomy than seen with external fixation. Dorsal plating has been associated with extensor tendon complications, but this complication is overcome by low profile plates. (11)

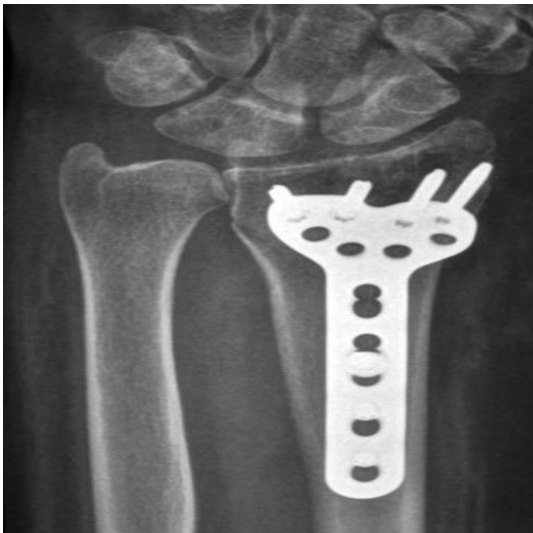

(Figure 6): Dorsal plating of distal radius with low profile plates. (11)

b) Volar plating: a) non-locking : the primary indication is a buttress plate for the shear fracture of the volar Barton. This construct may be unable to maintain fracture reduction in the presence of dorsal comminution. b) locked plating: Locked volar plating has increased in popularity because this implant has been shown to stabilize distal radius fractures with dorsal comminution. It has surpassed external fixation as the most popular mode of fracture fixation of the distal radius.

The dorsal side of the radius may be accessed through an extension of the volar approach. **(12)**

c) Fragment specific plating: Has been advocated for more complex fracture patterns involving several aspects of the radial and ulnar columns. **(13)**



**(Figure 7): Volar plate. (12)
distal radius plate. (13)**



(8): Fragment specific

Postoperative care:

Post-operative X ray will be done for all patients immediately to check the reduction and wire length, and for assessment of radial length, radial inclination, and volar tilt, then 3, and 6 weeks after surgery.

Wires are removed approximately 4-6 weeks postoperatively.

The patient remains in a cast approximately for 2 weeks after wires removal.

(14).

References.

- 1. Norwegian Orthopaedic Association - The Norwegian Medical Association (2015):** Treatment of distal radius fractures in adults.
- 2. Knirk J, Jupiter JB. (1986):** Intra-articular fractures of the distal end of the radius in young adults. *J Bone Joint Surg*;68:647-59.
- 3. Kenneth A. Egol, Kenneth J. Koval and Joseph D. Zuckerman. (2015):** Handbook of fractures— 5th ed.; p266-278.
- 4. Gupta A.(1991):** The treatment of Colles' fractures. Immobilisation with the wrist dorsiflexed. *J Bone Joint Surg Br*; 73:312-5.
- 5. Trumble TE, Culp RW, Hanel DP, et al. (1999):** Intra-articular fractures of the distal aspect of the radius. *Instr Course Lect*; 48:465-80.
- 6. Rayhack JM.(1993):** The history and evolution of percutaneous pinning of displaced distal radial fractures. *Orthop ClinNorth Am*; 24:287-300.
- 7. Kapandji A (1976):** Internal fixation by double intrafocal plate. Functional treatment of nonarticular fractures of the lower end of the radius (author's transl). *Ann Chir.* 1976;30(11-12):903-8.
- 8. Seitz WH Jr. (1993):** External fixation of distal radius fractures. Indications and technical principles. *Orthop Clin North Am*; 24:255-64.

9. **Cooney WP. (1983):** External fixation of distal radial fractures. ClinOrthop Relat Res;44-9.
10. **Sanjay Meena, Pankaj Sharma, Abhishek Kumar Sambharia et al. (2014):** Fractures of Distal Radius: An Overview Jour of Family Med and Prim Care Octr; 3(4) : p 325- 333.
11. **Ross M, Heiss-Dunlop W. (2010):** Volar angle stable plating for distal radius fractures. In: Slutsky DJ, editor. Principles andPractice of Wrist Surgery. 2nd ed. Philadelphia: Elsevier. p. 126-39.
12. **Soong M, van Leerdam R, Guitton TG, et al. (2011):** Fracture of the distal radius: Risk factors for complications after locked volar plate fixation. J Hand SurgAm; 36:3 9.
13. **Sammer DM, Fuller DS, Kim HM, et al. (2008):** A comparative study of fragment-specific versus volar plate fixation of distal radius fractures. Plast Reconstr Surg. Nov;122(5):1441- 50..
14. **El-Adawy MF, Henawy AT, El Haroon MS. (2018):** Treatment of distal radius fractures with percutaneous pinning. Egypt Orthop J Available at <http://www.eoj.eg.net/text.asp?2018/53/1/44/249273>