Journal of Cardiovascular Disease Research
ISSN: 0975-3583, 0976-2833 VOL 12, ISSUE 07, 2021

Laparoscopic Cholecystectomy in Management of Common Bile Duct Stones

AbdElhafez Mohammad ElShewail, Mustafa Sulayman Abdulhafith, Muhammad Ali Baghdadi, Ahmed Mahmoud Sallam
Department of General, GIT and Hepatobiliary Surgery, Zagazig University Hospital, Egypt.
Corresponding Author: Mustafa Sulayman Abdulhafith
Email: ms0782280@gmail.com

Abstract

Gallbladder stones (GBS) has been identified in the mummy of an Egyptian priestess dated back to about 1500 BC. It presents in approximately 10–15% of the adult population with approximately 20% of these patients experiencing some form of symptoms. Of those experiencing symptoms approximately 3.4 % to 18.8% will eventually have coexisting common bile duct stones (choledocholithiasis or CBDS). The incidence of choledocholithiasis in patients with cholelithiasis increases with age. Laparoscopic Cholecystectomy (LC) is a minimally invasive surgical procedure for removal of a diseased GB. This technique essentially has replaced the open technique for routine cholecystectomies since the early 1990s. At this time LC is indicated for the treatment of cholecystitis (acute/chronic), symptomatic cholelithiasis, biliary dyskinesia, acalculous cholecystitis, gallstone pancreatitis, and GB masses/polyps. These indications are the same for an OC.

Keywords: Laparoscopic cholecystectomy, Gall Stones

Introduction

Gallstone disease is defined by the occurrence of symptoms or complications caused by gallstones in the GB and/or the bile ducts. They are common (10–20% of the global adult population), and more than 20% of people with gallstones will develop symptoms in their lifetime (including biliary colic or infections), usually in adulthood. From a clinical

ISSN: 0975-3583, 0976-2833 VOL 12, ISSUE 07, 2021

perspective and in treatment algorithms, those with asymptomatic stones are not generally classified as having gallstone disease **(1).**

Diagnosis of gallbladder stones diseases:

In general, the clinical symptoms and management of gallstones do not differ between cholesterol and pigment stones, but it depends on the location of the stone (GB versus bile ducts) **(2)**.

A- Clinical diagnosis:

Patients with GBS can present with characteristic symptoms of biliary colic, which is defined as episodic attacks of severe pain in the right upper abdominal quadrant or epigastrium for at least 20–30 minutes with radiation of the pain to the right back or shoulder, which improves with administration of analgesics. In addition, GBS can also cause nonspecific abdominal symptoms, such as epigastric pain and intolerance to fried or fatty foods (characterized by nausea, bloating and flatulence). However, only 60% of patients report the absence of abdominal pain after surgery, indicating that symptoms are neither characteristic nor predictive **(3)**.

B- Radiological diagnosis:

Abdominal ultrasonography is the imaging method of choice for anyone who presents with any of these symptoms, as its diagnostic accuracy for the detection of GBS exceeds 95%. In addition, abdominal ultrasonography can detect complete or patchy calcification of the GB wall (also known as porcelain GB). When there is a strong suspicion of GBS, but a negative abdominal ultrasonography, endoscopic ultrasonography (EUS) or magnetic resonance cholangiography (MRCP) can be performed to detect microlithiasis below the detection limit of abdominal ultra- sonography **(2)**.

LC is a minimally invasive surgical procedure for removal of a diseased GB. This technique essentially has replaced the open technique for routine cholecystectomies since the early 1990s. At this time LC is indicated for the treatment of cholecystitis (acute/chronic), symptomatic cholelithiasis, biliary dyskinesia, acalculous cholecystitis,

ISSN: 0975-3583, 0976-2833 VOL 12, ISSUE 07, 2021

gallstone pancreatitis, and GB masses/polyps. These indications are the same for an OC **(4)**.

I- Indications (5):

- Cholecystitis (Acute/Chronic)
- Symptomatic cholelithiasis
- Biliary dyskinesia
- Acalculous cholecystitis
- Gallstone pancreatitis
- GB masses/polyps

II. Contraindications (5):

- Inability to tolerate pneumoperitoneum or general anesthesia
- Uncorrectable coagulopathy.
- Although GB cancer was once a contraindication to a LC, the current literature supports laparoscopic intervention; but metastatic GB is still contraindicated for LC.

III.Preoperative preparation (5):

- The patient should be medically optimized preoperatively, and laboratory investigated and assessed regarding an ASA class, anticoagulation, cardiopulmonary disease, or pregnancy.

- A low molecular weight heparin should be given 12 hours before surgery in high-risk patients.
- Preoperative antibiotics should be given within 30 minutes of incision with placement of pressure garments on both lower limbs of risky patients.

IV- Technique (6):

1. **Anesthesia:** The operation is done under general anesthesia with endotracheal intubation.

2. **Position of the Patient and surgical team:** Initially patient is fixed on the table in supine position. Peripheral intravenous lines are inserted, electrocardiography, pulse oximetry, and blood pressure monitors are placed. Both arms of the patient are abducted or tucked comfortably at the sides of the operating table. The two laparoscopic towers are situated on either side of the patient's trunk, toward the head. The surgeon stands on the patient's left, and the assistant stands on the right. An additional assistant, if present, can hold the laparoscope, but this is not essential. The position is changed after induction of pneumoperitoneum. Patient is placed in a reverse Trendelenburg position with the right side up position.
3. **Antiseptic cleaning and draping:** From nipple to midthigh. The sterile surgical field should allow for the possibility of an open procedure if needed.
4. **Establishment of pneumoperitoneum:** Intra-abdominal pressure is preset to 12 mm Hg to 14 mm Hg in automatic insufflator. 1 cm size smiling incision is made below the umbilicus. The pneumoperitoneum is achieved by multiple techniques like closed Veress needle technique, open technique using a blunt trocar, a Hasson's trocar or Palmer's point technique, in which placing the laparoscope at a point in the left midclavicular line, approximately 3 cm caudal to the costal margin in patients with a history of significant adhesions or multiple previous pelvic surgeries. A Veress needle is inserted into the abdomen at right angle taking care not to injure the underlying abdominal organs or big vessel. The position of the needle inside the peritoneal cavity is confirmed by injecting about 5 mL of saline and reaspirating it. If the needle is in the correct place the saline could be pushed easily and on aspiration nothing will come. This can also be confirmed by drop test. A drop of saline is placed at the back of the needle and the abdominal wall is lifted up. The needle is in the correct place, the saline drop will be sucked in. Once the needle is confirmed to be in the peritoneal cavity, it is connected to an automatic carbon dioxide insufflator by the insufflation tube. The carbon dioxide flow

is started at a slow rate (1–2 liter/min). Afterwards the flow rate is increased. Once the abdomen is inflated to a sufficient level the Veress needle is withdrawn.

5. **First trocar insertion:** The first trocar can be inserted by optic port or by open Hasson's technique or inserted blindly with controlled pushing force to avoid injury to the underling viscera or vessels. A 10 mm trocar and cannula are inserted into the abdomen below the umbilicus and the trocar is removed keeping the cannula in place.

6. **Introduction of the telescope attached to a video camera:** The video camera light source attached to 30-degree; 10 mm telescope is inserted into the peritoneal cavity through the infraumbilical trocar.

Photo (1): Laparoscopic cholecystectomy setup **(7)**

7. **Exploration of the peritoneal cavity**: The picture of the abdominal cavity is now displayed in the video screen. The pelvis is inspected first and then attention is drawn towards the GB and extrahepatic biliary tree.
8. **Insertion of 2nd, 3rd and 4th ports**: The next three ports are made under direct vision. The second 10 mm port is made at the epigastrium below the

ISSN: 0975-3583, 0976-2833 VOL 12, ISSUE 07, 2021

xiphoid just to the right of midline so that the trocar goes into the abdomen to the right of the falciform ligament. One 5 mm port is put in the right midclavicular line just below the right costal margin and a second 5 mm port is put in the right anterior axillary line at the level of the umbilicus. One toothed grasper is introduced through the anterior axillary port, and this grasps the fundus of the GB and pushes it up towards the right shoulder. One more grasper is introduced through the midclavicular port to hold the Hartmann's pouch of the GB. Thereby exposing the site of the hepatocystic triangle. Through the epigastric port a Maryland dissector attached to a diathermy is inserted to start dissection.

N.B. LC has traditionally been performed using two 10 mm ports and two 5 mm ports, and the safety and effectiveness of using smaller or fewer ports including single-port or natural orifice surgery for performing LC have been established.

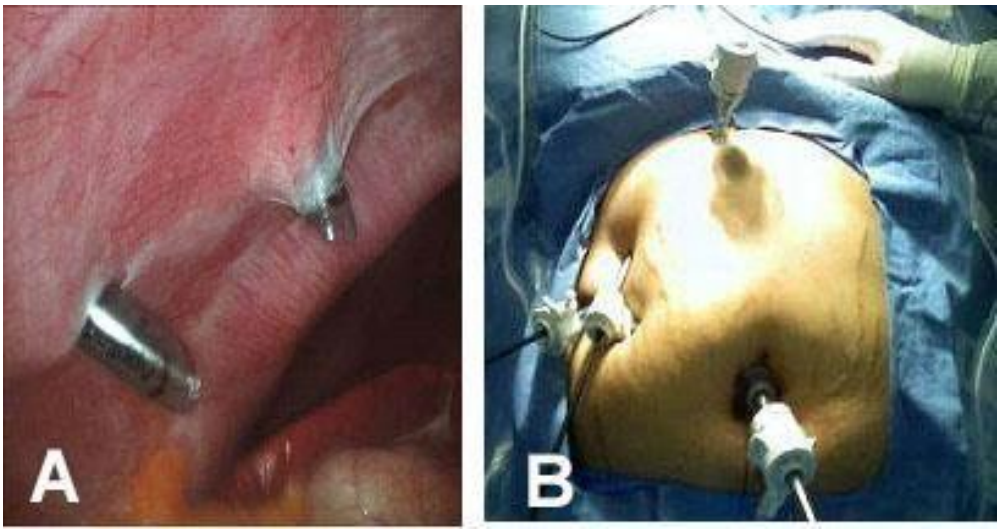

Photos (2 A, B): Placement of the ports **(8)**

9. **Dissection of cystic pedicle and the hepatocystic triangle:** The patient is positioned reverse Trendelenburg's position with the right side up to allow the intestine to fall away from the sub hepatic region. With the Maryland dissector

the anterior leaf and the posterior leaf of the cystic pedicle is teased off and the CD and CA are dissected clearly. Posterior dissection of the hepatocystic triangle is the most important initial step. Anterior dissection of the hepatocystic triangle is done and identification of CD and CA by application of critical view of safety technique is achieved.

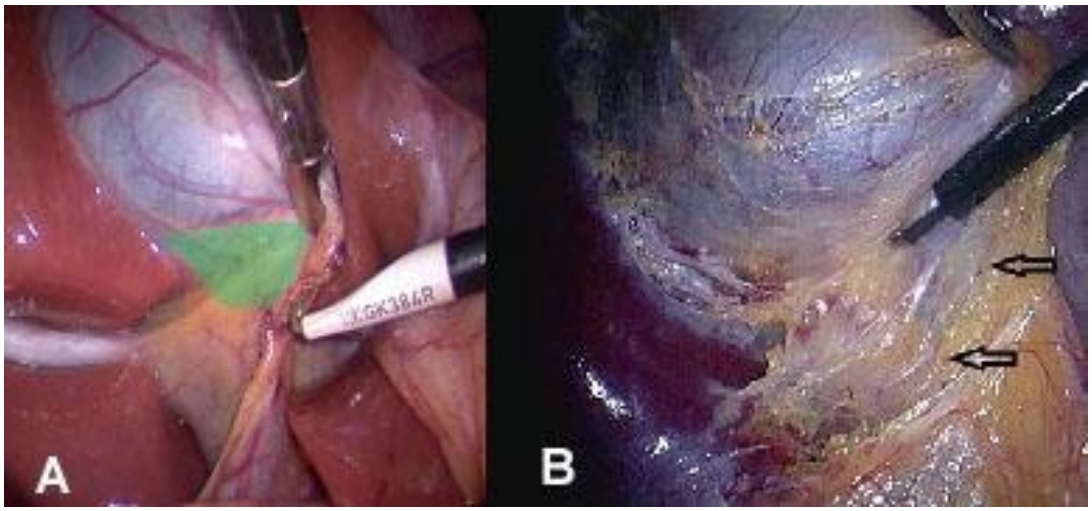

Photos (3 A, B): Posterior dissection of the hepatocystic triangle **(7)**

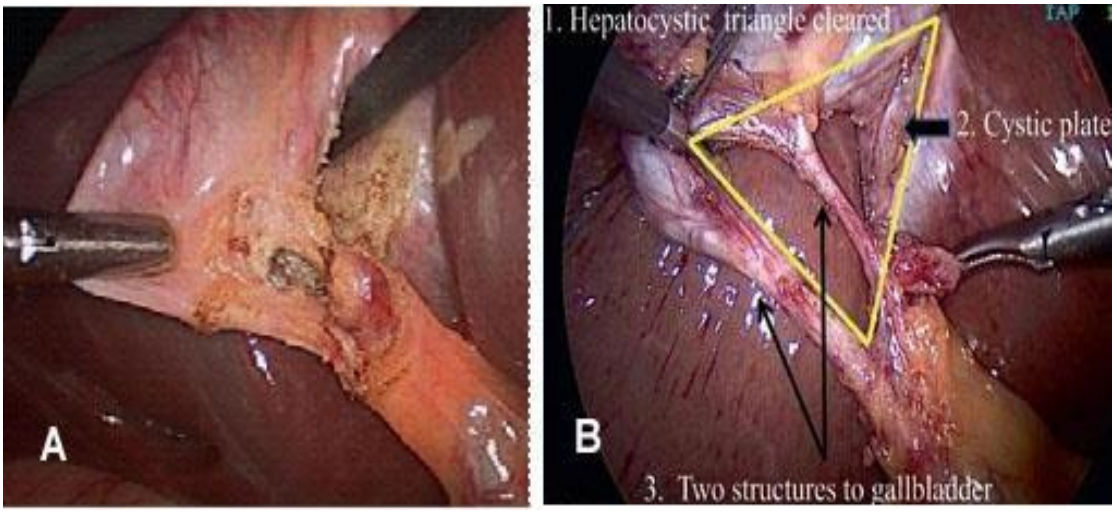

Photos (4 A, B): The hepatocystic triangle and critical view of safety **(9)**

ISSN: 0975-3583, 0976-2833 VOL 12, ISSUE 07, 2021

10. **Application of clips and division of cystic duct and artery:** Once the CD and CA are cleared off, they are clipped with titanium clips applied by a 10 mm. clip applier inserted through the epigastric port. Three clips are applied in the CD and three in the CA and the duct and artery are divided by an endoscissors keeping two clips in the CD and CA towards the bile duct side.

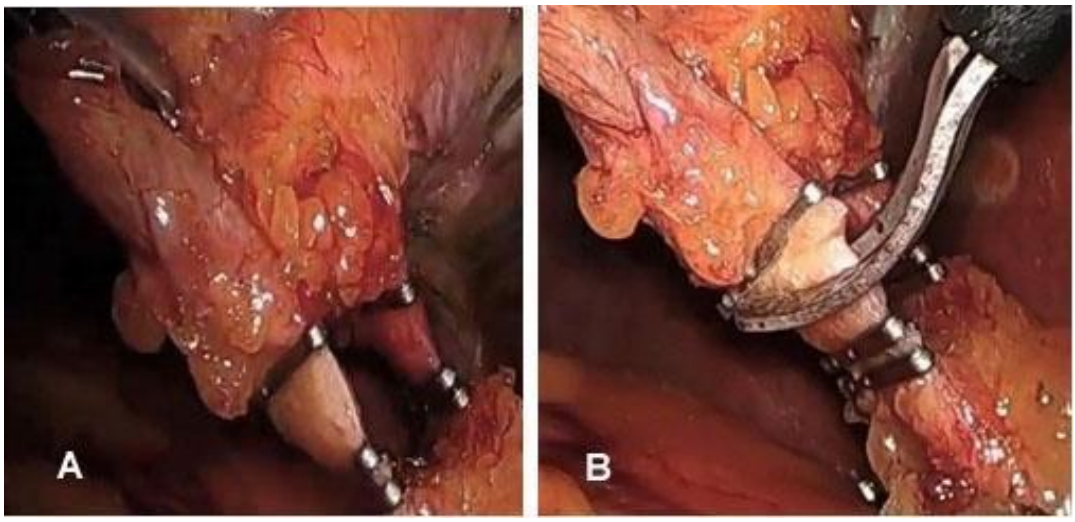

Photos (5): (A) Application of clips, (B) Division of cystic duct and artery **(10)**

11. **Dissection of the gallbladder from GB bed:** Once the CD and the CA are divided the GB is now dissected by using a monopolar diathermy hook from the GB bed.

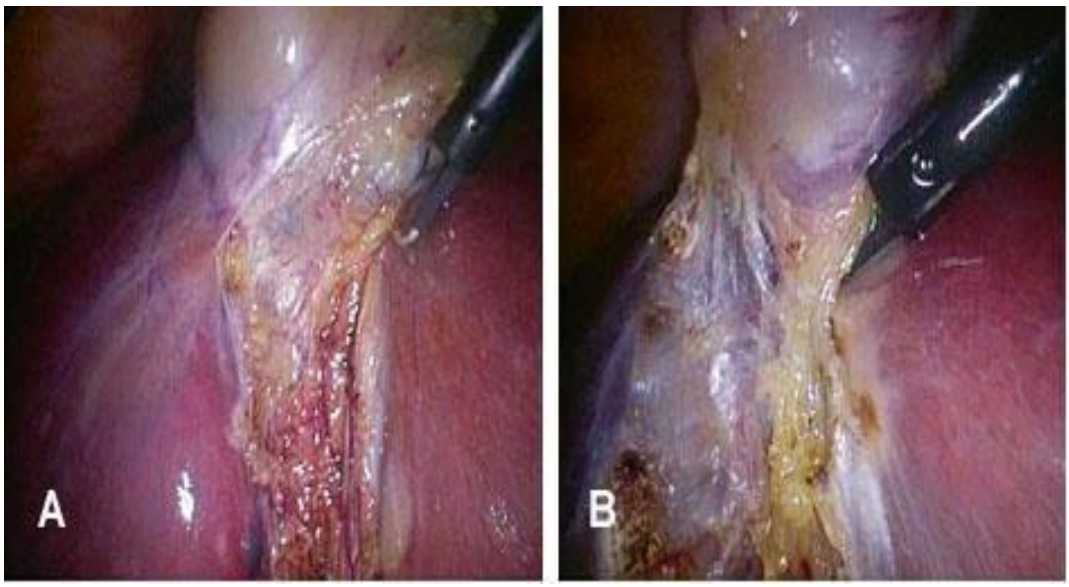

Photos (6 A, B): The dissection of GB from its bed **(10)**

12. **Irrigation and suction:** Once the GB are free, the GB bed is irrigated with normal saline and checks for any bleeding which may be controlled by diathermy coagulation.
13. **Extraction of the gallbladder:** The separated GB is extracted from the abdomen in a retrieval bag through the epigastric or the umbilical port

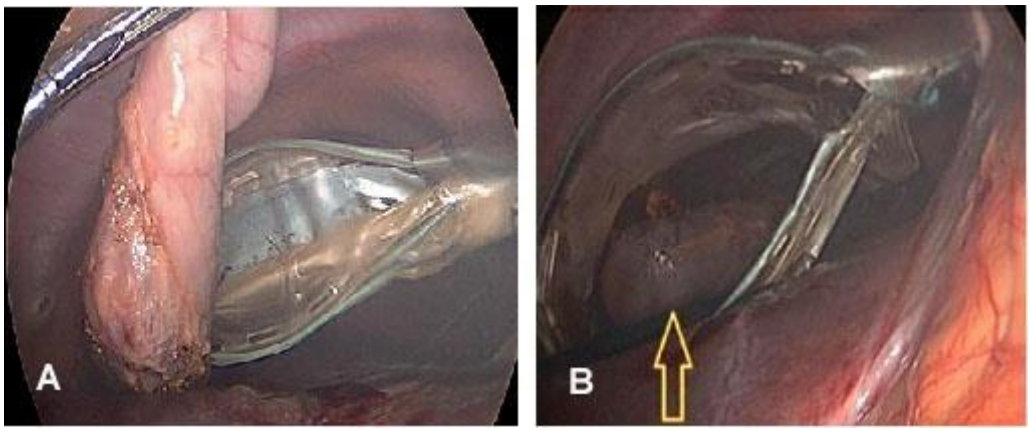

Photos (7 A, B): Placement of the GB in a retrieval bag **(10)**

14. **Placement of a drain:** Placement of a drain is optional. If there is considerable oozing or if the surgery is difficult then a tube drain should be placed in the hepatorenal pouch of Morrison for 24–48 hours.
15. **Closure of the port sites:** The cannulas are withdrawn, and the incisions are closed. The sheath in the 10 mm port areas is closed with sutures.

V- Complications:

A- Intraoperative complications

1- **Bleeding from vascular damage or from trocar sites:** Seeping in LC can be experienced intra-operatively or in the postoperative period. Intra- operative bleeding can be caused by one of the following four examples: vessel damage, slippage of clips/ ligatures of the cystic artery, liver bed oozing and various causes as the introducing of the pneumoperitoneum needle and the main trocar which are considered by many to be the most hazardous stride in LC, as it is basically a “visually impaired” stride of the operation **(11).**

ISSN: 0975-3583, 0976-2833 VOL 12, ISSUE 07, 2021

2- **Bile duct injury (BDI):** The rates of BDI, the most genuine difficulties related with LC, have been accounted for to go from 0.2% to 7% for LC contrasted by 0.2- 0.4% for OC **(11).**

3- **Gallbladder perforation:** Although LC has overall less complication rate than the traditional open approach, there appear to be at least two operative complications that occur with greater frequency during LC. One is the BDI and other is the GB perforation. GB gets perforated while it is being dissected from the liver bed or while being extracted through the port. During LC, because of perforation of the GB; rate of bile leaks and loss of gallstones into the peritoneum has been reported to be between 3% and 33% **(11).**

4- **Spilled gallstones:** Many times, the procedure may be complicated with rupture of the GB and spillage of gallstones and sludge into the peritoneal cavity occurs **(12).**

5- **Bile leaks:** Bile leaks may occur due to BDI whether major or accessory ducts that may be passing directly from liver to gallbladder through its bed **(13).**

6- **Conversion to open procedure:** Conversion to OC may be resorted to for various reasons with reported rates of 1% to 15%. Conversion increases the operative time, complication rates, perioperative costs and the length of hospital stay. Intraoperative difficulties that induce conversion include uncontrolled bleeding, difficult hepatocystic triangle dissection, CBDS with deficient skills and equipment for laparoscopic CBD exploration and BDI. Open conversion should not be regarded as a failure in LC. It is occasionally the safest option for the patient when encountering a difficult GB. Nevertheless, conversion still carries a high complication rate, and it is good practice to consult a more experienced surgeon where available before resorting to conversion **(14).**

B- Postoperative complications:

1- **Early complications:** These include complications related to anesthesia; complications related to peritoneal access (e.g., vascular injuries, visceral

injuries); complications related to pneumo-peritoneum (e.g., postoperative pain, cardiac complication, pulmonary complications and air embolism); and complications related to thermocoagulation. Specific complications of LC are hemorrhage, bile leakage, BDI, and others such as hematoma, foreign body inclusions **(15)**.

2- **Postoperative ileus:** Traditionally patients pass flatus on operative day zero night or on the 1st POD but sometimes postoperative ileus rarely occurrs after LC **(16).**

3- **Infectious complications:** LC is associated with a low risk of port site infection which in most cases is only superficial and responds to local measures. Infection is most commonly seen at port sites through which GB was extracted **(17).**

4-

Other postoperative complications are respiratory tract infection, prolonged ileus, hyperpyrexia, subphrenic collection, dyspepsia and persistence of symptoms. Specific complications of LC are hemorrhage, bile leakage, BDI, and subhepatic collection and others such as external biliary fistula, wound sepsis, hematoma, foreign body inclusions and rarely postoperative adhesions **(15).**

5- **Late postoperative stricture of bile ducts:** It may occur due to excessive power use during dissection at the hepatocystic triangle or due to in harried control of bleeding during the procedure **(18).**

References.

1. **Everhart J and Ruhl C (2009):** Burden of digestive diseases in the United States Part III: liver, biliary tract and pancreas. Gastroenterology; 136: 1134–1144.

2. **Lammert F, Gurusamy K, Ko C et al. (2016):** Gallstones. Nature reviews Disease primers; 2 (1): 1-17.

3. **Lamberts MP, Den Oudsten BL, Gerritsen JJ, Roukema JA, Westert GP, Drenth JP and van Laarhoven CJ (2015):** Prospective multicentre cohort study of patient-reported outcomes after cholecystectomy for uncomplicated symptomatic cholecysto- lithiasis. Br J Surg, 102(11), 1402-9.

4. **Casamassima, M. G. S., Gause, C., Yang, J., Goldstein, S. D.,Swarup, A., & Abdullah, F. (2016):** Safety of outpatient laparoscopic cholecystectomy in children: analysis of 2050 elective ACS NSQIP-pediatric cases. Pediatric surgery international, 32(6), 541-551.

5. **Kartal K and Uludag M (2016):** Can 4-port laparoscopic cholecystectomy remain the gold standard for gallbladder surgery. Ann Ital Chir, 87, 13-7.

6. **Saha ML (2014):** Operative Surgery. In Bedside clinics in surgery; Section 9, JP Medical Ltd. Pp. 981-983.

7. **Gupta V and Jain G (2019):** Safe laparoscopic cholecystectomy: Adoption of universal culture of safety in cholecystectomy. World journal of gastrointestinal surgery; 11(2): 62 -69.

8. **Sazhin VP, Sazhin IV, Pod''iablonskaia IA, Karlov DI, Nuzhdikhin AV and Aĭvazian SA (2016):** Etiology of "difficult" laparoscopic cholecystectomy. Khirurgiia, (1), 61-66.

9. **Deziel DJ and Veenstra BR (2020):** Biliary Anatomy. In The SAGES Manual of Biliary Surgery (pp. 5-23). Springer, Chamz.

10. **Cox MR (2018):** Laparoscopic Cholecystectomy: Operative Technique. In The Management of Gallstone Disease (pp. 221-248). Springer, Cham.

11. **JAMAL, A. (2017):** Early and Delayed Laparoscopic Cholecystectomy for Acute Cholecystitis: A Review Article. Open Access J. Surg, 5(5), 55567.

12. **Lee YN, Moon JH, Choi HJ, Kim DC, Chung JH, Lee TH and Kim SJ (2013):** Direct biliary drainage using transnasal endoscopy for patients with severe-to-moderate acute cholangitis. Journal of gastroenterology and hepatology, 28(4), 739-743.

13. **Felekouras E, Petrou A, Neofytou K, Moris D, Dimitrokallis N, BramisK and Diamantis T (2015):** Early or delayed intervention for bile duct injuries following laparoscopic cholecystectomy? A dilemma looking for an answer. Gastroenterology research and practice, 2015.

14. **Nassar AH, El Zanati H, Ng HJ, Khan KS and Wood C (2021):** Open conversion in laparoscopic cholecystectomy and bile duct exploration: subspecialisation safely reduces the conversion rates. Surgical Endoscopy, 1-9.

15. **Rodríguez-Sanjuán JC, Arruabarrena A, Sánchez-Moreno L, González- Sánchez F, Herrera LA and Gómez-Fleitas M (2012):** Acute cholecystitis in high surgical risk patients: percutaneous cholecystostomy or emergency cholecystectomy?. The American journal of surgery, 204(1), 54-59.

16. **Wu XD, Tian X, Liu MM, Wu L, Zhao S and Zhao L (2015):** Meta- analysis comparing early versus delayed laparoscopic cholecystectomy for acute cholecystitis. Journal of British Surgery, 102(11), 1302-1313.

17. **Alam MR, Nuruzzaman M, Begum M, Alim MA, Rahman MM, Karim MR and Alam MI (2021):** The frequency of port-site infection in laparoscopic cholecystectomies. Medicine Today, 33(1), 22- 26.

18. **Navez B and Navez J (2014):** Laparoscopy in the acute abdomen. Best Practice and Research Clinical Gastroenterology, 28(1), 3-17.