Journal of Cardiovascular Disease Research
ISSN: 0975-3583, 0976-2833 VOL 12, ISSUE 07, 2021

Clinical and Radiological Diagnosis of Metacarpal Fractures

Omar Abdelwahab Kelani [1], Tarek Abd ELSamad EL-Hewala[1] , Mohammed Adel Abdelrazek[1], and Haron Omran Mosbah[2] ,

[1]Orthopedic Surgery Department, Faculty of Medicine, Zagazig University, Egypt.
[2]Orthopedic Surgery Department, Faculty of Medicine, Gharyan University - Libya.
Corresponding author: Haron O. Mosbah Email: dr.haroon1982hom@gmail.com

Abstract

Background: Fractures of metacarpals and phalanges are the most common among upper limb bony injuries and contribute to about 10% of total fractures among them. It is well recognized that both soft tissue healing with fracture healing must be kept in mind during treatment of hand and metacarpal fractures because successful outcomes require the return of functional integrity to both the tissues. **Objective**: To evaluate the functional and radiological outcome of metacarpal fractures. **Conclusion**: High-resolution Radiological may be used to Evaluating the functional and radiological outcome of metacarpal fractures.

Keywords: Metacarpal Fractures, Clinical examination, radiological

Introduction

Fractures of metacarpals and phalanges are the most common among upper limb bony injuries and contribute to about 10% of total fractures among them**.** It is well recognized that both soft tissue healing with fracture healing must be kept in mind during treatment of hand and metacarpal fractures because successful outcomes require the return of functional integrity to both the tissues**(1).**

Diagnosis of hand fractures

Clinical

A well-taken history is important in order to tailor the management to the specific needs of the patient. Age, occupation, hand dominance, recreational activities, medical co-morbidity and mechanism of injury are important in history taking **(2)**.

Symptoms include pain, swelling, weakness, stiffness, deformity, numbness and altered sensation. Patients should be questioned about the initial deformity and reduction maneuvers that may have been attempted. Tenderness, swelling, bruising, crepitus, deformity, restricted motion and instability are common signs of injury **(2).**

Clinical examination can be carried out following the use of local anaesthetic with documentation of the neurological status of the digit/s prior to its administration. Such blockade also allows tendon and ligament integrity to be assessed without pain and facilitates irrigation of wounds **(2).**

Differential diagnosis includes dislocation, collateral ligament rupture and tendon laceration or avulsion **(2)**.

Radiological

For all cases, a minimum of two X-ray views of the hand and wrist are required for initial and basic skeletal survey (Fig-1). These are a postero anterior (PA) view and an oblique view with the fingers fanned out for minimal overlapping. A lateral view of the hand has so much overlapping that it is of limited usefulness except for initial diagnostic screening of the wrist but true lateral views of individual fingers are essential for their evaluations [(3)].

Figure (1) Standard survey views of the hand and wrist must include the following: (A). Posteroanterior view (PA). (B). A 45-degree oblique view with which the fingers can be fanned out to minimize their overlapping, (C). True lateral views [(3)].

The hand can be pronated or supinated, as shown in (Fig-2), depending on which finger or joint is being evaluated [(4)].

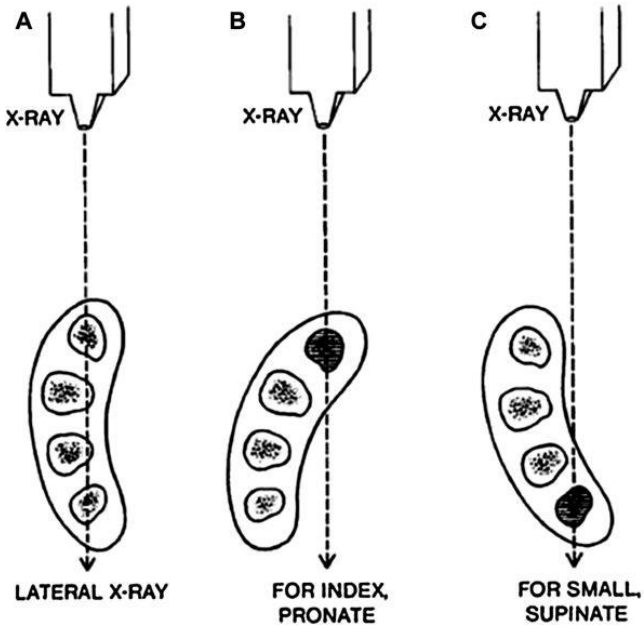

Figure (2) Axial relationships of metacarpals, showing that a lateral radiograph of the hand (A)requires slight pronation (B) and slight supination (C) for independent visualization of index and small metacarpals [(4)].

Brewerton described a tangential radiographic projection of the hand for demonstrating erosive arthritic changes in the metacarpal heads in 1967. This technique has been found useful in identifying erosive changes early in rheumatoid arthritis and been recently extended its use to the evaluation of changes due to trauma [5].

The radiographs are made with the fingers flat on the x-ray plate, the MCP joints flexed 65°(Fig-3), and the beam angled from a point 15° to the ulnar side of the hand [6].

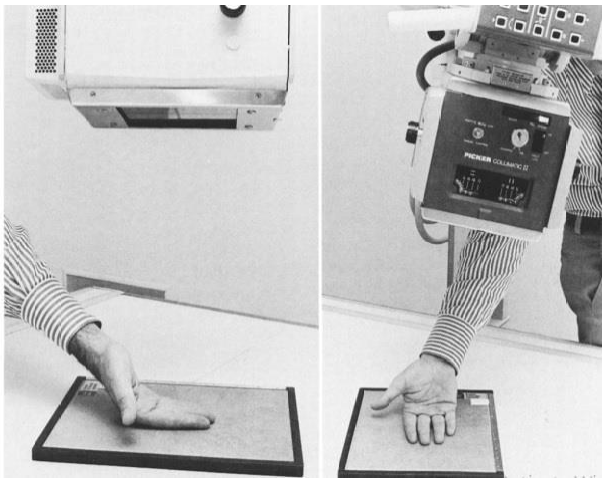

Fig-3: Brewerton view [6]

Robert suggests positioning the dorsal side of the hand flat on the plate, providing a more reproducible image (Fig 4-5), since the bulk of the palm precludes the joint lying flat. Forced pronation, he posits, is ‘‘easier to achieve and more comfortable for the patient and is more likely to position the joint exactly in the plane of the radiographic plate’’ centering the beam on the joint [7].

Figure (4) Modified Robert’s view of an asymptomatic thumb demonstrating the horizontal profile of both the trapeziometacarpal and scaphotrapezial joints [8].



Figure (5) Radiograph beam aimed 15 proximal [7]

High-resolution Computed tomography (CT) scan is more helpful method than plain X-ray in detecting carpal bones fractures. CT scans may be used to plan the approach to and fixation of complex intra-articular injuries, or to assess the skeleton where plain films are hard to interpret due to overlapping bony shadows (such as assessing the carpo-metacarpal joints).[3]

Table (1): Joints of the hand. [9]

Joint	Structure	Axis	Motion	Close-packed position
Metacarpo-phalangeal (MP)	biaxial (condylar)	lateral A-P	flexion/extension abduction/adduction	first: extension 2nd-5th: flexion
Proximal Interphalangeal (PIP)	uniaxial	lateral	flexion/extension	extension
Distal Interphalangeal (DIP)	uniaxial	lateral	flexion/extension	extension

Table (2): Range of motion in finger joint : [10]

Finger	Flexion	Extension	Abduction/adduction
Thumb			
Trapeziometacarpal	50° - 90°	15°	45° - 60°
Metacarpophalangeal(MCM)	75° - 80°	0°	0°
Interphalangeal (IP)	75° - 80°	5° - 10°	0°
Index			
Carpometacarpal (CMC)	5°	0°	0°
MCP	90°	30° - 40°	60°
Proximal interphalangeal (PIP)	110°	0°	0°
Distal interphalangeal (DIP)	80° - 90°	5°	0°

Middle			
CMC	5°	0°	0°
MCP	90°	30° - 40°	45°
PIP	110°	0°	0°
DIP	80° - 90°	5°	0°
Ring			
CMC	10°	0°	0°
MCP	90°	30° - 40°	45°
PIP	120°	0°	0°
DIP	80° - 90°	5°	0°
Little			
CMC	15°	0°	0°
MCP	90°	30° - 40°	50°
PIP	135°	0°	0°
DIP	90°	5°	0°

Table (3): Range of motion in the wrist :[10]

Wrist	Value
Flexion	65° - 70°
Extension	70° - 80°
Radial flexion (deviation)	15° - 25°
Ulnar flexion (deviation)	40° - 45°

Indications for nonoperative treatment:

Undisplaced, or minimally displaced, fractures of the metacarpal shaft can be treated nonoperatively. Most of these fractures produce a flexion deformity and often minimal shortening. If the flexion deformity exceeds 10-20 degrees in fractures of the second and third metacarpals, or 20-30 degrees in fractures of the fourth and fifth metacarpals, surgical treatment is recommended. Shortening of less than 2 mm does not interfere with function, but more than 5mm cannot be accepted.[11]

Immobilization with palmar splint:

A splint may be applied with the hand in an intrinsic plus (Edinburgh) position and the wrist in slight extension of 20-30 degrees. Extension of PIP joint and DIP joint only the fractured finger ray and the two adjacent rays are included in the splint, in fractures of the third, or fourth, metacarpal. In fractures of the second metacarpal, it may be sufficient to include only the second and third rays. In fractures of the fifth metacarpal, the fifth and fourth rays are included. The splint is held in place with an elastic bandage. The bandage should not be over tightened at the level of the wrist joint, so as to avoid excessive swelling of the hand. Direct

skin contact of adjacent fingers should be pre- vented by placing gauze pads between them. This splint is easy to apply and needs no hand therapy during the period of immobilization. A potential disadvantage of this technique is the complete immobilization of uninjured fingers and joints**.** [11]

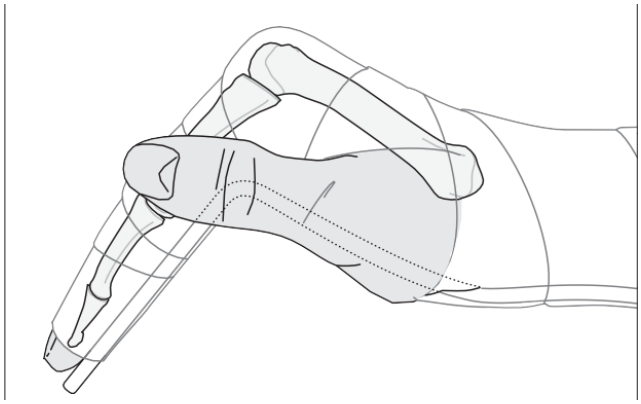

Fig. (6): Immobilization with palmar splint**.** [11]

Surgical management of metacarpal fractures:

Indications for surgery include;

- Open fractures
- Intraarticular fractures
- Angulation of the fracture greater than 30 degrees
- Rotational deformity greater than 10 degrees and gross (>5mm) shortening of the metacarpal.

Closed reduction and internal fixation (CRIF):

Multiple options exist for operative fixation of metacarpal fractures. Percutaneous Kirschner wires remain an important technique to control and stabilize fracture fragments. Several pinning techniques can be used for metacarpal or phalangeal fractures**.** [12]

The easiest technique is transfixion pinning of the fractured metacarpal to an intact adjacent metacarpal. A second pinning technique uses K-wires to cross near the fracture site. These can be placed antegrade or retrograde. In antegrade method a K-wires is intramedullary inserted in the metacarpal bone passing the fracture under fluoroscopy. The divergent tips of the wires in the metacarpal head resemble the stems of flowers, and thus the term "bouquet" osteosynthesis. In retrograde method a K-wire is inserted through the metacarpal head in the retrograde direction. [13] **(Fig. 7)**

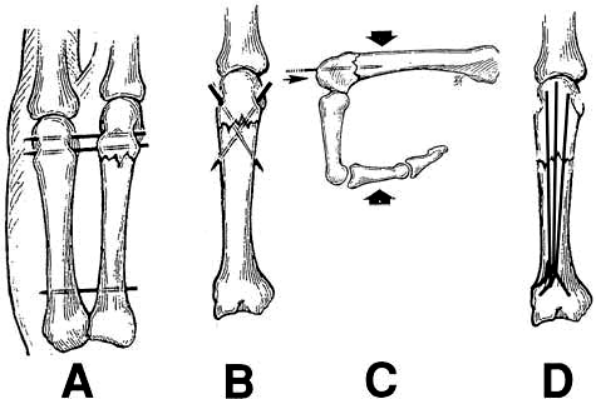

Fig. (7): Various pinning fixation techniques described for the management of metacarpal fractures. (A) Transfixion pinning. (B) Cross k-wires. (C) Retrograde intramedullary fixation. (D)Antegrade intramedullary fixation **.**[13]

Headless compression screw fixation for metacarpal neck and shaft fractures has been shown to be a reliable option for axially stable fractures. The advantages of headless compression screws are relatively fast insertion and the minimally invasive insertion technique, decreasing risks associated with more extensive soft tissue dissection, stability allowing early range of motion and that it is an intramedullary implant, which eliminates the risk of hardware irritation **(**Fig. 8). [14]

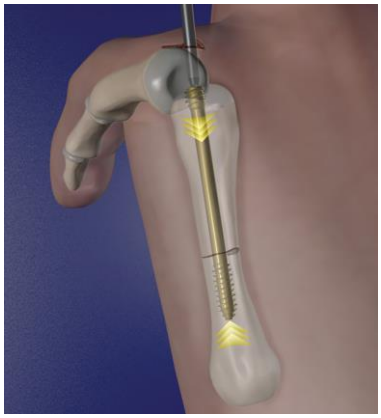

Fig. (8): Intramedullary screw fixation of a transverse metacarpal fracture**.** [14]

Open reduction and internal fixation (ORIF):

Mini plate and screws provides a rigid fixation. These implants neutralize rotational, torsional and shearing forces at the fracture area, thus enabling earlier and stronger rehabilitation. A rigid fixation enabling bone healing and early active finger motion is important in surgical treatment.

Case Presentation:

35 years old male, patient presented with fracture 2nd metacarpal. AO classification: 77.2.2C. History of fight in his left hand with. The patient was treated by open reduction and internal fixation by mini-fragment plates and screws. (Fig. 9, 10,11,12)

Time to union: 6 weeks , Total active motion: 255 , Quick DASH: 11 , No complications

Fig. (9): Preoperative x-rays showing fracture of 2nd metacarpal

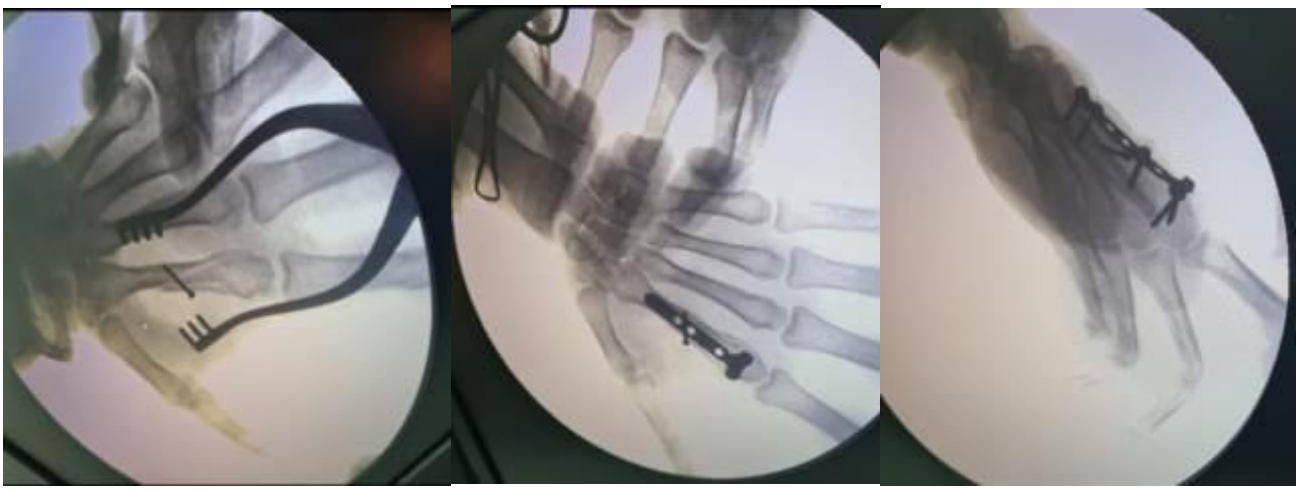

Fig. (10): Intra-operative x-rays showing fracture 2nd metacarpal.

Fig. (11): 2 weeks postoperative x-rays showing fracture of second metacarpal

Fig. (12): 3months postoperative x-rays showing fracture of second metacarpal.with complete union.

Complications of Metacarpal Fractures

Complications can arise with both conservative and surgical treatment of hand fractures. Closed treatment of fractures with immobilization can lead to malunion and stiffness. Surgical treatment of unstable fractures adds the potential for hardware-related adhesions, tendon rupture and infection **(15).**

CONCLUSION

High-resolution Radiological may be used to Evaluating the functional and radiological outcome of metacarpal fractures.

References

1- Meals, C., & Meals, R. (2013). Hand fractures: a review of current treatment strategies. *The Journal of hand surgery*, *38*(5), 1021-1031.

2- Haughton DN, Jordan D, Malahias M, Hindocha S & Khan W. Suppl 1: principles of hand fracture management. The open orthopaedics journal, 2012; 6, 43

3- Beasley, R.W., 2003. Beasley's Surgery of the Hand. Thieme Medical.

4-Cotterell, I.H. and Richard, M.J., 2015. Metacarpal and phalangeal fractures in athletes. Clinics in sports medicine, 34(1), pp.69-98.

5-Brewerton, D. A. (1967). A tangential radiographic projection for demonstrating involvement of metacarpal heads in rheumatoid arthritis. The British Journal of Radiology, 40(471), 233-234.

6-Lane, C.S., 1977. Detecting occult fractures of the metacarpal head: the Brewerton view. Journal of Hand Surgery, 2(2), pp.131-133.

7-Ladd, A.L., 2014. Guest editorial: The Robert's view: a historical and clinical perspective. Clinical orthopaedics and related research, 472(4), p.1097.

8-Gervis, W.H., 1949. Excision of the trapezium for osteoarthritis of the trapezio-metacarpal joint. The Journal of bone and joint surgery. British volume, 31(4), pp.537-539.

9- Gibson PD, Sobol GL & Ahmed IH. Zone II flexor tendon repairs in the United States: trends in current management. The Journal of hand surgery, 2017; 42(2), e99-e108.

10- Jaworski Ł & Karpiński R. Biomechanics of the human hand. Journal of Technology and Exploitation in Mechanical Engineering, 2017; 3(1), 28-33.

11- Kollitz KM, Hammert WC, Vedder NB & Huang JI. Metacarpal fractures: treatment and complications. Hand, 2014; 9(1), 16-23

13- Lee SK, Kim KJ, Choy WS. Modified retrograde percutaneous intramedullary multiple Kirschner wire fixation for treatment of unstable displaced metacarpal neck and shaft fractures. Eur J Orthop Surg Traumatol. 2013; 23(5):535-543

14- Guidi M, Frueh FS, Besmens I & Calcagni M. Intramedullary compression screw fixation of metacarpal and phalangeal fractures. EFORT Open Reviews, 2020; 5(10), 624-629.

15- Gollamudi, S. and Jones, W.A., 2000. Corrective osteotomy of malunited fractures of phalanges and metacarpals. Journal of Hand Surgery, 25(5), pp.439-441