

COMPARISON OF DIFFERENT METHODS OF HEMOSTASIS AFTER CHOLECYSTECTOMY

¹Rakhimov O.U., ²Muhammadsolikh Sh.B., ¹Turgunov Sh.Sh.

¹Tashkent Pediatric Medical Institute, ²Tashkent Medical Academy

Abstract:

Background and aim: The problem of hemostasis in cholecystectomy is sometimes relevant to the present day. The main methods of hemostasis during this operation are: electrocoagulation, stitching of the gallbladder bed, application of a hemostatic sponge, etc. The aim of the present study is to conduct a comparative analysis of the use of various methods of hemostasis after cholecystectomy.

Material and methods: The paper presents the results of a study of 200 patients with acute and chronic cholecystitis. Depending on the method of hemostasis, they were divided into 3 groups.

Results: When analyzing the postoperative period of patients in clinical observation groups, significant differences were revealed in some parameters. The duration of hemostasis in the main group with bleeding from the bladder bed after laparoscopic cholecystectomy (LC) and open cholecystectomy (OC) was 2 times different from the time in the control group. As a result of repeated coagulation of the gallbladder bed, an additional zone of coagulation necrosis was formed, which in the postoperative period was a source of hyperthermia and a substrate for the pyoinflammatory process.

Conclusion: Hemostatic sponge, is a fairly effective local hemostatic agent. The use of hemostatic sponge allows avoiding the specific dangers and complications of electrosurgical methods for stopping bleeding from the gallbladder bed, reducing postoperative complications by 1,5 times.

Keywords: hemostasis, open cholecystectomy, laparoscopic cholecystectomy, bleeding

Introduction:

The problem of reliable hemostasis is one of the main conditions for a successful outcome of surgery. At present time, there are various methods of hemorrhage control from the gallbladder bed (mechanical, biological, physical, chemical). Despite the variety of techniques and methods [9, 10], the issue of hemostasis in cases of hemorrhage from the gallbladder bed still remains relevant, requiring new, innovative solutions, especially during laparoscopic cholecystectomy (LC) [12]. The search for new methods, the development of modern means of hemostasis with high efficiency and application simplicity is an urgent problem of surgery.

A common physical method of hemostasis is electrocoagulation, which has worked well for minor bleeding. The main advantages of the technique are ease of use and accessibility to most surgeons [7]. However, studies have shown that after electrocoagulation, a zone of coagulation necrosis is formed, the size of which is very difficult to control, which subsequently serves as a

substrate for the development of infectious complications, secondary bleeding, biliary and urinary fistulas [2, 3, 4, 7, 11].

An incorrectly or insufficiently treated gallbladder bed can become a source of bleeding and bile leakage both during surgery and in the postoperative period [8].

A wide range of techniques and methods available in the arsenal of modern surgery does not solve the problem of hemostasis in case of bleeding (and probably concomitant bile leakage) from the gallbladder bed - there is a need to refine long-studied methods, as well as to search for new solutions aimed at eliminating the indicated problem [1, 5, 6].

Currently available hemostatic agents are effective in stopping bleeding but are otherwise ineffective in more severe bleeding. The development of safe and effective hemostatic drugs is important to reduce the time required to achieve hemostasis, the intensity of bleeding, and the incidence of associated complications with blood loss. An ideal hemostatic agent will reduce the use of blood products in elective and emergency surgery, and also has the ability to stop parenchymal, arterial and venous bleeding.

Aims and objectives:

The aim of the present study is to conduct a comparative analysis of the use of various methods of hemostasis after cholecystectomy.

Material and methods:

The paper presents the results of a study of 200 patients with acute and chronic cholecystitis. Depending on the method of hemostasis, they were divided into 3 groups. The first (main) group - 80 patients after cholecystectomy on the gallbladder bed for the purpose of hemostasis applied 1 g of hemostatic sponge in the form of a fine powder, the second (control) group - 101 patients after cholecystectomy, hemostasis was carried out by electrocoagulation of the gallbladder bed with a monopolar electrode, i.e. high-frequency electricity was used, the third group (comparison) - 19 patients after cholecystectomy on the gallbladder bed for the purpose of hemostasis used a hemostatic sponge «SPONGOSTANTM STANDART» Distributed by ETHICONTM USA (Ferrosan Medical Devices, Soeborg, Denmark).

Inclusion criteria:

- patient's age more than 18 years with either gender;
- the presence of acute cholecystitis or chronic cholecystitis;
- the use of a new hemostatic sponge “Gemogubka”, a hemostatic sponge "SPONGOSTANTMSTANDART" Distributed by ETHICONTMUSA (Ferrosan Medical Devices, Soeborg, Denmark) and the use of electrocoagulation of the gallbladder bed;
- informed consent of the patient to participate in this study.

Exclusion criteria:

- patient's age below 18 years;
- open surgical interventions on the organs of the upper floor of the abdominal cavity in history;
- severe concomitant diseases in the stage of decompensation; concomitant diseases and neuropsychiatric disorders;
- refusal of the patient to participate in the study.

When distributed by gender, 157 patients were women (78,5%), 43 (21,5%) were men. The average age of patients in the main group was $50\pm 13,7$ years, in the control group $55,9\pm 14,2$ years, in the comparison group $45\pm 15,2$ years, of which 77,2% were of working age (under 60 years).

Statistical Analysis

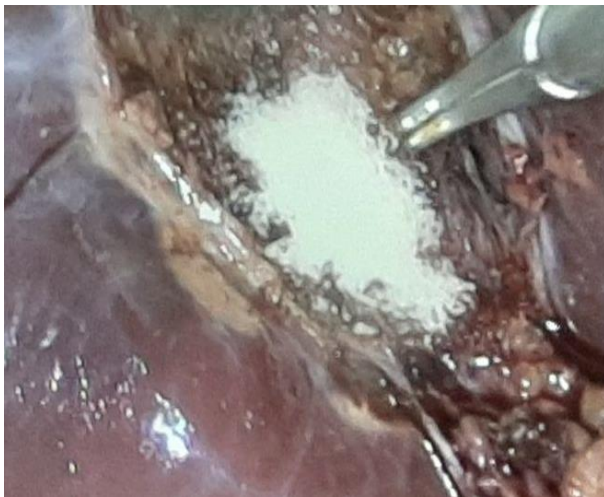The analysis of the data was made on the personal computer using the Statistical Package for Social Sciences (SPSS 23.0) software. Descriptive statistics were used in the study. The mean and standard deviation were calculated for quantitative variables. Frequencies and corresponding percentages are given for qualitative variables. Values below 0,05 were considered statistically significant.

Results:

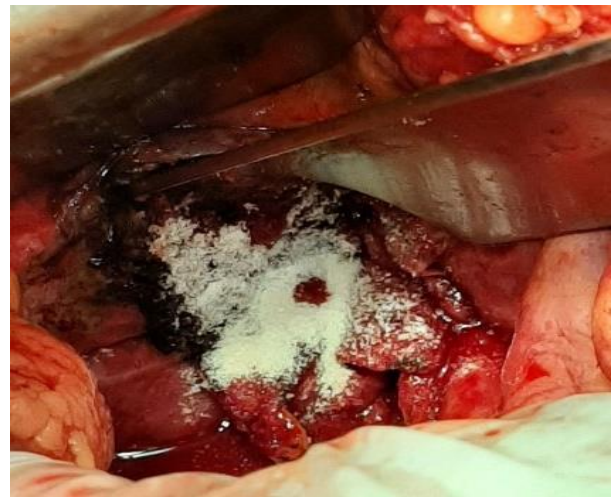The first group included 37 patients who underwent LC and 43 patients after open cholecystectomy (OC), for the purpose of hemostasis in the gallbladder bed, a new hemostatic sponge "Gemogubka" was used (Fig. 1).

In the control group, 56 patients after LC and 45 patients after OC, in which final hemostasis in the area of the gallbladder bed was achieved using monopolar coagulation (Fig. 2). In the control group, tissue dissection and coagulation during laparoscopic cholecystectomy was performed using electrocoagulation according to the standard method.

The comparison group included 14 patients after LC, and 5 patients after OC, in whom hemostatic sponge "SPONGOSTAN™ STANDART" was used for the purpose of hemostasis (Fig. 3).

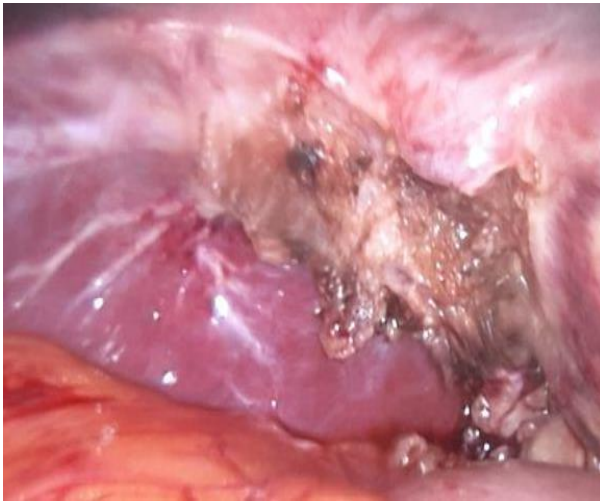


A

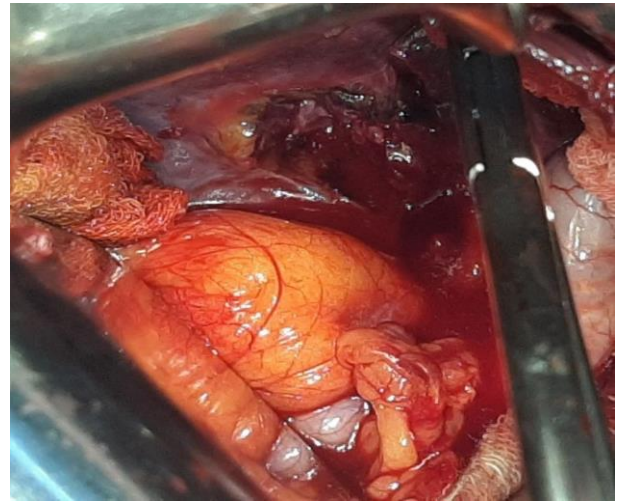

B

Fig. 1. Application of the hemostatic sponge. Application of the hemostatic sponge "Gemogubka" preparation on the surface of the gallbladder bed after LC (A) and OC (B)

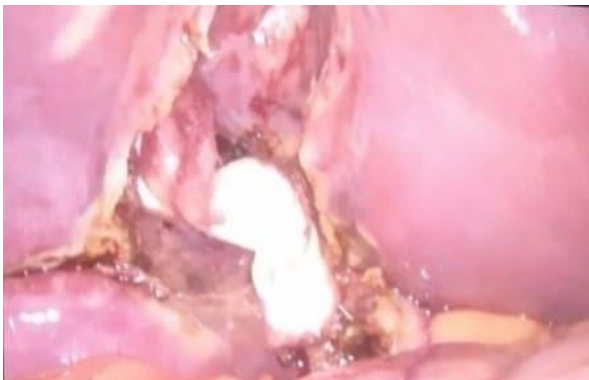

A

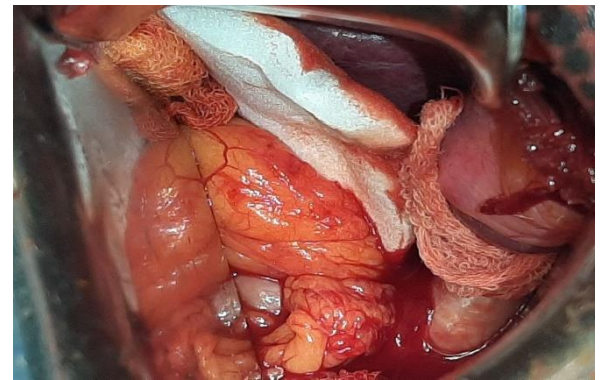


B

Fig. 2. The use of electrocoagulation. Hemostasis after electrocoagulation, zones of thermal burns are visualized after LC (A), bleeding from the gallbladder bed after OC (B)



A



B

Fig. 3. The use of the drug "SPONGOSTAN™ STANDART". Application of the drug on the surface of the gallbladder bed in case of LC (A), in case of OC (B)

When analyzing the postoperative period of patients in clinical observation groups, significant differences were revealed in some parameters.

Biochemical blood parameters of ALT and AST are shown in Fig.4.

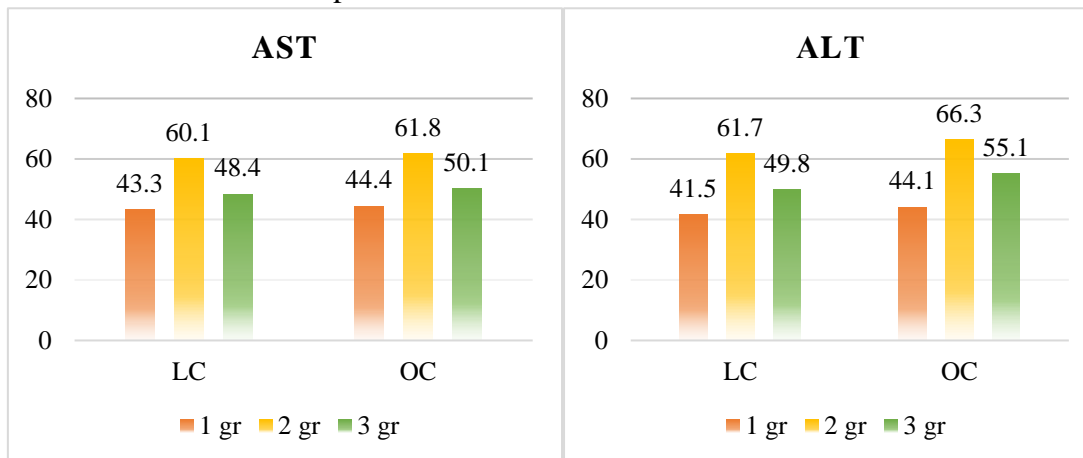


Figure 4. Comparative indicators of AST and ALT in patients after LC and OC

It should be noted that in all groups, ALT activity indicators were significantly ($p < 0,05$) higher than AST.

As a criterion for the viability of hemostasis, we evaluated the time from the moment of application of a hemostatic sponge or plate to the complete cessation of blood leakage from under the edges of the applied preparation. The duration of hemostasis in the observation groups is shown in Fig.5.

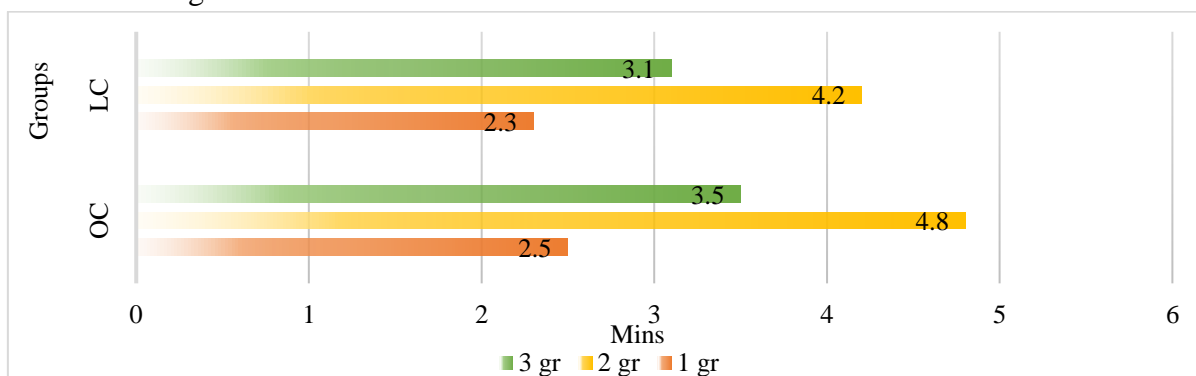


Figure 5. Duration of hemostasis in the observation groups

As can be seen from fig. 5, in the main group, the average duration of hemostasis for bleeding from the bladder bed after LC was $2,3 \pm 0,47$ mins, which was almost two times different from the control time - $4,2 \pm 0,47$ mins. ($p < 0,05$), and in the comparison group $3,1 \pm 0,54$ mins. After OC in the main group, the duration of hemostasis in bleeding from the bladder bed was $2,5 \pm 0,79$ mins, which also differed twice from the time in the control group $4,8 \pm 0,85$ mins ($p < 0,05$), and in the comparison group - $3,5 \pm 0,85$ mins.

The volume of intraoperative blood loss is shown in Fig.6.

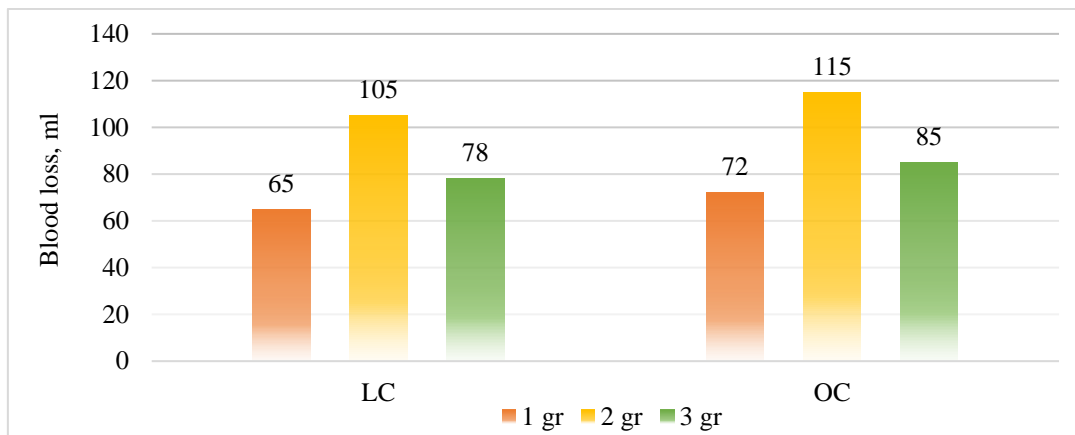


Figure 6. The volume of blood loss in ml.

The total duration of the surgical intervention, which amounted to in the studied groups, also changed commensurately. After LC in the main group was $61,2 \pm 4,8$ mins, in the control group $72,8 \pm 14,8$ mins, and in the comparison group $63,6 \pm 9,3$ mins ($p < 0,05$). After OC in the main group was $71,3 \pm 12,5$ mins, in the control group $94,7 \pm 28,7$ mins, and in the comparison group $74 \pm 10,8$ mins ($p < 0,05$) (Fig. 7).

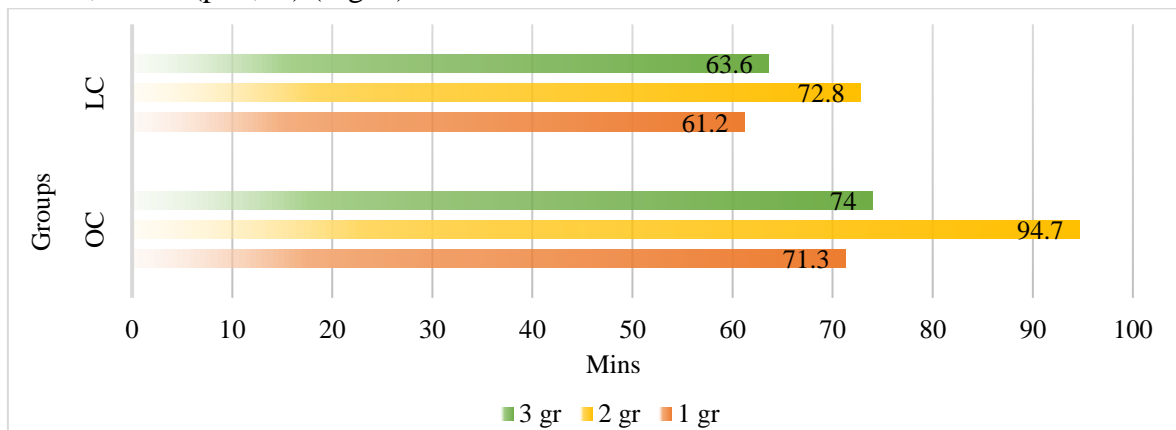


Figure 7. Duration of surgery in observation groups

When using electrocoagulation, it was also difficult to control the depth of electrosurgical exposure, which in 12 cases (11,8%) led to perforation of the gallbladder wall and bleeding, and in 6 cases (5,9%) - burns of the gallbladder bed in the control group. Postoperative complications of all groups of observations after laparoscopic and open cholecystectomy are presented in tables 1 and 2.

Table 1. The nature and frequency of postoperative complications after LC

Complications	I main group (n=37)		II control group (n=56)		III comparison group (n=14)	
	abs.	%	abs.	%	abs.	%
General (non-specific):	5	13,5	10	17,9	2	14,3
Fever	3	8,1	8	14,3	2	14,3
Pneumonia	1	2,7	1	1,8	-	
Urinary tract infection	1	2,7	1	1,8	-	

Specific:	1	2,7	4	7,1	1	7,1
Inflammation of the postoperative wound	1	2,7	2	3,6	1	7,1
Suppuration of the wound	-		-		-	
Subhepatic abscess	-		-		-	
Intra-abdominal bleeding	-		1	1,8	-	
Bile leakage	-		1	1,8	-	
Bladder bed hematoma	-		-		-	
Total	6	16,2	14	25	3	21,4

* The frequency of postoperative complications between the study groups is statistically significant ($p < 0,001$)

As can be seen from tab. 1, in the main group after LC specific complications were observed in 1 (2,7%) patient. In the control group, 4 (7,1%) patients had specific complications. In the comparison group, 2 (14,3%) had general complications and 1 (7,1%) had specific complications.

Table 2. The nature and frequency of postoperative complications after OC

Complications	I main group (n=43)		II control group (n=45)		III comparison group (n=5)	
	abs.	%	abs.	%	abs.	%
General (non-specific):	6	13,9	8	17,8	1	20
Fever	4	9,3	6	13,3	1	20
Pneumonia	1	2,3	1	2,2	-	
Urinary tract infection	1	2,3	1	2,2	-	
Specific:	2	4,6	6	13,3	-	
Inflammation of the postoperative wound	2	4,6	1	2,2	-	
Suppuration of the wound	-		1	2,2	-	
Subhepatic abscess	-		1	2,2	-	
Intra-abdominal bleeding	-		1	2,2	-	
Bile leakage	-		1	2,2	-	
Bladder bed hematoma	-		1	2,2	-	
Total	8	18,5	14	31	1	20

*The frequency of postoperative complications between the study groups is statistically significant ($p < 0,001$)

In the main group after OC, specific complications were observed in 2 (4,6%) patients, in the control group, in 6 (13,3%) specific complications, in the comparison group, in 1 (20%) patient, a general complication was noted.

In traditional cholecystectomy, the use of hemostatic sponge is characterized by a number of advantages over the use of high-frequency electricity: a high degree of adhesion of the hemostatic sponge to the gallbladder bed, instant stoppage of bleeding, complete absence of tissue damage, exclusion of damage to deep-lying vessels and bile ducts.

As a result of repeated coagulation of the gallbladder bed, an additional zone of coagulation necrosis was formed, which in the postoperative period was a source of hyperthermia and a substrate for the pyo-inflammatory process.

Carrying out LC in the control group was complicated by the "burning" of coagulated tissues to the working surface of the electrosurgical apparatus, which reduced the power of the coagulator - the burnt coagulation scab came off and bleeding resumed. Such excesses require the suspension of the operation to clean the instrument, which increases the overall duration of LC.

Conclusion:

1. New hemostatic sponge "Gemogubka" is a fairly effective local hemostatic agent. Gemogubka - causes rapid hemostasis due to the high degree of adhesion.
2. It has been established that the hemostatic sponge "SPONGOSTAN™ STANDART" is inferior to the domestic drug hemostatic sponge in terms of adhesive and hemostatic characteristics. The time of hemostasis when using the hemostatic sponge "SPONGOSTAN™ STANDART" is on average $3,1 \pm 0,54$ mins, and hemostasis - $2,3 \pm 0,47$ mins.
3. The developed method, based on the use of hemostatic sponge, allows avoiding specific dangers and complications of electrosurgical methods for stopping bleeding from the gallbladder bed, reducing postoperative complications by 1,5 times, however, hemostatic sponge cannot completely replace electrocoagulation in cases of bleeding from vessels with a caliber of more than 1 mm. In these cases, spot coagulation is performed in the area of bleeding.

References:

1. Baluda M.V., Fomin V.S. A modern view on the problem of hemostasis of the gallbladder bed. Surgeon. -2007. No. 4. - P. 69-76. (In Russ.)
2. Boyko V.V., Remneva N.A., Chernyaev N.S., Britskaya N.N. Pathological features of the resection margin of the liver immediately after the use of a high-frequency electrosurgical welding machine and a monopolarelectrocoagulator. News of Surgery. 2015;23(3). P 256-61. (In Russ.)
3. Cherkova N.V. Comparative assessment of liver regeneration under the influence of electrocoagulation and ultrasonic scalpel. Bulletin of KhNU named after V.N. Karazin. Ser Medicine. 2004;(7). P 9-13. (In Russ.)
4. Dambaev G.Ts., Baikov A.N., Semichev E.V., Shpisman M.N., Aleinik A.N., Deneko O.I., et al. Intraoperative methods of hemostasis during operations on the liver. Bull Sib Medicine. 2011;10(4). P 89-92. (In Russ.)
5. Gorsky V.A., Shurkalin B.K., Faller A.P., Rzhebaev K.E., Kakurin S.N. Methods for implementing additional hemostasis during operations on the liver and bile ducts. Khirurgiya. Supplement to the magazine Consilium Medicum. - 2015. - No. 1. - P. 74-80. (In Russ.)
6. Martinez-Ramos C., A. Lopez-Pastor, J. R. Nùñez-Peña, M. Gopegui, R. Sanz-López, T. Jorgensen, L. Pastor, J. L. Fernandez-Chacon&S. Tamames-Escobar. Changes in hemostasis after laparoscopic cholecystectomy // Surgical Endoscopy volume 13, P. 476–479(2014).
7. Ong A.M, Bhayani S.B, Hsu T.H, Pinto P.A, Rha K.H, Thomas M., et al. Bipolar needle electrocautery for laparoscopic partial nephrectomy without renal vascular occlusion in a porcine model. Urology. 2003 Dec; 62(6). P 1144-48.

8. Rakhimov O.U. Experience of application of a new hemostatic agent "Gemogubka" in the prevention of bleeding from the gall bladder bed after traditional cholecystectomy// The American Journal of Medical Sciences and Pharmaceutical Research (ISSN – 2689-1026). - 2020. P. 122-131.
9. Rakhimov O.U., MukhammadsolihSh.B. Clinical evaluation of the method of application hemostasis using a new domestic drug "Hemogubka" after cholecystectomy // Turkish Journal of Physiotherapy and Rehabilitation: Volume 32 - Issue 2, Publication Year: 2021 – P. 4428-4436.
10. Sadykov R.A., Ismailov B.A., Kim O.V. New film coating made from cellulose derivatives for local hemostasis // News of Surgery. 2019; 3 (27): 256-263. (In Russ.)
11. Sedov V.M., Yurlov V.V., Petrishin V.L., Boikova N.V., Semenov G.M., Korablin N.M. Some patterns of morphological changes in the liver tissue during electrical exposure. Bulletin of Surgery named after I.I. Grekov. 2001;160(4). P 27-31. (In Russ.)
12. Tursumetov A.A., Rakhimov O.U. An Innovative approach to the prevention of hemorrhage from the gallbladder bed after cholecystectomy // Solid State Technology Volume: 63 Issue: 6, Publication Year: 2020 – P. 15231-15245.