

Original research article

Study of sacrum in patients with low back pain

Dr. Gouri B Kaveriappa

Assistant Professor, Department of Radio Diagnosis, Father Muller Medical College, Mangalore, Karnataka, India

Corresponding Author:

Dr. Gouri B Kaveriappa

Abstract

In the present study, it was proved that deficiency on the dorsal surface of the sacrum is higher among the low back pain patients in whom it is one of the causes of the disease firmly established a larger study involving the living patients suffering from low back pain. Patients above 20 years age group attending the Radiology OPD with the digital radiograph of the antero-posterior view of lumbo-sacral spine with history of low back pain was considered.

Keywords: Sacrum, lower back pain, patients, radiology

Introduction

Sacrum is the fused lower five sacral vertebrae along with the coccyx at the caudal end of the vertebral column and it has the hiatus containing the rootlets of sacral and coccygeal spinal nerve. The compressive effect in the course of exit of the lower spinal nerve or anything else is the cause for low back pain. This prompted us to carry out the present study, which aimed to observe the vertebral level of apex and base of sacral hiatus & the length and transverse diameter of sacral hiatus among the patients with low back pain attending the radiology. Sacrum is formed by fusion of five sacral vertebrae and forms the caudal end of the vertebral column. The vertebral canal of Sacrum (Sacral canal) runs throughout the greater part of the bone. The opening present at the caudal end of sacral canal is known as sacral hiatus. It is located inferior to the fourth (or third) fused sacral spines at ^[1, 2] the lower end of median sacral crest. The Sacral hiatus contains lower sacral and coccygeal nerve roots, filum terminale externa and fibro ^[3] fatty tissue. The fifth sacral spinal nerves and coccygeal nerve emerge through the sacral hiatus close to the medial side of the sacral cornua. The sacral hiatus is covered only by skin, a subcutaneous fatty layer ^[4, 5] and the sacro-coccygeal membrane the shape of the sacral hiatus shows many variations. Sometimes lamina of more than one sacral vertebra or laminae of all sacral vertebrae remain non fused. In these conditions a wide gap is formed in that region. Hence the surface area for muscular attachment is decreased which may lead to pain sensation ^[6-10] at the back region. Cross-sectional descriptive study was conducted among the patients with history of low back pain attending the Department of Radiology.

Aims and Objectives

To study the sacrum in patients with low back pain.

Materials and Methods

This study was done in the Department of Radio-Diagnosis, Father Muller Medical College, Mangalore from June 2013 to May 2014.

This study was done using 120 patients.

Inclusion criteria

Patients with lower back pain.

Exclusion criteria

Patients with history of trauma.

With orthopaedic treatment.

Results

Table 1: Age Distribution

30-40 years	22
41-50 years	40
51-60 years	38
61-70 years	20

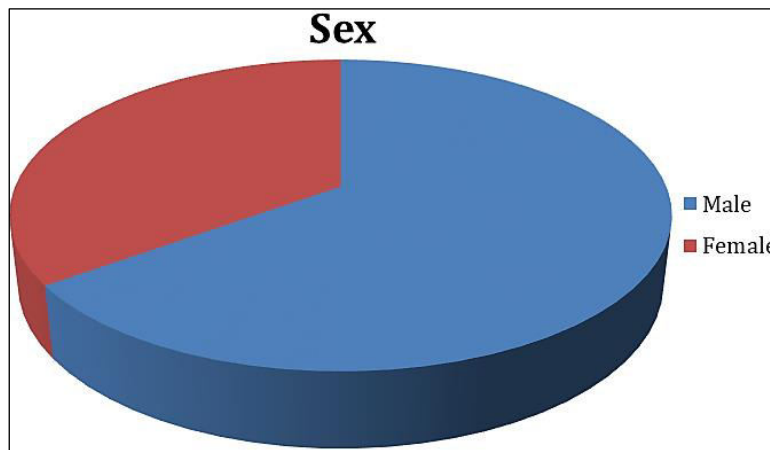


Fig 1: Sex Distribution

Table 3: Sacral Hiatus and Backpain according to x-rays

Level	Back pain	P value	Significance
S4	13	<0.0012	Significant
S5	47		

Discussion

Variations in dorsum of the sacrum may have some association with clinical conditions like low back pains. The sacral hiatus is an important bony landmark. Clinicians sometimes experience difficulties in determining the hiatus of sacrum by palpating it clinically. It is therefore important to describe the anatomical variations of the location of sacral hiatus to guide the clinical procedure e.g. caudal epidural block. Long back Brailsford JF proposed that the variation in the development of the sacral hiatus can cause decrease area for the attachment of extensor muscle at back causing painful conditions. In spina-bifida the laminae of all the sacral vertebrae fail to fuse at back leading open sacral canal i.e. a midline gap. In spina-bifida occulta the posterior element of upper sacral vertebrae fail to fuse. Mehmet S *et al.*^[7,8] and Kumar V *et al.* also mentioned that these kinds of anatomical variations would lead to painful condition of the back and some clinical procedural failures. Variants of sacral hiatus (SH) may be considered as the lower pole of the spectrum of failure in fusion of laminae of sacral vertebrae with spina-bifida as its highest grade which is established to be due to folic acid deficiency during^[9] pregnancies. Malarvani T *et al.* also supported this hypothesis that this developmental variations of the dorsum of the sacral bone leads to the decreased surface area for the attachment of extensor muscles of the back and so even a mild stress to these muscles would make it strain more and result in painful conditions of the back. So, studying the area of sacral hiatus i.e. level of its apex; its length, breadth and diameter is a pertinent issue. Knowledge of higher area of sacral hiatus as one of the causes of low back pain can be utilized for prevention of this chronic disabling condition. In the present study the percentages among male and female low back pain patients having their apex of sacrum at S4 level were revealed to be 91.30 percent and 96.29 percent, respectively 8 and these were higher than what were observed by Kumar *et al.*^[10] Contrary to the observations made by Mohamed SM *et al.* the present study revealed that there was no statistically significant difference between the mean sacral hiatal length across the gender.

Conclusion

Knowledge of higher area of sacral hiatus as one of the causes of low back pain can be utilized for prevention of this chronic disabling condition.

References

1. Standerling S. Gray’s anatomy: the anatomical basis of clinical practice, 39th edn. Elsevier, Churchill Livingstone, Edinburg, 2005, 749-754.
2. Gray H, Peter Anatomy Lwilliam. Gray’practice; Skeletal system, 38th edition. Churchill Livingstone,

2008.

3. Ernest JF. Anatomy of the Human Skeleton; J and A Churchill Ltd, London, 1914, 37-42.
4. Gray's Anatomy, 35th edition, Orient Longman, 1973, 242-244.
5. Phalgunan V, Baskaran S. Morphological analysis of sacral hiatus and its clinical significance: The Health Agenda, 2013, 1(1).
6. Brailsford JF. Deformities of lumbosacral region of spine. Br J Surg. 1929;16:562-627.
7. Mehmet S, Johongir MM, Ali D. Evaluation of Congenital Lumbosacral Malformations and Neurological Findings in Patients with Low Back Pain, Turkish Neurosurgery. 2009;19(2):145-8.
8. Kumar V, Vinay KV, Remya K, Kumar A, Shishir K. High sacral hiatus with non-fusion of lamina of first sacral vertebrae: a case report. NUJHS. 2012;2(4):60-2.
9. Malarvani T, Ganesh E, Nirmala P. Study of sacral hiatus in dry human sacra in Nepal, Parsa region. Int. J Anat. Res. 2015;3(1):848-55.
10. Mohamed SM, Omayma MM, Hoda HAELR, Hosam MA. Morphometric study of sacral hiatus in adult human Egyptian sacra: Their significance in caudal epidural anesthesia. Saudi J Anaesth. 2012;6(4):350-7.