ISSN:0975-3583,0976-2833 VOL12,ISSUE02,2021

ORAL LEUKOPLAKIA: A CASE REPORT

Dr. Sourab Kumar
Associate Professor, Dept. of Oral Pathology and Microbiology D Y Patil University, School of Dentistry, Nerul, Navi Mumbai, Maharashtra
sourab.kumar@dypatil.edu
Dr. Subraj Shetty
Associate Professor, Dept. of Oral Pathology and Microbiology D Y Patil University, School of Dentistry, Nerul, Navi Mumbai, Maharashtra
subraj.shetty@dypatil.edu
Dr. Sheiba Gomes
Professor, HOD, Dept. of Public Health Dentistry D Y Patil University, School of Dentistry, Nerul, Navi Mumbai, Maharashtra
cathybabu93@gmail.com
Dr. Rutuja Gajanan Vidhale
Post graduate student, Dept. of Oral Pathology and Microbiology D Y Patil University, School of Dentistry, Nerul, Navi Mumbai, Maharashtra
rutuja.vidhale@gmail.com
Dr. Nikita Kamble
Post graduate student, Dept. of Oral Pathology and Microbiology D Y Patil University, School of Dentistry, Nerul, Navi Mumbai, Maharashtra
nikita.kamble@dypatil.edu
Dr. Priyadharshini
Post graduate student, D Y Patil University, School of Dentistry, Nerul, Navi Mumbai, Maharashtra
priyadharshiniteju@gmail.com

ABSTRACT

Oral leukoplakia (OL) grabs the place of being one of the most common oral potentially malignant disorders of the oral mucosa. As a result of differences in tobacco and dietary habits the annual percentage of malignant transformation varies in different parts of the world. The tongue and the floor of the mouth can be considered to be high-risk sites with regard to malignant transformation of leukoplakia in some parts of the world. Management of this condition remains a variable and includes local, topical, and systemic therapies such as antioxidants, carotenoids, and antifungal therapies. Cessation of tobacco consumption habits, as being the most common etiological factor of OL, has shown to be an effective measure with regard to the incidence of oral cancer as well. Therefore, in view of many predominantly white or white lesions of the mucosa of oral cavity, it is a great challenge for the oral health care professionals to clinically identify and diagnose a leukoplakia, being a potentially (pre) malignant lesion. In this article, we discuss one such case of leukoplakia.

Keywords: Leukoplakia, dysplasia, white patch, malignancy

ISSN:0975-3583,0976-2833 VOL12,ISSUE02,2021

INTRODUCTION

In India, 0.2 to 4.9% leukoplakia cases are observed amongst other premalignant lesions. Majority of leukoplakia cases are seen in men of the age within 35-45 years. Most frequently leukoplakia occurs in middle aged or older men and their frequency increases along with age.[1] Most commonly leukoplakia occurs on the buccal mucosa, lower lip and alveolar mucosa showing dysplastic changes.[2] The term leukoplakia is used only as a clinical entity with no proper histology. Clinically it is seen as white plaques and histologically, it shows atrophy or acanthosis with epithelial dysplasia which may or may not be observed. Leukoplakia shows an inconsistent pattern with a slight tendency for malignant transformation.[3] The case reported in this article is of hyperkeratotic lesion with mild dysplasia.

Case report:

A 61‑year‑old male patient was reported with an ulceroproliferative lesion on the left buccal vestibule and attached gingiva of 33 regions. Lesion appeared 6 months back with a history of local trauma. Clinical examination revealed an extraosseous, pinkish white patch extending from mesial surface of 33 up to distal surface of 34. [Figure 1]. The patient had a history of tobacco chewing, which he stopped 25 years ago and a medical history of hypertension for 8 years. Oral hygiene was satisfactory, revealing generalized chronic gingivitis. A provisional diagnosis of squamous cell carcinoma was made; the lesion was incised under local anesthesia. Histopathological examination revealed a hyperparakeratinized stratified squamous epithelium and underlying connective tissue stroma. Dysplastic features like altered nuclear cytoplasmic ratio, nuclear hyperchromatism, individual cell keratinization and increased mitosis were observed in the epithelium. Connective stroma was composed of few inflammatory cell infiltrate and extravasated RBCs. [Figure 2] Based on the histopathological examination a final diagnosis of hyperkeratotic lesion with mild dysplasia was made

Figure 1: Clinical photograph showing lesion extending from mesial surface of 33 up to distal surface of 34

ISSN:0975-3583,0976-2833 VOL12,ISSUE02,2021

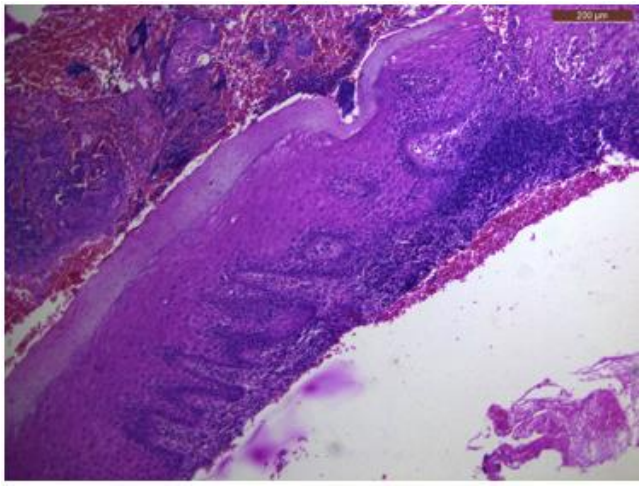

Figure 2: Photomicrograph showing hyperparakeratinized stratified squamous epithelium with dysplasia and underlying connective tissue stroma (H & E 10X)

DISCUSSION

Various studies show that 1-18% of pre-malignant lesions occurring in the oral cavity do transform into cancer. Cancer development in these lesions depends on a variety of factors, like genetics, geographical traits, differences are observed studies depending upon the case selection, sample size selection, etc. Population-based studies also have an influence on the survey and thus transformation rates vary accordingly. Thus one cannot say for sure as to whether or not all clinically detectable lesions characterized as precursors will eventually develop into carcinomas.[4,5] Leukoplakia is a premalignant lesion showing a white patch or plaque which cannot be confirmed clinically or pathologically as any other disease with the most common occurrence in tobacco smokers and chewers.[6]

Leukoplakia occurs either in one of the two variants: Homogeneous and the non-homogeneous type. Homogeneous leukoplakia is seen as a uniform flat white lesion, it appears thin, and has a smooth, wrinkled or corrugated surface throughout the lesion. Non-homogeneous type is a combination of red and white lesion that appears irregularly flat, or nodular, or has a verrucous surface.[7]

In the present case, overall clinical and histopathological features were suggestive of a hyperkeratotic lesion with mild dysplasia. It was advised to keep the patient under observation in view of dysplasia. A retrospective study conducted using over more than 3000 cases of oral white lesions showed that almost 20% of leukoplakia cases had some degree of epithelial dysplasia. A significant correlation was obtained within the site and the incidence of dysplastic

ISSN:0975-3583,0976-2833 VOL12,ISSUE02,2021

or malignant changes during the biopsy. Other than the site of the lesion, the clinical aspect also has some correlation with the dysplastic or malignant changes. Thus it is concluded that the thickness of the lesion is directly related to more dysplastic or malignant changes; therefore, a verrucous leukoplakia has a greater chance to show dysplasia than a thick homogeneous leukoplakia, which, in turn, has a greater chance to show dysplasia than a thin leukoplakia. Several studies have shown the incidence of dysplastic or malignant transformations in oral leukoplakia varies from 15.6 to 39.2%.[1]

CONCLUSION

Amongst the premalignant lesions, oral leukoplakia is most commonly observed. Diagnosis of such lesions requires a detailed habit history and a meticulous clinical examination. Along with thorough clinical history, biopsy procedures can also help in differentiating leukoplakia from other white lesions. Oral leukoplakia have a high malignant transformation rate, therefore early detection is a must. Newer non-invasive methods like immune histo chemical markers can help in early detection and thus reduce the malignant transformation rates.

REFERENCES

1. Aggarwal, Bhateja. Leukoplakia-potentially malignant disorder of oral cavity-a review. Biomed J Sci Tech Res
2. Waldron CA, Shafer WG. Leukoplakia revisited. A clinicopathologic study 3256 oral leukoplakias. Cancer 1975;36(4):1386–92.
3. Jemal, Ward, Center, Hao, Siegel. Global cancer facts & figures 2007. Atlanta, GA: American
4. Silverman S Jr. Oral lichen planus: a potentially premalignant lesion. J Oral Maxillofac Surg 2000;58(11):1286–8.
5. Shukla A. Potentially malignant disorders of the oral cavity: a clinical study. Indian J Otolaryngol Head Neck Surg 2014;66(1):79–85.
6. Rodriguez-Pérez I, Bánóczy J. Oral leukoplakia. A histopathological study. Acta Morphol Acad Sci Hung 1982;30(3-4):289–98.
7. Chandak R, Chandak M, Sathawane R, Lohe V, Bansod R, Bansod R. Ruminating the Pathway of Oral Leukoplakia- A Review. Annals of RSCB 2021;6761–71.