

## **PREFABRICATED SPACE MAINTAINER VS CONVENTIONAL SPACE MAINTAINER: A CASE REPORT**

### **Dr. J. Jasmin Winnier**

Associate Professor, Department of Pediatric and Preventive dentistry, D. Y Patil University,  
School of Dentistry, Nerul, Navi Mumbai- 400706.  
jasmin.winnier@dypatil.edu

### **Dr. Rucha Bhise Patil**

Associate Professor, Department of Pediatric and Preventive dentistry, D. Y Patil University,  
School of Dentistry, Nerul, Navi Mumbai- 400706.

### **Dr. Ashveeta Shetty**

Lecturer, Department of Pediatric and Preventive dentistry, D.Y Patil University, School of  
Dentistry, Nerul, Navi Mumbai- 400706.

### **Dr. Arwa Soni**

Post Graduate students, Department of Pediatric and Preventive Dentistry, D.Y Patil  
University, School of Dentistry, Nerul, Navi Mumbai- 400706.

### **Dr. Shivani Mehta**

Post Graduate students, Department of Pediatric and Preventive Dentistry, D. Y Patil  
University, School of Dentistry, Nerul, Navi Mumbai- 400706.

### **Dr. Chinmaya Chaudhary**

Post Graduate students, Department of Pediatric and Preventive Dentistry, D. Y Patil  
University, School of Dentistry, Nerul, Navi Mumbai- 400706.

### **ABSTRACT**

Despite efforts at prevention, premature loss of deciduous tooth is still a prevalent issue, disrupting the integrity of the arch and negatively influencing the positioning of permanent successors. Distinctive equipment called space maintainers (SMs) are used to preserve spaces left behind after primary teeth are lost too soon. In this case report, a traditional band and loop space maintainer was compared with prefabricated space maintainer which can be easily place in a single appointment with a lesser chair side time.

Key words: Primary teeth, Space maintenance, prefabricated, conventional

### **INTRODUCTION**

Early primary tooth loss in children is common and is typically caused by trauma and caries. Alignment of the developing teeth underneath cannot be achieved with a narrow arch which occurs due to early loss of deciduous molars causing crowding, malpositioning and impaction of the developing tooth.<sup>i</sup>

Placing an efficient, inexpensive, and long-lasting space maintainer in children who have lost their primary teeth prematurely is the most reliable method to prevent future malocclusion. Maintaining mesiodistal connections in the dental arch is the primary

responsibility of space maintainers. To prevent the space from obviating and to lessen those effects, proper usage of space maintainers is advised until permanent teeth emerge.<sup>ii iii</sup> It is preferable to place a space maintainer within the first 30 days following tooth loss since studies by Lin YT, Macena MC, Tunison have shown that majority of space closure occurs in the initial 6 months after tooth loss.<sup>iv v vi</sup>

There are a variety of devices may be used as space maintainers depending on child's dental growth stage and the arch and tooth involved.<sup>vii</sup> Even though removable space maintainers have a number of benefits, such as being simple to clean and allowing children to practice improved oral hygiene, they could also be lost or broken. Additionally, patient compliance is mandatory. Retention and acceptance are two issues for this type of space maintainer. According to previous studies, both dental professionals and patients prefer the use of fixed space maintainers.<sup>viii</sup>

Band and loops are the most extensively used fixed space maintainers in children because they are economic and easy to produce. Nonetheless since they hinder the emergence of adjacent teeth and put the abutment tooth at risk for decay, they require constant treatment and follow ups. These space maintainers are easily adjustable for improved dentition adaptation, but neither do they facilitate mastication nor do they stop the emergence of the teeth.

This space maintainer is utilized for premature and one-sided loss of deciduous molars before or after the emergence of the first molar as well as two-sided loss of deciduous molars ahead of the emergence of permanent incisors.<sup>lix x</sup>

The conventional band and loop space maintainers fail primarily due to cement dissolution or solder failure. Placement of these appliances also require two appoints and a relatively positive patient co-operation. Impressions are essential and it may be difficult to achieve undistorted impressions in a patient with hyperactive gag reflex.

Prefabricated band and loops devices were introduced to dentistry in recent times. They can possibly overcome most of the previously mentioned limitations of conventional space maintainers. 84.4% success rate for the prefabricated device was reported by Setvia V( 2014) and Tahririan D ( 2019).<sup>xi</sup>

## CASE REPORT

A 5-year-old male child reported to the Department of Pediatric And Preventive Dentistry with the chief complaint of pain in the lower right and left back region, with an extra oral swelling on the right lower side of the face since the past 1 day.[Figure 1] No significant medical history was mentioned.

On intraoral examination, the presence of a deep carious lesion on tooth no. 84 and 74 was observed.[Figure 2] Analgesics and antibiotics were given to the patient and recalled after 3 days.

Intraoral periapical radiograph revealed the presence of diffuse inter-radicular radiolucency extending periapically and root resorption in relation to tooth no. 84, due to poor prognosis of the tooth, decision for extraction of tooth 84 was carried out.[ Figure 3].The patient presented after 1 week with pain and extra oral swelling on the left side of the face, similar radiographic findings were observed and decision for extraction was carried out. [Figure 4]

Decision for space maintainer delivery was carried out to prevent space loss on either sides using bilateral band and loops were to be fabricated and delivered. Conventional band and loop space maintainer was done on right side, on tooth 85. Preformed band which fitted snugly, size 33 was selected, then adapted onto the tooth. Alginate impressions was taken, band was stabilized into the impression using cyanoacrylate ester, dental stone was poured into it and the cast was retrieved. Loop was fabricated according to the length and width available in the arch between 85 and 83, which was later was soldered onto the band, trimmed and polished. Patient was recalled and then, the band and loop space maintainer was delivered.[Figure 6]

A prefabricated band and loop space maintainer by Kids-e-dental<sup>®</sup> was fabricated and delivered on the same day on tooth 75[ Figure 5]. A band which fitted the tooth snugly, size 35.5 was selected and adapted onto the tooth, pre formed loop were evaluated and selected , the excess loop wire to be eliminated was marked and trimmed off using the wire cutter given in the kit. Crimper available along with the kit was placed at the centre of the tube and partial crimping was done intraorally and final crimping was done extraorally after the space maintainer was removed.

## DISCUSSION

One of the critical functions of the primary tooth is to occupy the physiological space and guide the eruption of its permanent successor.<sup>xii</sup> Precocious loss of deciduous molars without adequate intervention may result in space loss for successors. It has been reported that following extraction of the primary first molar, there is a space loss of 1.5 mm in the mandible and 1 mm in the maxilla.<sup>xiii</sup> Early loss of the deciduous molars had a prominent effect on dental arch dimensions leading to 2–4 mm of space closure per quadrant in maxillary as well as mandibular arch. Substantial space loss occurs due to mesial movement of the permanent molars.<sup>xiv</sup>

With the conventional method, although the selection of preformed bands took minimal time, an impression was required to make, after which band was stabilized into the impression and patient recalled. This contributed to increase in steps and chair side time, onto which lab steps were added such as cast pouring, loop fabrication, soldering, trimming and polishing. Contrast to this appliance was the prefabricated one, which eliminated a second visit and lab steps, thus inevitable decreasing patient cost, chair side time and operator fatigue.

Although minimal research has been done using prefabricated space maintainers, in regards to adaptation on unusual tooth anatomy, longevity, strength and gingival health.

## CONCLUSION

Prefabricated space maintainer can be considered as a possible substitute conventional space maintainers which will reduce chair side time, patient visit, cost and operator fatigue.

## REFERENCES

- 
1. Casamassimo PS, Fields HW, Jr, McTigue DJ, Nowak A. Pediatric Dentistry: Infancy Through Adolescence. India: Elsevier Health Sciences; 2013.
  2. Bayardo RE. Anterior space maintainer and regainer. ASDC J Dent Child. 1986;53:452–5.
  3. Hill CJ, Sorenson HW, Mink JR. Space maintenance in a child dental care program. J Am Dent Assoc. 1975;90:811–5.
  4. Lin YT, Lin WH, Lin YT. Immediate and six-month space changes after premature loss of a primary maxillary first molar. J Am Dent Assoc. 2007;138:362–8

- 
5. Macena MC, Tornisiello Katz CR, Heimer MV, de Oliveira e Silva JF, Costa LB. Space changes after premature loss of deciduous molars among Brazilian children. *Am J Orthod Dentofacial Orthop.* 2011;140:771–8.
  6. Tunison W, Flores-Mir C, ElBadrawy H, Nassar U, El-Bialy T. Dental arch space changes following premature loss of primary first molars: A systematic review. *Pediatr Dent.* 2008;30:297–302.
  7. Tunc ES, Bayrak S, Tuloglu N, Egilmez T, Isci D. Evaluation of survival of 3 different fixed space maintainers. *Pediatr Dent.* 2012;34:e97–102
  8. Foster T. *A Text Book of Orthodontics.* Ed London: Blacwell; 1990. Dental factors affecting occlusal development; pp. 129–46.
  9. Christensen J, Fields H. *Pediatric Dentistry: Infancy through Adolescence.* 4th ed. St Louis, Mo: Elsevier Saunders; 2005. Space maintenance in the primary dentition; pp.
  10. Kisling E, Høffding J. Premature loss of primary teeth: Part III, drifting patterns for different types of teeth after loss of adjoining teeth. *ASDC J Dent Child.* 1979;46:34–8.
  11. Tahririan D, Safaripour M, Eshghi A, Bonyadian AH. Comparison of the longevity of prefabricated and conventional band and loops in children's primary teeth. *Dent Res J (Isfahan).* 2019 Nov 12;16(6):428-434.
  12. Stanley J. Nelson development and eruption of teeth. In: *Wheeler's Dental Anatomy, Physiology and Occlusion.* Philadelphia: Elsevier Health Sciences; 2014.
  13. Tunison W, Flores-Mir C, ElBadrawy H, Nassar U, El-Bialy T. Dental arch space changes following premature loss of primary first molars: A systematic review. *Pediatr Dent* 2008;30:297-302.
  14. Northway WM, Wainright RL, Demirjian A. Effects of premature loss of deciduous molars. *Angle Orthod* 1984;54:295-329.

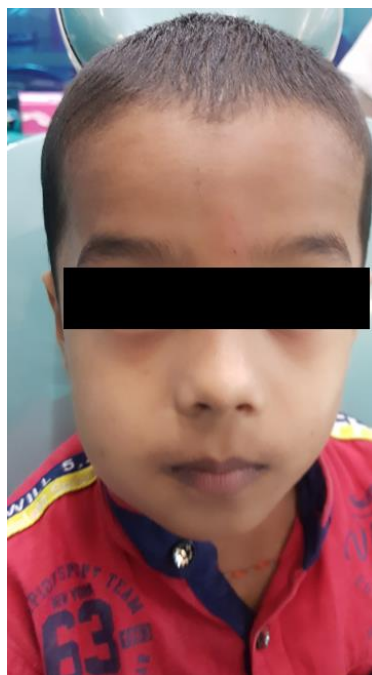

Fig 1: Extra oral swelling on right side of face

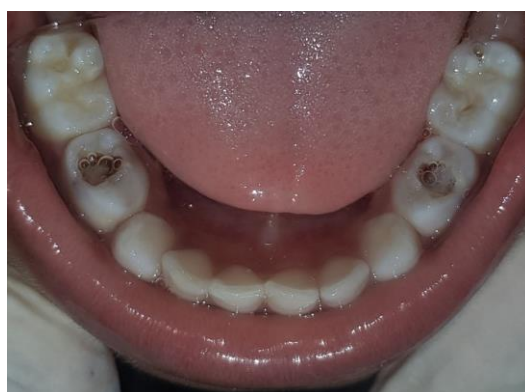

Fig 2: Deep carious lesions on right and left lower back region, involving tooth no. 74 and 84

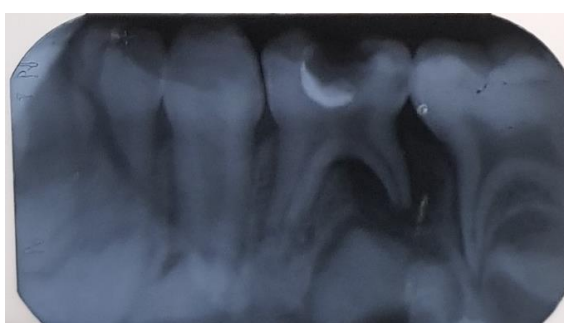

Fig 3: Tooth No. 84

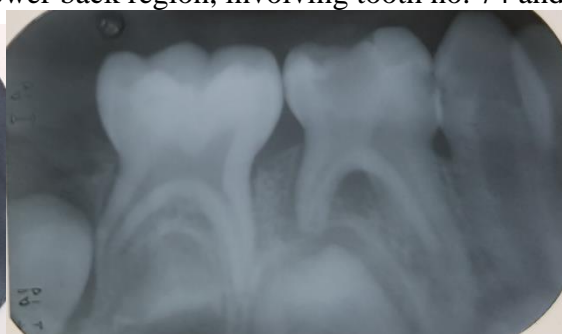


Fig 4: Tooth No. 74



Fig 5: A prefabricated band and loop space maintainer by Kids-e-dental®

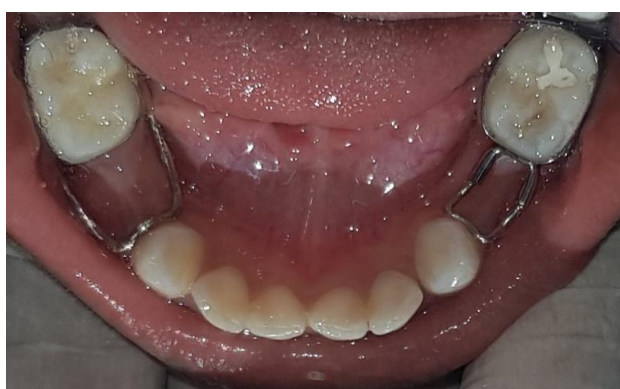

Fig 6: Conventional space maintainer on right side and prefabricated space maintainer on left side