

ORIGINAL RESEARCH

Mid-Term Clinical and Echocardiographic Outcomes of Extensive Septal Myectomy for Hypertrophic Obstructive Cardiomyopathy¹Mausam Shah, ²Ronak Khojani, ³Nirav Panchal, ⁴Jignesh Kothari^{1,2}Assistant Professor, ³Associate Professor, ⁴Professor, Department of Cardiovascular and Thoracic Surgery, U. N. Mehta Institute of Cardiology and Research Centre, Civil Hospital Campus, Asarva, Ahmedabad, Gujarat, India**Corresponding author**

Jignesh Kothari

Professor, Department of Cardiovascular and Thoracic Surgery, U. N. Mehta Institute of Cardiology and Research Centre, Civil Hospital Campus, Asarva, Ahmedabad, Gujarat, India

Email: jvks20@yahoo.com

Received: 17 December, 2022

Accepted: 20 January, 2023

Abstract**Introduction:** This study was planned to see the mid-term clinical and 2-D echocardiographic outcomes of extensive septal myectomy for hypertrophic obstructive cardiomyopathy.**Methods:** Fifty-one patients of all age groups suffering from HOCM were enrolled in this study. They were selected on basis of two inclusion criteria are LVOT pressure gradient ≥ 50 mmHg direct by transthoracic echocardiography and second one presence of severe symptoms despite appropriate medical therapy with Beta-blockers and calcium channel blockers. A septal myectomy was done. Follow-up: The follow-up period averages 1 year for HOCM patients. Follow-up data were derived from medical charts and LVOT gradient information was obtained from the record of transthoracic echocardiography detection at every outpatient visit.**Results:** After one year of surgery, the 2-D Echo finding were similar to the finding at the time of discharge, mean gradient around 11.83mmHg, septal thickness around 11.45mm during systole and 12.49 mm during diastole and posterior wall thickness around 12.07mm . There was no gross difference. Preoperatively all patients have normal left ventricular function, following septal myectomy, only 2 patients had EF <45%, following follow-up of 1 year three patient had EF <45%.**Conclusion:** Septal myectomy and adjunctive procedures provide excellent relief of symptoms and improve cardiac function in HOCM patients in the early postoperative period and at 1-year follow-up. Pre-operative identification of risk factor, pre-operative optimisation and intra-operative adequate resection gives a better symptomatic and echocardiographic outcome with the patient can perform normal routine activity.**Keywords:** HOCM- hypertrophic obstructive cardiomyopathy, LVOT- left ventricular outflow tract, TEE- transthoracic echocardiography, CHB- complete heart block, LBBB- left bundle branch block, PPI- permanent pacemaker implantation, IVS- interventricular septum, PW- posterior wall, SAM- systolic anterior motion, MVR- mitral valve replacement.**Introduction**

Hypertrophic obstructive cardiomyopathy is a genetic cardiovascular disease characterized by increased left and or right ventricular wall thickness that is not solely explained by loading

conditions. It is one of the few ailments which is well studied yet that knowledge is not fully understood.¹

Initially accurately described by Teare (London pathologist) in 1958 in young people who died suddenly. Braunwald and colleagues distinguish it from another cardiomyopathy, Goodwin and colleagues named it hypertrophic obstructive cardiomyopathy. It is the commonest genetic disease with mendelian autosomal dominant inheritance. It is the commonest cause of sudden cardiac death in young adults. Left untreated it causes significant morbidity and mortality. The incidence of the disease is around 0.1 -0.5 % in the general population.² Even though several aetiology have been proposed, genetics remains the most important and with the maximum strength of association.

Symptomatology of HCM varies from mild symptoms to sudden cardiac death. Evaluation of these patients starts with symptom analysis and invasive and non-invasive imaging modalities.

Treatment strategies for HOCM evolved gradually over the years which started with the myectomy described by Morrow. Since then, surgery as well as medical and invasive methods evolved over years. But the gold standard is surgical myectomy.³⁻¹⁰ In this study we will be analysing the results of surgical myectomy.

Materials and methods

Ethics committee approval was taken from our institutional ethics committee. The current study is about patients with hypertrophic cardiomyopathy who underwent surgical myectomy as the primary treatment. Patient samples were selected over 5 yrs, from January 2015 to December 2020. Fifty-one patients underwent myectomy during these periods. The current study is a retrospective and prospective descriptive study. All patients were evaluated by consultant cardiologists. Although they were given medical therapy, they still had severe symptoms attributable to LVOT obstruction. The review of hospital records and analyses of preoperative data, operative reports, and postoperative and follow-up echocardiography were carried out. In this study, the perioperative period was defined as the period from surgical preparation to 30 days.

Inclusion Criteria

- LVOT pressure gradient ≥ 50 mmHg at rest by transthoracic echocardiography;
- Presence of severe symptoms despite prior appropriate medical therapy with beta-receptor blocker and calcium channel blocker.

Patient undergoing surgery received the standard premedication, induction and anesthetic agents.

Surgical Procedure

Surgery was carried out under mild hypothermic cardiopulmonary bypass with total anaesthesia. The heart and ascending aorta were exposed by a longitudinal median incision in the sternum. Cannulas were inserted into the superior vena cava, inferior vena cava and ascending aorta to establish cardiopulmonary bypass. Through a transverse aortotomy, the aortic valve was exposed, and cardiac asystole was induced by cold blood antegrade cardioplegia. The hypertrophic septum and mitral valve were exposed sufficiently by pulling the right coronary aortic valve. A Ross retractor was used to display the muscular septum. The superior borderline of septal resection is located at 3 mm below the right coronary sinus valve. Resection started from the middle of the right aortic sinus and moved 10–12 mm horizontally toward the commissure of the left sinus valve and right sinus valve. Longitudinal resection usually reached the root of the mitral papillary muscle, the length of which ranged from 45 to 50 mm. To reduce the LVOT gradient, the thicknesses of the left ventricular wall

and interventricular septum need to be nearly normal by visual inspection. The resection was continued toward the mitral valve annulus and apically to the bases of the papillary muscles. All areas of papillary muscle fusion to the septum or ventricular free wall are divided, and anomalous chordal structures and fibrous attachments of the mitral leaflets to the ventricular septum are excised. Intraoperative transesophageal echocardiography (TEE) was used routinely. TEE assessment was performed after weaning from cardiopulmonary bypass to evaluate the adequacy of LVOT and mitral valve function.

2D Echocardiography

During the hospital stay, preoperative transthoracic echocardiography was performed for HOCM patients and intraoperative TEE was applied routinely. The adequacy of the resection and the LVOT gradient was assessed immediately by transthoracic echocardiography after surgery and transthoracic echocardiography was repeated before or on the day of hospital discharge. During the outpatient follow-up period, patients had transthoracic echocardiography detection at every visit. And transthoracic echocardiography at the end of one year. A careful analysis of septal hypertrophy, abnormalities of the mitral valve, and subvalvular apparatus was performed. LVOT gradient was detected at rest and with provocation by transthoracic echocardiography.

Follow-up

The follow-up period averages 1 year for HOCM patients. Follow-up data were derived from medical charts and LVOT gradient information was obtained from the record of transthoracic echocardiography detection at every outpatient visit. All patients were assigned New York Heart Association (NYHA) classification based on symptoms.

Statistical Analysis

Continuous variables were expressed as mean \pm SD otherwise described as proportion. χ^2 test was used to compare categorical variables.

Results

Fifty-one patients have undergone septal myectomy in our institute in the last 5 years, we included all age group patients. Patients were divided into four age groups less than 21, 21-40, 41-60, and more than 60 years.

The majority of a patient was found in the age group of 21-40 years around 20 (39.21%), followed by 18(35.29%) in the age group of 41-60years. 9 (17.64%) patients were less than 21 years. And 4 (7.84%) patients were above 60 years of age. The minimum age of the patient who underwent surgery was a 6-year female patient and the maximum age of the patient who underwent surgery was 70-year female and the men's age were 38 years. In our study, the incidence is more in the 21-40 years age group followed by in 41-60 year of age group and then the 20year group, HOCM is least common after the age of 60 years. Globally the disease affects more males than females, but females tend to have more severe disease. In our study also males 26 (50.98%) shows slight predominance as compared to females 25 (49.01%). (Table 1)

Patients with HOCM most commonly presented with dyspnoea. In this study, 46 (90.19%) patients presented with dyspnoea and associated complaints, and 5(9.80%) patients did not have dyspnoea. A total of 47(92.15%) patients were presented with NYHA class III, followed by 2 (3.96%) patients who presented with NYHA class II, and one patient presented with NYHA class I, this patient more symptomatic with chest pain. One patient presented with NYHA class IV dyspnoea associated with severe mitral regurgitation and severe left ventricular dysfunction. In this study, there were 24 (47.05%) patients presented with the

complaint of chest pain associated with dyspnoea and/or palpitation. And 27 (52.94%) patients with no chest pain.

A total of 14 (27.45%) patients had complained of palpitation out of which 13 patients had associated complaints of dyspnoea, and 5 patients had associated complaints of chest pain. 37 (72.54%) patients did not have to complain of palpitation. 13 (25.49%) patients had pre-operative arrhythmia, the most commonly atrial fibrillation and 38 (74.50%) patients did not have preoperative arrhythmias. In most patients, arrhythmias were not a presenting complaint, except for a few.

The average hospital stay was 11 days, more than 2 weeks postoperatively consider a prolonged hospital stay, a total of 10 (19.60%) patients had prolonged hospital stays, and 41(80.39%) patients got normal discharge on routine days. Prolong hospital stay was due to severe left ventricular dysfunction, pneumonia, septicaemia, and wound infection, Generally, mortality was < 2%, in our study it is 1 (1.96%), one patient die due to severe biventricular dysfunction, decompensated left ventricle, sepsis and stroke, rest 50 (98.03%) were normal no any focal neurological deficient went home uneventful. Some centre experience 0% mortality.

Immediate postoperative period most patients downgraded from the NYHA class III to class I and II, in our study 31 (60.78%) patients were found to be NYHA class I and 18(35.29%) patients were found to be NYHA class II and 2 (3.92%) patients remain as a class III at the time of the discharge. A total of 16 (31.37%) patients developed postoperative arrhythmia. And 35 (68.62%) do not have any post-operative arrhythmias. Patients with CHB will require PPI, and a total of 6(11.67%) patients required PPI, the rest 45 patients did not require PPI, and arrhythmias like atrial fibrillation etc. managed with beta-blockers and another antiarrhythmic drug. (Figure 1)

Regarding the mitral valve, in our study 4(7.84%) patients require mitral valve replacement intraoperative, and 47 (92.15%) patients had not required mitral valve replacement. In some patients moderate amount of mitral valve regurgitation resolved after septal myectomy. Though this patient did not require mitral valve replacement. (Table 3)

Follow up

At the one-year follow up most patients (33(66%)) remains in NYHA class I, 14 (28%) patients had NYHA class II, and 3(6%) patients had NYHA class III. These data show that most patient remains in NYHA class I

Patient get benefit from the septal myectomy mostly patients present with NYHA class III after extensive septal myectomy most patients change from NYHA class III to NYHA class I, II. P value for NYHA class II and III is 0.0004 and <0.0001 so data is statically significant. Patients got benefit from septal myectomy. (Table 4)

Generally, in HOCM all patients have good lv function, the presence of a high gradient between the lv and aorta due to hypertrophy of septal leaflet across the LVOT. In our patient minimum gradient across the LVOT is 80mm and maximum is around 160 mmHg, and the mean gradient is 107.12 mmHg. Interventricular septal thickness during systole min was 15mm and the maximum was 23mm and the mean was 19.01mm during diastole minimum septal wall thickness was 16mm, the maximum thickness is around 25mm and the mean was 21.03mm. In our study minimum posterior wall thickness was around 12mm, the maximum wall thickness was 17mm and the mean was 15.09mm.

The latest follow-up just before discharge 2d echocardiographic finding shows the gradient was reduced to just near normal, the mean was 10.58mmHg; the minimum gradient noticed across the LVOT was 2mmHg and in one patient noticed around 30mmHg. (Table 5).

Following the septal myectomy septal wall thickness reduced to near normal size average septal wall thickness reduced to 10.84mm during systole and 11.78mm during diastole, and

posterior wall thickness reduced to an average of 11.43mm. In our study, almost all patients have undergone adequate septal myectomy.

After one year of surgery, the 2d echo finding just similar to the finding at the time of discharge, mean gradient around 11.83mmHg, septal thickness around 11.45mm during systole and 12.49 mm during diastole and posterior wall thickness around 12.07mm there is no gross difference. (Table 6)

Preoperatively all patients have normal lv function, following septal myectomy, only 2 patients have EF <45%, following follow-up of 1 year three patient have EF <45%, one patient presents with left ventricular dysfunctions. Which is gradually improved with supportive medical therapy.

After septal myectomy Lv mass reduced due to the adequate resection. So the thickness of the septum during systole and diastole decreased and posterior wall thickness also reduce after myectomy. Due to the above resection gradient across the lvot also reduce. Statistical analysis of these variables shows the p-value for the lvot gradient, ivs size in systole and diastole and posterior wall thickness are less than 0.001 so data is statically significant. And the patient gets benefits from septal myectomy. (Table 7)

For all patients who underwent extensive septal myectomy, clinical symptoms improve with the surgical treatment. On follow-up of one year no patient presented with syncope, chest pain and new onset arrhythmias. 3(6%) patient presented with dyspnoea. Rest 47 patient did not have dyspnoea. One patient presented with severe left ventricular dysfunction. 2nd patient had the same symptoms at the time of discharge. He did not benefit from the myectomy. On and off he was admitted multiple times with dyspnoea, last 3rd patient was present with class III dyspnoea on evaluation, was diagnosed with viral pneumonitis.

Figure 1. NYHA Class Postoperative

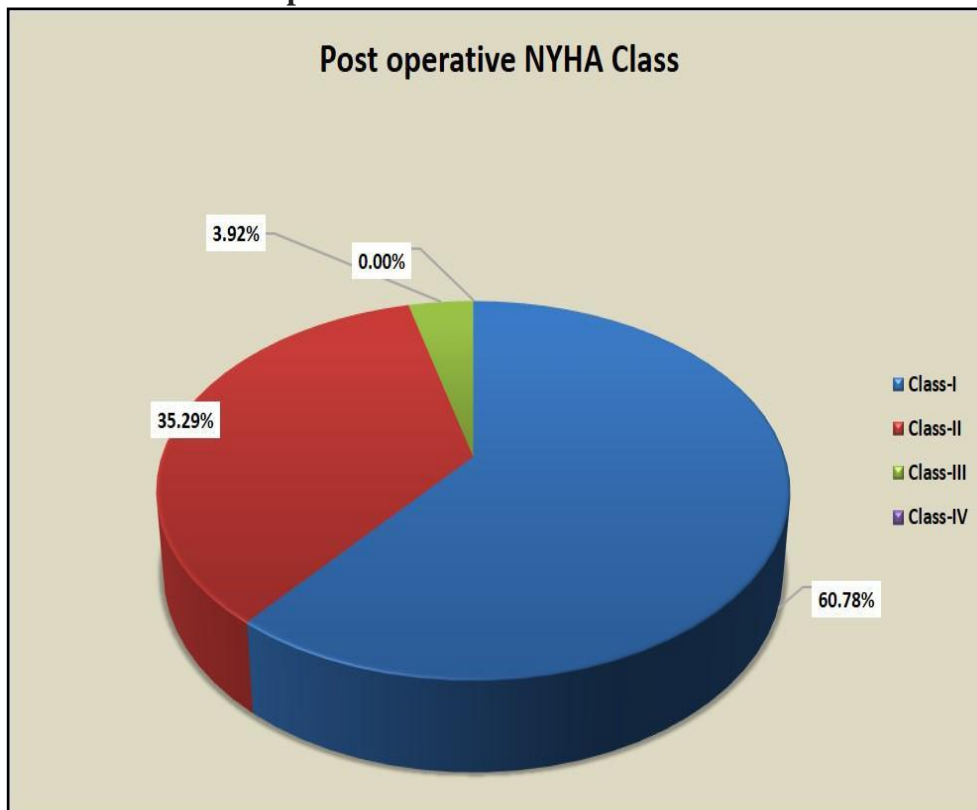


Figure 2. NYHA Class After 1 Year Follow Up

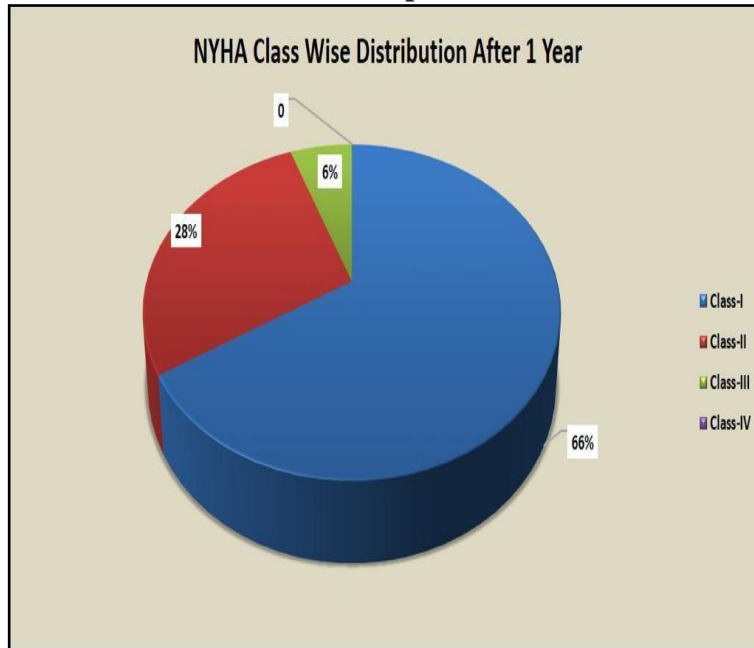


Table 1: Age Wise Distribution and Gender Distribution

Age(year)	No of patients
<21	9 (17.64%)
21-40	20 (39.21%)
41-60	18(35.29%)
>60	4 (7.84%)
Total	100%(n=51)
Mean Age	38.52 ± 16.90
Male	26 (50.98%)
Female	25 (49.01%)

Table 2: Dyspnoea and NYHA Class Distribution

Dyspnoea	Number
YES	46 (90.19%)
NO	5(9.80%)
TOTAL	51 (100%)
NYHA CLASS	Total patient
Class-I	1 (1.96%)
Class-II	2 (3.96%)
Class-III	47 (92.15%)
Class-IV	1 (1.96%)
TOTAL	51 (100%)

Table 3: Mitral Valve Replacement

MVR	NUMBER
YES	4 (7.84%)
NO	47(92.15%)
TOTAL	51 (100%)

Table 4: NYHA Class Differences

NYHA Class	Preoperative	Postoperative	1 Year Follow Up	P Value
I	01	31	33	<0.0001
II	02	18	14	0.0004
III	47	02	03	<0.0001
IV	01	00	00	0.3654

Table 5: Post Operative 2D Echo Finding.

Total (n=51)		Min	Max	Mean
LVOT Gradient		80(mmHg)	160(mmHg)	107.13(mmHg)
IVS	Systole	15mm	23mm	19.01mm
	Diastole	16mm	25mm	21.03mm
PW		12mm	17mm	15.09mm

Table 6: Post Operative 2D Echo Cardiography Finding After 1 Year.

Total(n=51)		Min	Max	Mean
LVOT Gradient		8mmHg	30mmHg	11.83mmHg
IVS	Systole	3mm	15mm	11.45mm
	Diastole	10mm	16mm	12.49mm
PW		10mm	15mm	12.07mm

Table 7: LVOT Gradient Comparison

	Preoperative	Postoperative	1 Year Follow Up	P Value
LVOT Gradient	107.13 ± 19.60	10.58 ± 5.50	11.86 ± 4.47	<0.001
IVS Systole	19.01 ± 2.65	10.84 ± 1.37	11.42 ± 1.73	<0.001
IVS Diastole	21.03 ± 2.56	11.78 ± 1.54	12.46 ± 1.45	<0.001
PW	15.09 ± 1.76	11.43 ± 1.08	12.06 ± 1.26	<0.001
EF	56.92 ± 4.85	53.43 ± 6.51	52.6 ± 8.09	0.0028

Discussion

The present study included 51 HOCM patients who were symptomatic and treated by septal myectomy in our hospital. Our results showed that septal myectomy significantly reduced LVOT obstruction, mitral regurgitation and HOCM-related symptoms. Cardiac function was increased by surgical treatment. Septal myectomy and adjunctive procedures could be efficacious and low-risk therapy in HOCM patients. It gives predictable, immediate, and durable remodelling of the LVOT which translates into long-term control of symptoms.

Left ventricular septal myectomy was first reported by Cleveland in 1963 and Morrow subsequently revealed the good clinical and hemodynamic outcomes of myectomy surgery.¹¹ Isolated septal myectomy could not diminish SAM of the mitral valve and relieve LVOT obstruction completely.¹² Marwick et al. reported that up to 20 % of patients with isolated septal myectomy were placed back on cardiopulmonary bypass because of inadequate resection.¹³

An inadequate length of septal excision was the most common reason for recurrent LVOT obstruction after myectomy. Extensive septal myectomy to the midventricular level, with or without shaving of the papillary muscles, could eliminate the LVOT gradient and SAM-induced mitral regurgitation.^{14,15}

Until now, limited data are addressing long-term outcomes of extensive septal myectomy in HOCM patients. Wang et al. showed that extensive septal myectomy provided excellent relief from LVOT obstruction (91.8 ± 25.1 to 14.3 ± 13.4 mmHg, $P < 0.05$) and satisfactory

clinical outcomes for 93 HOCM patients at early and mid-term follow-up. Their study showed that the 30-day and in-hospital mortality was 0 %. After surgery, limiting symptoms were decreased while physical abilities were increased.¹⁶

The surgical procedure itself has undergone various modifications, even though the procedure is still known by its founder Morrow. Refinements in surgical technique, myocardial protection, equipment, understanding pathophysiology, better post-operative care etc all brought down the mortality. Currently, the accepted mortality for the procedure is 1-1.5 %. But in high-volume centres, the mortality is almost approaching zero. Some centres have reported zero mortality for over five hundred cases. Further depths into the pathophysiology have shifted the focus from myectomy alone. Presently higher volume centres are trying for better outcomes in terms of Mitral valve replacement, CHB leading to PPI, and major adverse cardiovascular events.

Subaortic myectomy has become the gold standard to relieve the LVOTO and associated SAM. Myectomy is a safe and effective procedure even though mitral regurgitation, residual LVOTO, and SAM are still a problem in a minor group of patients post myectomy. Mitral valve replacement has been proposed by Cooley to solve these problems. But present-day surgeons are in favour of avoiding primary MVR for HOCM.

Our study results were quite fruitful, regarding the functional class majority of patients changed from FC 3,4 to FC 1 and 2, This corresponds to the decrease in post-op gradient. The minimum post-op gradient was 2 and the maximum was 30 with a mean of 10. The gradient was almost similar at the follow-up of 1 year. This significant reduction of gradient and enlargement of the LVOT translated into the improvement in functional class. Our results indicate that myectomy is an effective method for the treatment of HOCM.

Total LV mass decreases after myectomy and the reduction exceeds that of the septal mass, indirect evidence of the amelioration of pressure overload. There is an almost complete abolition of SAM with its associated LVOTO and MR. There was no case of syncope or recurring angina during the post-follow-up of 1 year.

The complications associated with the procedure were minimal, but it is statistically significant. 11.67% of patients required PPI following the procedure which amounted to a statistically significant. Almost 7.84% of patients required mitral valve replacement. The patient category was complicated with severe mitral regurgitation Majority of these patients had long-standing mitral regurgitations which did not respond to myectomy alone. In some patients, leaflets were beyond the scope of repair, in our study 10 had prolonged hospital stay out of which one dies due to severe decompensated left ventricular failure, and sepsis, and over mortality is 1.96%.

In our study, clinical improvement following myectomy was comparable among patients with rest, similar to previous surgical experiences. The symptoms of HOCM patients undergoing septal myectomy procedure in our study were relieved after the operation at the time of discharge and follow-up of one year. Echocardiography results by our study showed LVOT gradient and septal width of HOCM patients were significantly reduced whereas their LVID_d and EF were increased after surgery at the time of discharge and the one-year follow-up. Myectomy consistently reverses the heart failure process and usually returns patients to normal (or near-normal) activity levels and quality of life. Heart failure would have inevitably progressed to death and/or profound disability. By relieving gradient to outflow and normalizing LV pressures and mitral regurgitation, these data suggest that myectomy conveys a survival benefit. A small group of clinical non-responders to surgical myectomy were identified, defined as patients with persistent NYHA class 3 symptoms postoperatively despite surgical relief of the outflow gradient. The determinants of this clinical course remain incompletely resolved but may be due to the predominant role diastolic dysfunction plays in generating symptoms.

Limitations

The patient volume was low because of which the strength of the statistical analysis is low.

Conclusion

Septal myectomy and adjunctive procedures provide excellent relief of symptoms and improve cardiac function in HOCM patients in the early postoperative period and at 1-year follow-up. Pre-operative identification of risk factor, pre-operative optimisation and intra-operative adequate resection gives better symptomatic and echocardiographic outcome with the patient can perform the normal routine activity.

References

1. Maron BJ. Hypertrophic cardiomyopathy: a systematic review. *JAMA*. 2002 Mar 13;287(10):1308-20.
2. Brown ML, Schaff HV. Surgical management of obstructive hypertrophic cardiomyopathy: the gold standard. *Expert Rev Cardiovasc Ther*. 2008;6:715–22.
3. Kim M, Kim B, Choi YJ, Lee HJ, Lee H, Park JB, Lee SP, Han KD, Kim YJ, Kim HK. Sex differences in the prognosis of patients with hypertrophic cardiomyopathy. *Sci Rep*. 2021 Mar 1;11(1):4854.
4. Olivetto I, Maron MS, Adabag AS, Casey SA, Vargiu D, Link MS, Udelson JE, Cecchi F, Maron BJ. Gender-related differences in the clinical presentation and outcome of hypertrophic cardiomyopathy. *J Am Coll Cardiol*. 2005 Aug 2;46(3):480-7.
5. Alcalai R, Seidman JG, Seidman CE. Genetic basis of hypertrophic cardiomyopathy: from bench to the clinics. *J Cardiovasc Electrophysiol*. 2008 Jan;19(1):104-10.
6. Fernández-Ruiz I. Modulating myosin function to treat hypertrophic cardiomyopathy. *Nat Rev Cardiol*. 2019 Apr;16(4):201.
7. van Driel B, Nijenkamp L, Huurman R, Michels M, van der Velden J. Sex differences in hypertrophic cardiomyopathy: new insights. *Curr Opin Cardiol*. 2019 May;34(3):254-259.
8. Marrocco V, Bogomolovas J, Ehler E, Dos Remedios CG, Yu J, Gao C, Lange S. PKC and PKN in heart disease. *J Mol Cell Cardiol*. 2019 Mar;128:212-226.
9. Marc A. Raj; Sagar Ranka; Amandeep Goyal. P. Elliott, B. Anderson, E. Arbustini, et al., Classification of the cardiomyopathies: a position statement from the European Society of Cardiology Working Group on myocardial and pericardial diseases, *European Heart Journal* 29 (2008) 270–276.
10. Kouchoukos NT, Blackstone EH, Hanley FL, Kirklin JK. *Kirklin/Barratt-Boyes Cardiac Surgery E-Book*. Elsevier Health Sciences; 2012 Sep 27.
11. Sasson Z, Prieur T, Skrobik Y, Fulop JC, Williams WG, Henderson MA, Gresser C, Wigle ED, Rakowski H. Aortic regurgitation: a common complication after surgery for hypertrophic obstructive cardiomyopathy. *Journal of the American College of Cardiology*. 1989 Jan 1;13(1):63-7.
12. Marwick TH, Stewart WJ, Lever HM, Lytle BW, Rosenkranz ER, Duffy CI, Salcedo EE. Benefits of intraoperative echocardiography in the surgical management of hypertrophic cardiomyopathy. *Journal of the American College of Cardiology*. 1992 Nov 1;20(5):1066-72.
13. Cho YH, Quintana E, Schaff HV, Nishimura RA, Dearani JA, Abel MD, Ommen S. Residual and recurrent gradients after septal myectomy for hypertrophic cardiomyopathy—mechanisms of obstruction and outcomes of reoperation. *The Journal of Thoracic and Cardiovascular Surgery*. 2014 Sep 1;148(3):909-16.

14. Minakata K, Dearani JA, O’Leary PW, Danielson GK. Septal myectomy for obstructive hypertrophic cardiomyopathy in pediatric patients: early and late results. *The Annals of thoracic surgery*. 2005 Oct 1;80(4):1424-30.
15. Altarabsheh SE, Dearani JA, Burkhart HM, Schaff HV, Deo SV, Eidem BW, Ommen SR, Li Z, Ackerman MJ. The outcome of septal myectomy for obstructive hypertrophic cardiomyopathy in children and young adults. *The Annals of Thoracic Surgery*. 2013 Feb 1;95(2):663-9.
16. Wang S, Luo M, Sun H, Song Y, Yin C, Wang L, et al. A retrospective clinical study of transaortic extended septal myectomy for obstructive hypertrophic cardiomyopathy in China. *Eur J Cardiothorac Surg*. 2013; 43:534–40.