

## COMPARITIVE STUDY OF USG ,CT AND MRI IN ASSESSMENT OF BLUNT TRAUMA ABDOMEN

**AUTHORS – Dr. Ramani Ranjan Mund<sup>1</sup>,Dr. Santhosh kumar patro<sup>2</sup>, Dr. Bishwajyoti sahoo<sup>3</sup>,Dr. Preity Priyadarshini<sup>4</sup>,Dr.Suresh Amal Chand<sup>5</sup>**

<sup>1</sup>Associate Professor,Dept of General Surgery, MKCG MCH,Berhampur,Odisha

<sup>2</sup>Assistant Professor,Dept of General Surgery, MKCG MCH, Berhampur,Odisha

<sup>3</sup>Assistant Professor ,Dept of General Surgery, MKCG MCH,Berhampur,Odisha

<sup>4</sup>Junior Resident, Dept of General Surgery, MKCG MCH, Berhampur, Odisha

Corresponding Author – Dr suresh Amal Chand ,Junior Resident, Dept of General Surgery, MKCG MCH, Berhampur, Odisha. Mob – 9645421906.

Mail – [amalcculz@gmail.com](mailto:amalcculz@gmail.com)

**Key words:** Blunt trauma, MRI, CT, USG

### ABSTRACT

#### BACKGROUND

Blunt abdominal trauma may represent an immediate threat to life and requires rapid diagnosis and treatment. A diagnostic tool is required for assessment of abdominal injuries since clinical examination and physical examination is unreliable in most of the cases. The management of patients with blunt abdominal injury has evolved greatly over the last few decades. Major changes in the diagnostics of hemodynamically stable patients with blunt trauma have occurred. Major changes in the diagnostics of hemodynamically stable patients with blunt trauma have occurred. Magnetic resonance imaging (MRI), with the lack of radiation exposure and iodinated contrast material, is an attractive option for diagnosis in stable patient.

#### AIM AND OBJECTIVE

To compare the diagnostic efficacy of USG, CT and MRI of Abdomen in Blunt Abdominal Trauma in order to bring out the most effective diagnostic modality.

#### METHODOLOGY

The patients, satisfying the inclusion criteria, after clinical evaluation, were subjected to Abdominal X-ray, Ultrasonography, Computed Tomography and Magnetic Resonance Imaging and a report was obtained from the radiologist regarding the pathology associated. This was compared with the intra-operative finding during Exploratory Laparotomy Procedure. The data was collected in a pretested Case Record Proforma designed for the study and was assessed by appropriate statistical methods.

#### RESULTS AND CONCLUSION

Sensitivity, specificity, positive predictive value, negative predictive value and accuracy of USG was determined to be 73.68%, 96.43%, 96.55%, 72.97% and 83.33% respectively. In CT and MRI sensitivity was 85.53% and 96.05%, specificity was 96.43% and 98.21%, PPV

was 97.01% and 98.65%, NPV was 83.08% and 94.83% and accuracy was 90.15% and 96.97% respectively. Higher sensitivity and specificity along with greater accuracy was noted in MRI as compared to CT and USG.

## INTRODUCTION

Trauma is also called as an ‘unsolved epidemic’ in the present society. Death from cancer and cardiovascular disease together is almost equal to loss of life from trauma. Trauma is the common cause of death in people less than 40 years of age<sup>(1,2)</sup>. Traditionally, abdominal injuries can be divided into penetrating trauma and blunt trauma. Blunt abdominal trauma (BAT) usually occurs due to road traffic accidents (RTA), fall from heights or during sports<sup>(3)</sup>.

Blunt abdominal trauma may represent an immediate threat to life and requires rapid diagnosis and treatment. In the remaining patients, in whom there is no immediate threat to life, a correct diagnosis is paramount in the interest of timely institution of appropriate therapy<sup>(4,5)</sup>.

A diagnostic tool is required for assessment of abdominal injuries since clinical examination and physical examination is unreliable in most of the cases<sup>(6)</sup>. Previously available diagnostic techniques included plain radiography, contrast studies, angiography and scintigraphy. Diagnostic laparotomy used to play a prominent role, so much so that the popular surgical aphorism was “never let the abdominal wall stand between you and the diagnosis”<sup>(7)</sup>. Most of the patients with abdominal injuries can be conservatively managed<sup>(8)</sup> and laparotomy involves significant morbidity and mortality which has led to look for better alternatives.<sup>(9)</sup>

Diagnostic peritoneal lavage (DPL) introduced in 1965 by Root et al<sup>2</sup> was cheap and easily available technique and could be done safely and quickly even in emergency setting. The major disadvantage of DPL is its limitation in evaluating retroperitoneal organs like kidneys and pancreas which has led to additional method for diagnosis.<sup>(8)</sup>

CT is however relatively insensitive to early detection of intestinal, mesenteric and pancreatic injury. The need to shift a potentially unstable out of the trauma care area, the time required to prepare the patient, and limited availability are its main disadvantages.<sup>(9)</sup>

spleen, liver and kidney are the most commonly injured abdominal organs<sup>(10-12)</sup> as a result of blunt trauma and a missed splenic injury is the most common cause of preventable death in trauma patients<sup>(11)</sup>.

The management of patients with blunt abdominal injury has evolved greatly over the last few decades. Historically, surgical management was the preferential treatment for most blunt abdominal injury, because nonoperative management (NOM) was associated with a high mortality rate and significant risk of delayed rupture<sup>(13)</sup>. However, a significant amount of the laparotomies were non-therapeutic and therefore possibly unnecessary<sup>(14)</sup>.

Furthermore, as the severity of post splenectomy infection became better understood, a trend from splenectomy towards splenic conservation has emerged. Although initially controversial, NOM of patients with blunt abdominal injury is currently the treatment of

choice in hemodynamically stable patients<sup>(15,19)</sup> NOM can be divided in either observation (OBS) alone or angiography and embolization (AE) followed by close observation. Observational management involves admission to a unit with monitoring of vital signs, strict bed rest, frequent monitoring of haemoglobin concentration, and serial physical exams<sup>(20)</sup>

In 1995 Sclafam described the first successful use of angiography and embolization in a patient with splenic injury<sup>(21)</sup> Many studies support the use of embolization as an adjunct to observation. AE has increased the success rate of nonoperative management both by stopping ongoing bleeding as well as by preventing delayed rupture<sup>(22,26)</sup>. Success rates up to 97% are described in the literature. Improved imaging techniques and advances in interventional radiology have helped to better differentiate patients who can be observed versus those needing AE. However, a lot of issues regarding the diagnostics and therapeutic management of patients with blunt abdominal injuries after trauma are still debated. abdominal trauma/28' In general, FAST examination has replaced the use of DPL, because DPL is an invasive procedure and provides no information about which organ is injured, resulting in a high rate of negative or non-therapeutic laparotomies<sup>(29)</sup>

FAST is useful in trauma evaluation to identify intra-abdominal fluid, a herald of significant organ injury, with a sensitivity of 90-93%<sup>(30,31)</sup>. FAST can be performed simultaneously with resuscitation efforts during the initial trauma management and can be completed rapidly and is, therefore, also useful in hemodynamically unstable patients<sup>(32)</sup> One of the strengths of FAST in this patient group is that it helps to direct the surgeon to the abdomen as a major source of blood loss when positive, thereby leading to early laparotomy rather than Computed tomography (CT).

Despite its efficacy and non-invasive character, FAST has several important disadvantages. First, FAST does not accurately detect the extent (grade) or the exact site of the organ injury. Hemoperitoneum detected with FAST in hemodynamically stable patients should be followed by a CT scan to evaluate the nature and extent of injury in more detail<sup>(33)</sup>. Second, its sensitivity for direct demonstration of blunt abdominal injury is relatively low (between 34% and 55%), since the presence of free fluid in sufficient quantity indirectly indicates intraperitoneal injury<sup>(34)</sup>. Other limitations of FAST include operator-dependence, limited retroperitoneal accuracy and poor scanning results in obese patients or patients with overlying wounds.

When the FAST is negative for hemoperitoneum, it is still debatable whether a CT scan is required. Estimates for the presence of intra-abdominal injury in the absence of hemoperitoneum on FAST can be as high as 29%<sup>(35)</sup>. In a recent study, 13% of the patients with clinical signs of abdominal injury and a negative FAST for intra-abdominal fluid were shown to have significant injury upon CT scanning<sup>(36)</sup>. Therefore, hemodynamically stable patients with a negative FAST and a high clinical suspicion of splenic injury, for example a seat belt sign or upper abdominal pain, should undergo routine CT scanning.<sup>(37,38)</sup>

An increase in the utilisation of another radiological modality, the Contrast Enhanced Ultra-sound (CEUS) could contribute to the shift towards NOM. CEUS is a real-life, non-invasive, bedside, radiation free technique. Some studies suggest that CEUS is a good

alternative to CT scanning for the evaluation of traumatic lesions in solid abdominal organs, especially in patients with contraindications for CT contrast agents and in hemodynamically compromised patients<sup>(39)</sup>. The exact place of CEUS in the diagnostics of patients with blunt abdominal injury should be further determined in the future.

The introduction of helical tomography in the 1980s has improved the detection and classification of blunt abdominal injury<sup>(40)</sup>. Currently, Multidetector Computed Tomography scanning with intravenous contrast is the gold standard diagnostic modality in hemodynamically stable patients with intra-abdominal fluid detected with FAST. CT scanning with intravenous contrast has numerous advantages. First, the detection of injuries related to the liver, spleen and kidney can be reliably determined, with a sensitivity of 90-100%. Second, active bleeding (a contrast extravasation), pseudo aneurysms and post traumatic arteriovenous fistulas can be diagnosed and the localisation of these vascular injuries can also be established. Third, the CT scan plays a decisive part in the order of treatment if more than one injury is present<sup>(41)</sup>.

Because of the technical developments which have resulted in a higher degree of resolution of the CT scan and in quicker scanning, the effectiveness of conventional radiology (X-rays and FAST) in the clinical ATLS approach has been challenged. One of the main reasons for this is the lack of any research which prove that the mortality and disability rates of injured patients decreases after the implementation of the ATLS concept<sup>(42)</sup>. One of the current discussions in literature is whether a whole body CT survey should be implemented in the primary survey. Some authors recommend conducting a whole body CT (the so-called imaging survey) as the standard diagnostic tool during the early resuscitation phase for patients with polytrauma. They report that a CT scan of the chest or abdomen results in a change of treatment in up to 34% of patients with blunt trauma<sup>(43)</sup>. A 30% reduction in mortality using the whole body CT is also reported<sup>44</sup>. Other arguments in favour of an imaging survey are the reduction in time from admission to intervention and the possibility of managing hemodynamically unstable patients in the same way<sup>(45)</sup>.

It is debatable whether a whole body CT survey is to be recommended considering its disadvantages. The need for iodine containing contrast and the radiation exposure, especially in the relatively young trauma population, are not negligible when one considers the lifetime risk of cancer<sup>(46)</sup>. Moreover, whole body CT as part of the primary survey can only be adopted if a CT scan is available in, or very close to, the emergency department<sup>(47)</sup>. For the moment the benefit of whole body CT scanning seems particularly high for patients with severe injury.

Magnetic resonance imaging (MRI), with the lack of radiation exposure and iodinated contrast material, is an attractive option for diagnosis. However, lengthy imaging times and limited widespread availability have previously precluded the utilization of MRI in the workup of trauma patients<sup>(48,49)</sup>. MRI with coronal imaging has been used to evaluate the integrity of the diaphragm in cases of suspected diaphragmatic rupture<sup>48,49</sup>. There have been case reports describing the use of MRI

Over the past 40 years, many changes in the primary survey and treatment of patients with blunt abdominal trauma have occurred. Traditionally, emergency laparotomy was the standard of care. Before the 1970s, the structure of the diagnosis and treatment of life-threatening injury was very dependent upon the physician. The turning point of this management style came with the introduction of the Advanced Trauma Life Support (ATLS) principles by Steiner and Collicott in 1978<sup>(27)</sup>. With this ATLS protocol, a clear guideline for the optimal primary clinical survey of patients with life-threatening injury was developed. The goal of the primary survey is to quickly assess and stabilize the trauma patient. Structure, simplicity and a multidisciplinary methodology are essential to this approach. An important ATLS principle is: ‘treat first what kills first’.

Major changes in the diagnostics of hemodynamically stable patients with blunt trauma have occurred. Currently, the primary survey consists of a chest X-ray, X-rays of the cervical spine and pelvis, blood and urine samples and a Focussed Assessment with Sonography for Trauma (FAST).

Formerly, diagnostic peritoneal lavage (DPL) was the procedure of choice for the quick diagnosis of a hemoperitoneum in patients with blunt abdominal trauma. DPL, first described in 1965, resulted in a decrease in mortality and morbidity following in diagnosis of both renal and pancreatic injuries following trauma<sup>(50,51)</sup>. Two additional studies have compared CT and MRI in the diagnosis of abdominal solid organ injury<sup>(52,53)</sup>.

Fulcher et al and McGehee et al opined that, MRI, although safer in most regards than CT, has experienced limited utility in the trauma patient due to availability concerns, prolonged imaging times and difficulty associated with patient monitoring. Technological advances have brought about the widespread availability of MRI and have significantly shortened imaging times while finding creative ways to better monitor patients. With these improvements MRI can be used as a valid alternative in the workup of stable patients with contraindication to CT in setting of blunt abdominal trauma<sup>(52,53)</sup>.

Trauma is the leading cause of death among people who are younger than 45 years<sup>(54)</sup>. One of the main causes of death after trauma, with numbers ranging from 40 to 80%, is exsanguination caused by injuries to the abdominal organs. The spleen and liver are the most commonly injured organs as a result of blunt trauma. The kidney is also commonly injured<sup>(55)</sup>. American Association for the Surgery of Trauma (AAST) has devised a set of organ injury grading scales to assess the amount and severity of injury of all organs<sup>(56)</sup>.

With this background, the present study was designed to evaluate the diagnostic efficacy of USG, CT and MRI in cases of blunt trauma abdomen in Southern Odisha.

### **AIMS & OBJECTIVES**

To compare the diagnostic efficacy of USG, CT and MRI of Abdomen in Blunt Abdominal Trauma in order to bring out the most effective diagnostic modality.

## **MATERIALS AND METHODS**

### **STUDY POPULATION**

The patients admitted consecutively, in Dept, of General Surgery, M.K.C.G. Medical College Hospital, Berhampur with a clinical diagnosis of Blunt Abdominal Trauma from August 2020 to July 2022 included in the study, who underwent Exploratory Laparotomy.

### **SAMPLE SIZE**

Total of 66 cases

### **INCLUSION CRITERIA**

Patients of all age groups and both sexes; with history of Blunt Abdominal Trauma, admitted to Dept, of General Surgery, M.K.C.G. Medical College Hospital, Berhampur; underwent Exploratory Laparotomy, were included.

### **EXCLUSION CRITERIA**

- Patients refusing to participate in the study.
- Patients not requiring Surgical intervention.
- Patients having contraindication to CT (Radiation Hazard) and MRI (Claustrophobia, Cardiac Pacemakers, Metallic Implants and other metallic foreign bodies).
- Patients having history of allergy / anaphylaxis to contrast agents.
- Pregnancy.
- Clinically unstable patients.

### **METHOD OF DATA COLLECTION**

- The patients, satisfying the inclusion criteria, after clinical evaluation, were subjected to Abdominal X-ray, Ultrasonography, Computed Tomography and Magnetic Resonance Imaging and a report was obtained from the radiologist regarding the pathology associated. This was compared with the intra-operative finding during Exploratory Laparotomy Procedure. The data was collected in a pretested Case Record Proforma designed for the study and was assessed by appropriate statistical methods.
- Sixty six patients who were stable to undergo US, CT and MRI had positive findings were subjected for the study. Whenever possible, US preceded CT and MRI, the time gap between the two was kept to the minimum to make the studies comparable. US, CECT and MRI were done in all 66 patients. Patients having the tests interpreted as negative and who either did not require admission or who were discharged after short observation without any further investigation, were not included. Diagnostic peritoneal tapping was performed in all the patients with free fluid to confirm the presence of hemoperitoneum.

### **Ultrasonography**

- US scans were performed on “Wipro GE-LogiqS8®” machine, with 2-5 and 5-10 Mhz curvilinear and linear probes. Particular attention was paid in assessing free fluid in abdomen and evaluation of solid organs.

**CT Technique**

- CT scans were performed on “Wipro GE-Revolution EVO 128 Slice®” helical sub second (0.75 Sec) scanner capable of 50 secs, continuous spiral run. Images were reconstructed with 180° linear interpolation reconstruction algorithm. Helical CT of the entire abdomen was done from the level of dome of diaphragm up to the inferior aspect of ischium.

**Contrast Material**

- Routine oral contrast was not given to the patients. All patients received IV contrast material administered with an automated Medrad Power Injector after the initial pilot scan via a large-bore (18-20 G) peripheral venous line. A total of 100ml, 60% nonionic iodinated contrast was given intravenously at a rate of 2-4 ml per second. Scanning was initiated 70-90 secs after initiation of contrast infusion. Free fluid with attenuation value > 30 Hounsfield Units (HU) was labelled as hemoperitoneum. Follow up US or CT scans were obtained as dictated by the clinical course of the patients. Patients undergoing conservative management were clinically followed up. Surgical findings were noted from the operative notes in those undergoing laparotomy.

**MRI Technique**

MRI was performed using Cura Magna Momentum®, 1.5T. T1-weighted and T2-weighted spin echo sequences were obtained in all patients. Gradient-recalled echo (GRE) sequences (22-25/12-13/60 degrees flip angle) were obtained.

- Injury to different organs was staged by organ injury scaling (OIS) system developed by Organ Injury Scaling Committee of the American Association for the Surgery of Trauma (AAST), Moore et al.

**OBSERVATIONS AND RESULTS**

Sixty-six patients of either gender with history of blunt abdominal trauma attending Department of General Surgery with assistance from the Dept, of Radio-Diagnosis in M.K.C.G. Medical College and Hospital, Berhampur, from August 2020 to July 2022; formed study population.

**Observations and results were analysed and compiled as following:**

**Table 1: Frequency distribution of gender**

Gender	No. of patients (N)	Percentage (%)
Male	47	71.2
Female	19	28.8
<b>Total</b>	<b>66</b>	<b>100</b>

In our study male predominance was seen. Males receiving blunt abdominal trauma were 47 (71.2%) while that of females were 19 (28.8%). Male to female ratio was 2.47:1.

**Table 2: Frequency distribution based on age groups of patients studied**

Age groups (Years)	No. of patients (N)	Percentage (%)
<20	3	4.5
21-30	8	12.1
31-40	19	28.8

41-50	15	22.7
51-60	11	16.7
61-70	6	9.1
>70	4	6.1
<b>Total</b>	<b>66</b>	<b>100</b>
<b>Min-Max- 18-75 years old</b>		<b>Mean <math>\pm</math> SD- 43.94 <math>\pm</math> 14.5</b>

Out of 66 patients studied, majority belonged to age group 31 to 40 and 41 to 50 years old (19 cases, 28.8% and 15 cases, 22.7%); followed by 11 patients (16.7%) from age group 51 to 60 years old. Three (4.5%) patient, 8 (12.1%) patients, 6 (9.1%) patients and 4 (6.1%) patients were seen in age groups less than 20 years old, 21 to 30 years old, 61 to 70 years old and more than 70 years old respectively. Youngest patient enrolled was 18 years old male while oldest one was 75 years old male and one female. Mean age was to be  $43.94 \pm 14.5$  years.

**Table 3: Frequency distribution of modes of injury**

Mode of injury	No. of patients (N)	Percentage (%)
Assault	9	13.6
Bull gore injury	2	3.1
Fall from height	15	22.7
Occupation related	4	6.1
Road traffic accident	36	54.5
<b>Total</b>	<b>66</b>	<b>100</b>

Road traffic accidents were major means of injury in our study (36 cases, 54.5%); followed by fall from height type of injury (15 cases, 22.7%). Assault in 9 patients (13.6%), bull gore injury in 2 patients (3.1%) and occupation related injury in 4 patients (6.1%) was source of blunt abdominal trauma.

**Table 4: Frequency distribution of symptoms/clinical presentation**

Symptoms	No. of patients (N)	Percentage (%)
Abdominal pain	52	78.8
Abdominal tenderness	50	75.8
Guarding	24	36.4
Abdominal distension	20	30.3
Rebound tenderness	27	40.9
Absent bowel sounds	18	27.3
Hematuria	3	4.5
Per rectal bleeding	4	6.1
Vomiting	22	33.3

Majority of patients complained of abdominal pain (52 cases, 78.8%). Abdominal tenderness was seen in 50 patients (75.8%), abdominal guarding in 24 patients (36.4%),



abdominal distension in 20 patients (30.3%) and rebound tenderness in 27 patients (40.9%). Bowel sounds were absent in 18 patients (27.3%). Twenty two patients (33.3%) complained of vomiting. Hematuria and per rectal bleed was noted in 3 (4.5%) and 4 (6.1%) patients respectively.

**Table 5: Frequency distribution of X-ray findings**

X-ray findings	No. of patients (N=66)	Percentage (%)
Pneumoperitoneum	31	46.9
Peritoneal collection	14	21.2

On X ray, pneumoperitoneum was seen in 31 patients (46.9%) and peritoneal collection was seen in 14 patients (21.2%)

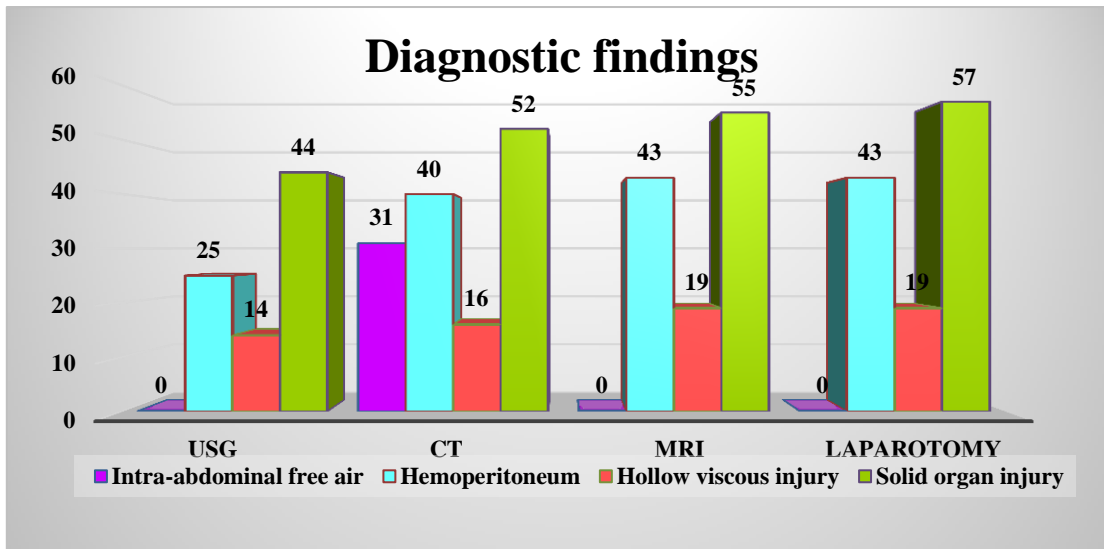
**Table 6: Frequency distribution of findings of USG, CT, MRI and exploratory laparotomy**

Findings	USG	CT	MRI	Laparotomy
Intra-abdominal free air	-	31 (46.9%)	-	-
Hemoperitoneum	25 (37.9%)	40 (60.6%)	43 (65.2%)	43 (65.2%)
Hollow viscous injury	14 (21.2%)	16 (24.2%)	19 (28.8%)	19 (28.8%)
Solid organ injury	44 (66.7%)	52 (78.8%)	55 (83.3%)	57 (86.4%)

Ultrasound was done in all patients to rule out differential diagnosis. Hemoperitoneum, hollow viscous injuries and solid organ injuries were seen in 25 (37.9%), 14 (21.2%) and 44 (66.7%) patients respectively.

CT scan was also done in all the patients. Intra-abdominal free air indicating perforation was noted in 31 (46.9%) patients. In CT findings hemoperitoneum, hollow viscous injuries and solid organ injuries were seen in 40 (60.6%), 16 (24.2%) and 52 (78.8%) patients respectively.

Magnetic resonance imaging revealed hemoperitoneum, hollow viscous injuries and solid organ injuries in 43 (65.2%), 19 (28.8%) and 55 (83.3%) patients respectively. Exploratory laparotomy was done in all patients and its findings were considered as gold standard for evaluation of other diagnostic modalities. Laparotomy revealed hemoperitoneum, hollow viscous injuries and solid organ injuries in 43 (65.2%), 19 (28.8%) and 57 (86.4%) patients respectively.

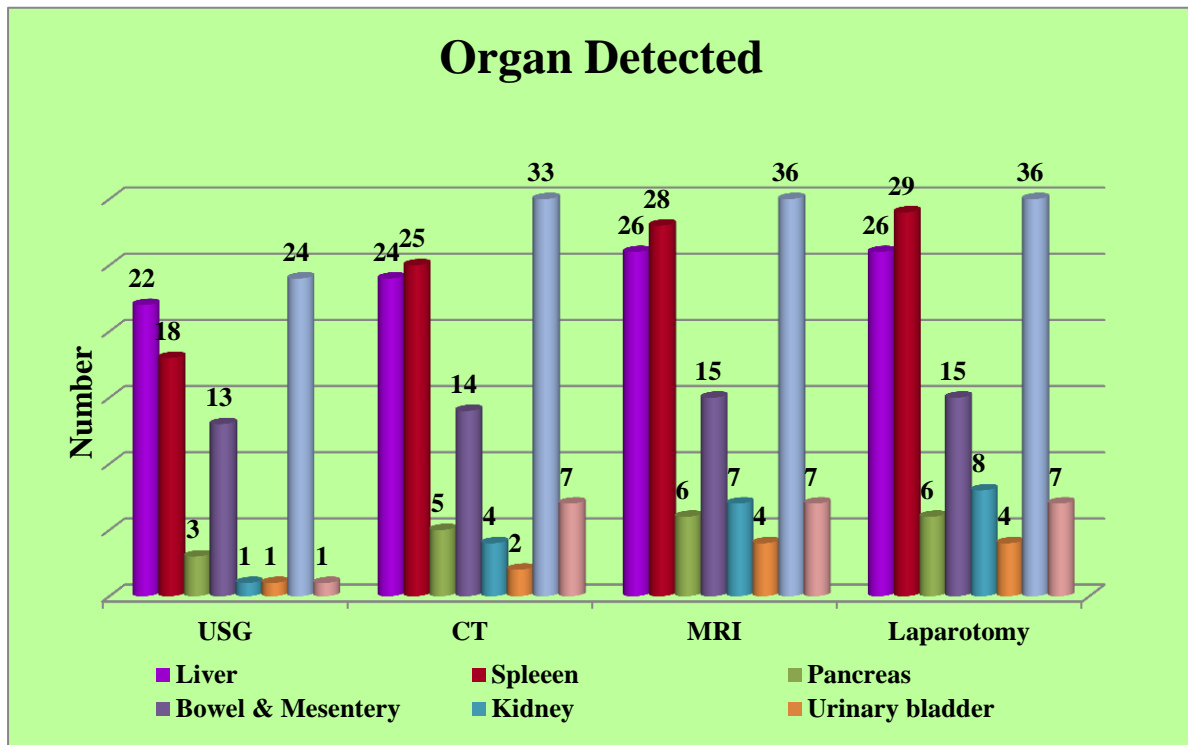


**Figure 1: Frequency distribution of findings of USG, CT, MRI and exploratory laparotomy.**

**Table 7: Frequency distribution of viscera affected based on USG, CT, MRI and exploratory laparotomy.**

Organ detected	USG	CT	MRI	Laparotomy
Liver	22	24	26	26
Spleen	18	25	28	29
Pancreas	3	5	6	6
Bowel and mesentery	13	14	15	15
Kidney	1	4	7	8
Urinary bladder	1	2	4	4
Hemoperitoneum	24	33	36	36
Retro-peritoneal haemorrhage	1	7	7	7

Liver and splenic lacerations were noticed on USG (22 and 18), CT (24 and 25), MRI (26 and 28) and laparotomy (26 and 29). Pancreatic lacerations were seen in 3 patients on USG, 5 patients on CT and 6 patients on MRI and laparotomy. Kidney lacerations were visible on USG (1), CT (4), MRI (7) and laparotomy (8). Bladder wall injury was seen on USG (1), CT (2) and MRI and laparotomy (4 cases each). Injury and lacerations on bowel and mesentery was present in 13 patients on USG, 14 patients on CT and 15 patients on MRI and laparotomy. Hemoperitoneum and retroperitoneal haemorrhages were observed on USG (24 and 1), CT (33 and 7) and MRI and laparotomy (36 and 7).

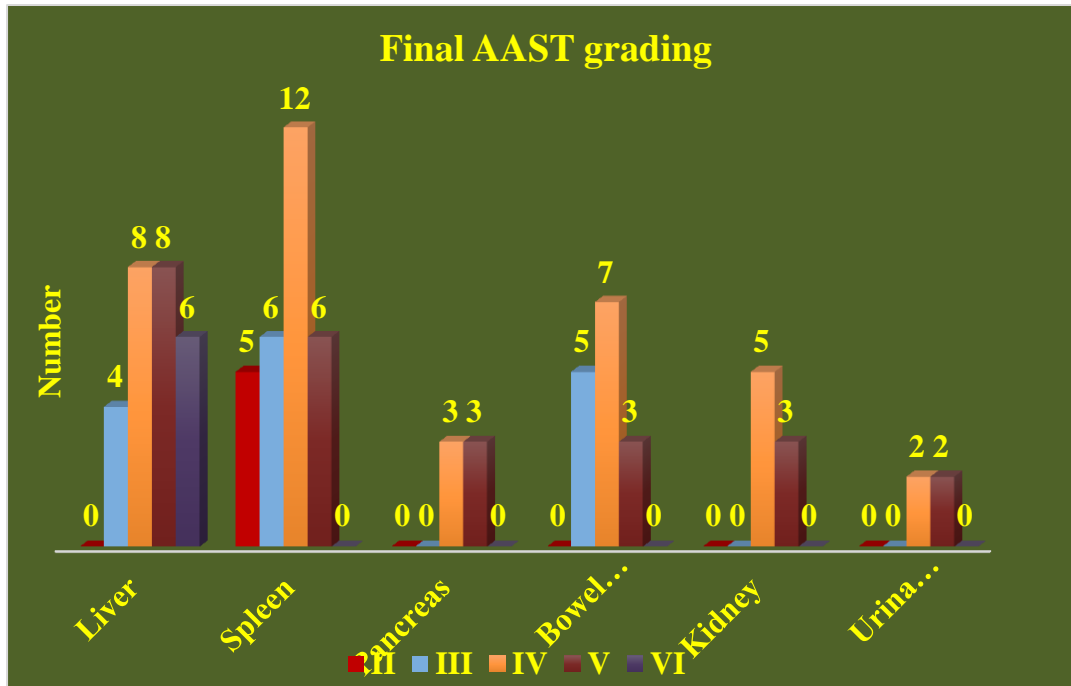


**Figure 2: Frequency distribution of viscera affected based on USG, CT, MRI and exploratory laparotomy**

**Table 8: Frequency distribution of final AAST grading of injury**

Organ injured	I	II	III	IV	V	VI
Liver	0	0	4	8	8	6
Spleen	0	5	6	12	6	-
Pancreas	0	0	0	3	3	-
Bowel and mesentery	0	0	5	7	3	-
Kidney	0	0	0	5	3	-
Urinary bladder	0	0	0	2	2	-

The American Association for the Surgery of Trauma (AAST) injury scoring system was used to grade injuries sustained by patients. None of the patients received grade I injury to any organ. Grade III, IV, V and VI liver injury was seen in 4, 8, 8 and 6 patients respectively. Similarly; grade II, III, IV and V splenic injuries were noted in 5, 6, 12 and 6 patients respectively. In three patients each grade IV and V pancreatic injuries were noticed. Bowel and mesenteric lacerations of grade III (5), grade IV (7) and grade V (3) were seen. Grade IV and V kidney injuries were seen in 5 and 3 patients respectively. And, in two patients each urinary bladder injury of grade IV and V was observed.



**Figure 3: Frequency distribution of final AAST grading**

**Table 9: Frequency distribution of site of injury**

Site of injury	No. of patients (N)	Percentage (%)
Liver	26	39.4
Spleen	29	43.9
Kidneys	8	12.1
Pancreas	6	9.1
Bowel and mesentery	15	22.7
Urinary bladder	4	6.1

Site of injury in majority of patients was found to be spleen (29 patients, 32.9%); followed by liver (26 patients, 29.5%). Injury to kidney, pancreas, bowel and mesentery and urinary bladder was seen in 8 (9.1%), 6 (6.8%), 15 (17%) and 4 (4.5%) patients respectively. In total 88 visceral organ were found to be affected following blunt abdominal trauma. Hemoperitoneum and retro peritoneal haemorrhages were seen in 36 and 7 patients respectively

**Table 10: Distribution of correlation between findings of USG, CT and MRI as compared to exploratory laparotomy**

Diagnostic modality		Intra-abdominal injury +ve	Intra-abdominal injury -ve
USG	Positive	56	2
	Negative	20	54
CT	Positive	65	2
	Negative	11	54
MRI	Positive	73	1
	Negative	3	55

In our study, USG, CT and MRI was done in all patients. Out of 88 organ injuries, 56, 65 and 73 hollow viscous and solid organ injuries were correctly diagnosed using USG, CT and MRI respectively. False negative intra-abdominal injuries were noted in USG (20), CT (11) and MRI (3). Also, false positive injuries were observed in USG (2), CT (2) and MRI (1).

**Table 11: Diagnostic efficacy of various modalities used to diagnose blunt abdominal trauma with respect to exploratory laparotomy as gold standard**

	Sensitivity %	Specificity %	PPV %	NPV %	Accuracy %
<b>USG</b>	73.68	96.43	96.55	72.97	83.33
<b>CT</b>	85.53	96.43	97.01	83.08	90.15
<b>MRI</b>	96.05	98.21	98.65	94.83	96.97

Findings of exploratory laparotomy were considered as final and gold standard for comparison of other diagnostic methods viz. USG, CT and MRI.

Sensitivity, specificity, positive predictive value, negative predictive value and accuracy of USG was determined to be 73.68%, 96.43%, 96.55%, 72.97% and 83.33% respectively. In CT and MRI sensitivity was 85.53% and 96.05%, specificity was 96.43% and 98.21%, PPV was 97.01% and 98.65%, NPV was 83.08% and 94.83% and accuracy was 90.15% and 96.97% respectively.

Higher sensitivity and specificity along with greater accuracy was noted in MRI as compared to CT and USG.

## DISCUSSION

Blunt abdominal trauma (BAT) usually occurs due to road traffic accidents (RTA), fall from heights or during sports. Prevalence of intraabdominal injury (IAI) varies widely, ranging from 7.7% to 65%/72\* The Indian fatality rates for trauma are 20 times that for developed countries. About 30% of such deaths are thought to be preventable.<sup>(57)</sup>

Isolated blunt abdominal trauma (BAT) represents about 5% of annual trauma mortality from blunt trauma. As part of multiple-site injury (polytrauma), BAT contributes another 15% of trauma mortality. In the abdominal trauma, the best exploration strategy is one that leads most quickly and reliably in the diagnosis of surgical injury.

Trauma accounts for one of the reason for majority of deaths in people younger than 45 years of age and is also a preventable cause of death. The loss of years of life due to trauma is more than combined years of life loss of malignancy, heart disease and stroke combined. The energy impacted during a blunt trauma is distributed over a wide area compared with penetrating injuries and the forces involved during the impact create both shear and tensile strain. Examples for these include falls, automobile and motor vehicle accidents and sports related injuries<sup>(58)</sup> Pain, subtle physical signs, and masked by intoxication and head injury appears to be main reasons in case of missing abdominal injuries in cases of blunt abdominal trauma. Clinical diagnosis in blunt injuries is a challenging task to the surgeon or physician due to lack of specific findings in these high velocity injuries<sup>(59)</sup>

The likelihood of injury to an individual organ depends upon the impact of velocity and mechanism of trauma and also the vulnerability of the patient at the time of the event. In

most of the literature reports, liver and spleen are the most common organs affected. Other organ which may be at risk includes kidneys, bowel, mesentery, pancreas, adrenals, and diaphragm and intra-abdominal vessels. Hemodynamically stable patients and patients who respond to initial management often require further diagnostic evaluation<sup>(60)</sup>

Diagnostic laparotomy used to play a prominent role, so much so that the popular surgical aphorism was “never let the abdominal wall stand between you and the diagnosis”<sup>(77)</sup> Most of the patients with abdominal injuries can be conservatively managed and laparotomy involves significant morbidity and mortality which has led to look for better alternatives<sup>(61)</sup>

Ultra sonogram (US) of the abdomen appears to be a useful and important tool in diagnosis of any kind of injury to the abdominal organs due to BAT. But an important hindrance factor previously was resolution and only 50% specificity in solid organ injuries<sup>(62)</sup>

Computed tomography has become the choice in advanced trauma centres as a primary modality of investigation in cases with BAT. CT evaluates retro peritoneum and abdomen with an additional advantage in also assessing the functional status of organs and skeletal injuries. Most of the reports and findings from various studies demonstrated CT as a better diagnostic choice than US in cases of BAT.

Disadvantages to CT include exposure to radiation and the need for iodinated contrast material with associated nephrotoxicity and allergic reactions. Magnetic resonance imaging (MRI), with the lack of radiation exposure and iodinated contrast material, is an attractive option for diagnosis. However, lengthy imaging times and limited widespread availability have previously precluded the utilization of MRI in the workup of trauma patients.

The variable scope, sensitivity, accuracy and advantages of these extensively used modalities has given rise to their variable use in different parts of the world<sup>(63)</sup> Present study was conducted with an aim to evaluate the diagnostic efficacy of USG, CT and MRI in cases of blunt trauma abdomen in Southern Odisha.

In present study, 60 cases with blunt abdominal trauma were included. The prevalence of BAT was more in males (71.2%) with male to female ratio was 2.47:1 as reported in earlier studies. Sanjay B et al<sup>(64)</sup> reported trauma in 77% cases which is little higher than our finding while Reddy et al<sup>(65)</sup> observed BAT in 67.15% with male to female ratio on 2.04:1. Mean age observed was  $43.94 \pm 14.5$  years with majority of cases belonging to 31 to 50 years (51.5%). This age is the highly vulnerable group as they are more actively involved in works externally and also in motor traffic accidents<sup>(66)</sup> Majority patients were free of comorbidities (71.2%). 54.5% of cases had BAT due to road traffic accident, followed by fall from height in 22.7% as reported in the findings of Mohapatra et al<sup>(67)</sup> who reported the incidence of RTA as 54% and Kulkarni et al who reported as 64% which is higher than our study<sup>(68)</sup> In Sanjay B et al<sup>(64)</sup> study RTA accounted for 77.4% of in injuries and 19.3% of patients sustained injuries due to fall from height.

Abdominal pain (78.8%) was the most common symptom in our study as also reported by Farahmand et al<sup>(69)</sup> in his study. In our study, tenderness (75.8%) was the most common clinical sign with other signs like guarding (36.4%), rebound tenderness (40.9%). However few studies reported that guarding, Hypotension and rebound tenderness were the common findings in cases of BAT. This is explained by the reason that signs depend upon the

type of injury and shear tensile strength which caused the injury and type of injury which can be organ parenchymal damage, hemoperitoneum or major organ injury. Reddy et al<sup>(65)</sup> also found the similar results with 100% cases with abdominal pain and tenderness followed by nausea, vomiting and abdominal fullness.

Abdominal pain (78.8%) was the most common symptom in our study as also reported by Farahmand et al<sup>(69)</sup> in his study. In our study, tenderness (75.8%) was the most common clinical sign with other signs like guarding (36.4%), rebound tenderness (40.9%). However few studies reported that guarding, Hypotension and rebound tenderness were the common findings in cases of BAT. This is explained by the reason that signs depend upon the type of injury and shear tensile strength which caused the injury and type of injury which can be organ parenchymal damage, hemoperitoneum or major organ injury. Reddy et al<sup>(65)</sup> also found the similar results with 100% cases with abdominal pain and tenderness followed by nausea, vomiting and abdominal fullness. suggests a higher likelihood of blunt injuries to the bowel. In addition, free intraperitoneal air, or trapped retroperitoneal air from duodenal perforation, may be seen.

On X-ray, pneumoperitoneum was seen in 31 patients (46.9%) and peritoneal collection was seen in 14 patients (21.2%). In Sanjay B et al<sup>(64)</sup> study, of the total 40 patients, free intraperitoneal air under the diaphragm was seen in 2 patients on abdominal radiograph. Pneumoperitoneum does not always indicate bowel rupture and can be observed in patients with pneumomediastinum or pneumothorax and in patients on mechanical ventilation.

Organ injury can be easily diagnosed by abdominal ultrasound as well as the presence of free intra-abdominal fluid, which could be blood or intestinal secretions. US is cheap, easily available, portable, non-invasive, with no radiation and is done in the emergency unit at the same time with resuscitation methods. On US examination, hemoperitoneum, hollow viscous injuries and solid organ injuries were seen in 25 (37.9%), 14 (21.2%) and 44 (66.7%) patients respectively.

On CT intra-abdominal free air was diagnosed in 46.9% and hemoperitoneum, hollow viscous injuries and solid organ injuries were seen in 40 (60.6%), 16 (24.2%) and 52 (78.8%) patients respectively. MRI revealed hemoperitoneum, hollow viscous injuries and solid organ injuries in 43 (65.2%), 19 (28.8%) and 55 (83.3%) patients respectively. These findings were confirmed on laparotomy. On exploratory laparotomy hemoperitoneum, hollow viscous injuries and solid organ injuries were diagnosed in 43 (65.2%), 19 (28.8%) and 57 (86.4%) patients respectively. Out of 88 organ injuries, 56, 65 and 73 hollow viscous and solid organ injuries were correctly diagnosed using USG, CT and MRI respectively. 20, 11 and 3 false negative intra-abdominal injuries were noted in USG, CT and MRI. Also, false positive injuries were observed in USG (2), CT (2) and MRI (1).

Splenic injuries account for about 40% of all intra-abdominal injuries 49. The presence of pulp tissue and poorly developed mesenchymal supporting structure predisposes spleen to injury. In our study spleen was the commonest organ injured with an incidence of 43.9%. Liver was the second most frequently injured organ in our study with an incidence of 39.4%. Least injured organ was urinary bladder with 6.1%. Pancreatic injury was found in 6 cases. Hemoperitoneum and retro peritoneal haemorrhages were seen in 36 and 7 patients respectively. These injuries were diagnosed on USG, CT and MRI and compared with the

exploratory laparotomy. On USG, CT and MRI, of 26 liver injuries 22, 24 and 26 were diagnosed correctly. Of 29 splenic injuries, 18, 25 and 28 injuries were correctly diagnosed on USG, CT and MRI respectively. Of 8 kidney injuries, 7 were correctly diagnosed on MRI. Hemoperitoneum and retroperitoneal haemorrhages were observed on USG (24 and 1), CT (33 and 7) and MRI and laparotomy (36 and 7).

In Srivastava et al<sup>(70)</sup> study, CT had detected four cases of hepatic trauma that were missed on USG and most of them were grade - I injuries and also CT helped in grading the lesion better in one case which was graded as grade - II but was given a higher grade as grade III on CT. CT detected 14 cases of splenic trauma compared to USG which detected only 11 cases, of the 3 additional cases detected on CT two were of grade - I and one was a grade IV injury, one case which was graded as grade I on USG was found to be grade III. USG detected only 7 cases of renal trauma where CT could detect 9 cases of renal trauma. CT detected 2 cases which were missed on USG. The reason for this could be due to partially filled bladder and also CT CYSTOGRAPHY was done when ever there was a doubt on NCCT.

Our results were in concordance with the Ramchandran et al<sup>(70)</sup> study who found that spleen is the predominant organ to be involved accounting for 31% (59 out of 190) followed by liver (39 patients-21%), kidney (21 patients-11%), bladder (12 patients-6%), bowel/mesentery (10 patients-5%) and pancreas (1%). The study done by Radhiana Hassan et al (2010) who encountered pancreatic injury in only 3% of the cases. Our study also correlates with the findings of MM Kumar et al<sup>(57)</sup> who accounted 26% of splenic injuries among visceral organs in his study.

While Reddy et al<sup>(65)</sup> found that liver was the most common organ injured and observed in 348 cases (63.5%), followed in order by Spleen 248 cases (45.26%), kidneys 24 cases (4.38%), Bowel and mesentery 12 cases (2.19%), pancreas 2 cases (0.36%) and urinary bladder in 2 cases (0.36%). Also, in Sanjay Bet al<sup>(64)</sup> study, liver was the most frequently injured organ with 55% incidence followed by spleen injuries in 41.95%. Urinary bladder was affected in 3.2% and pancreas in 6.4%.

In present study, none of the patients presented with grade I AAST injury. Five cases presented with grade II injury. Six cases endured with grade III splenic injury and 5 with grade 111 bowel and mesenteric lacerations. Majority cases had grade IV organ injury, in which, 12 cases had splenic injury, 8 were presented with liver injury, 7 with bowel and mesentery, 5 with kidney injury and 3 with grade IV pancreatic injury. 2 cases each were sustaining grade IV and grade V urinary bladder injury. 6 cases had grade VI liver injury in present series. Grade V injury of liver and spleen were seen in 8 and 6 cases, while 3 cases each had grade V injury of pancreas, kidney and bowel and mesentery.

Similar findings were observed by Sanjay B et al<sup>(64)</sup> Of the 22 cases of liver injuries, six had grade III injury. The remaining six cases had grade I and ten grade II injury. They found 17 splenic injuries, of them grade 111 injuries were seen in 6 patients. Two patients had grade 1 and five patients had grade II injury. Of 3 kidney injury, 2 had grade I injury and one with grade IV injury. They also noticed extra peritoneal bladder injury in one patient with an associated spleen and kidney injury.



Also, our results were comparable to the study conducted by Madhu et al. They observed that 14 patients had Liver injuries (33%) and out of these eight had grade 2 injuries while six had grade 3 injuries. 11 patients had Splenic injuries (26%) and out of these, six had grade 2 injuries, four had grade 3 and two had grade 5 injury. 10 cases of Hollow viscus perforation (23%). 3 Renal injuries (7%), 2 were of grade 3 and 1 of grade 4.

In present study, Sensitivity, specificity, positive predictive value, negative predictive value and accuracy of USG was determined to be 73.86%, 96.43%, 96.55%, 72.97% and 83.33% respectively. In CT and MRI sensitivity was 85.53% and 96.05%, specificity was 96.43% and 98.21%, PPV was 97.01% and 98.65%, NPV was 83.08% and 94.83% and accuracy was 90.15% and 96.97% respectively. Higher sensitivity and specificity along with greater accuracy was noted in MRI as compared to CT and USG.

In Reddy et al<sup>(65)</sup> study US had a sensitivity of 94%, specificity of 100%. CT findings in our study detected all the cases with hemoperitoneum or parenchymal injury or both and had sensitivity, specificity and accuracy of 100% when compared with US.

In Sanjay B et al<sup>(64)</sup> study, US had an overall sensitivity of 85.3%, specificity of 100% and accuracy of 86%. CT was positive (either for intra-abdominal free fluid or organ injury or both) in all the patients and thus showed an overall sensitivity, specificity and accuracy of 100%.

Sensitivity and Specificity of USG in detection of intraabdominal injury in the present study were somewhat similar with the study done by Atif Latif et al Kwashima et al<sup>(71)</sup> mentioned that multiorgan involvement occurs in 75% of those with blunt trauma; however, it differs regarding its association with penetrating trauma that he mentioned that it occurs in 80% of patients with penetrating trauma. This may be due to the fact that most patients with penetrating trauma included in this study had stab injury directed toward the flanks resulting in isolated renal injury. The most commonly injured intraabdominal organ associated with renal injury was the liver (46%) followed by the spleen (30%), and this is consistent with Ramchandani et al. who stated that the liver and the spleen are the most common intraabdominal organs to be injured with blunt trauma<sup>(72)</sup> Jeffrey et al. state that CT staging of blunt hepatic injuries has little discriminatory value in predicting outcome of stable patients, as nearly all have an excellent prognosis<sup>(73)</sup> Ilahi et al. in their study found that CT was 68% (19 of 28) accurate in diagnosing pancreatic injury<sup>(74)</sup> They concluded that CT scan is only moderately sensitive and can underestimate or miss pancreatic injury. Sclafani et al. consider CT the method of choice for renal injuries and confirmatory angiography unnecessary<sup>(75)</sup> Lupetin et al. using CT, diagnosed renal artery occlusion in all seven patients with renal trauma in their series<sup>(76)</sup>

In a case report by McGehee et al<sup>(53)</sup> on comparison of MRI with post-contrast CT in evaluation of acute abdominal trauma, they stated that, the efficacy of CECT for the evaluation of traumatic visceral injury is well established with reported sensitivities and specificities ranging from 93 to 96%. They concluded that MRI is superior in ability to image in multiple planes thus can diagnose more accurately than other modalities.

Few studies have investigated the use of MRI in patients with blunt abdominal trauma. MRI with coronal imaging has been used to evaluate the integrity of the diaphragm in cases of suspected diaphragmatic rupture<sup>(48)</sup> There have been case reports describing the use

of MRI in diagnosis of both renal and pancreatic injuries following trauma<sup>(51)</sup> Two additional studies have compared CT and MRI in the diagnosis of abdominal solid organ injury<sup>(53,77)</sup> The first study compared MRI without contrast material to CT with contrast material and found that MRI offered no advantage over CT for the routine evaluation of acute abdominal trauma<sup>(53)</sup> A more recent study using an experimental animal model compared the performance of MRI with intravascular contrast material to CT in the setting of abdominal trauma. Using a porcine model, hepatic and renal injuries were surgically created and followed with both CT and 3D MRI using intravascular contrast material. This study demonstrated that MRI was as comparable to CT in diagnosing intra-abdominal parenchymal injuries and intraperitoneal blood following traumatic injury<sup>(77)</sup>

With these improvements MRI can be used as a valid alternative in the workup of stable patients with contraindication to CT in the setting of blunt abdominal trauma.

### SUMMARY

- Road traffic accidents were major means of injury in our study (36 cases, 54.5%); followed by fall from height type of injury (15 cases, 22.7%). Assault in 9 patients (13.6%), bull gore injury in 2 patients (3.1%) and occupation related injury in 4 patients (6.1%) was source of blunt abdominal trauma.
- Majority of patients complained of abdominal pain (52 cases, 78.8%). Abdominal tenderness was seen in 50 patients (75.8%), abdominal guarding in 24 patients (36.4%), abdominal distension in 20 patients (30.3%) and rebound tenderness in 27 patients (40.9%). Bowel sounds were absent in 18 patients (27.3%). Twenty-two patients (33.3%) complained of vomiting. Hematuria and per rectal bleed was noted in 3 (4.5%) and 4 (6.1%) patients respectively.
- Exploratory laparotomy was done in all patients and its findings were considered as gold standard for evaluation of other diagnostic modalities. Laparotomy revealed hemoperitoneum, hollow viscous injuries and solid organ injuries in 43 (65.2%), 19 (28.8%) and 57 (86.4%) patients respectively.
- Hemoperitoneum was seen on USG, CT and MRI in 25, 40 and 43 patients.
- Hollow viscous injuries were noted using USG, CT and MRI in 14, 16 and 19 patients.
- Solid organ injuries were detected using USG, CT and MRI in 44, 52 and 55 patients.
- Site of injury in majority of patients was found to be spleen (29 patients); followed by liver (26 patients). Injury to kidney, pancreas, bowel and mesentery and urinary bladder was seen in 8, 6, 15 and 4 patients respectively. Hemoperitoneum and retro peritoneal haemorrhages were seen in 36 and 7 patients respectively.
- Sensitivity, specificity, positive predictive value, negative predictive value and accuracy of USG was determined to be 73.86%, 96.43%, 96.55%, 72.97% and 83.33% respectively. In CT and MRI sensitivity was 85.53% and 96.05%, specificity was 96.43% and 98.21%, PPV was 97.01% and 98.65%, NPV was 83.08% and 94.83% and accuracy was 90.15% and 96.97% respectively.
- Higher sensitivity and specificity along with greater accuracy was noted in MRI as compared to CT and USG.

### CONCLUSION

- To conclude, from our study MRI is always a superior diagnostic modality than US in cases of organ injury in BAT. However US can be performed as a initial imaging modality in all the cases of BAT but US can miss few cases of minor organ parenchymal damage and retroperitoneal hematomas masked by dilated loops or thickened bowel walls. Hence it is imperative that all cases of BAT are to be followed by MRI and CT after US. Our study strongly suggests that MRI scans should be followed by imperative CT and US scans or in cases which are negative by CT and US but clinically strongly suspicious of organ injury or damage. However accurate imaging diagnosis and hemodynamical stability are the main determinants that determine the strategy of management of cases of BAT. US is a sensitive investigation in diagnosing cases of hemoperitoneum than organ specific damages and MRI is a better diagnostic modality in organ damage than US and CT and has more sensitivity in detection of mesenteric tears and small bowel injury.

## BIBLIOGRAPHY

1. Raptopoulos V. Abdominal trauma. Emphasis on computed tomography. Radiologic clinics of North America. 1994;32(5):969-87.
2. Shiryazdi M, Modir A. Study of the diagnostic value of ultra sonography in blunt abdominal traumas. Pak J Med Res. 2005;44(3): 130-2.
3. Brown CK, Dunn KA, Wilson K. Diagnostic evaluation of patients with blunt abdominal trauma: a decision analysis. Academic Emergency Medicine. 2000;7(4):385-96.
4. Rosai J, Ackerman S. Surgical pathology. Eighth edition, Mosby. 1996:1917-2020.
5. Wolfman NT, Bechtold RE, Scharling E, Meredith J. Blunt upper abdominal trauma: evaluation by CT. AJR Am J Roentgenol. 1992; 158(3):493-501.
6. Fabian T, Croce M. Abdominal Trauma including indications for celiotomy in Feliciano DV, Moore EE, Mattox KL (ed) Trauma. Appleton & Lange; 1996.
7. Kristensen J, Buemann B, Kuehl E. Ultrasonic scanning in the diagnosis of splenic haematomas. Acta chirurgica scandinavica. 1971; 137(7):653-7.
8. Goletti O, Ghiselli G, Lippolis PV, Chiarugi M, Braccim G, Macaluso C, et al. The role of ultrasonography in blunt abdominal trauma: results in 250 consecutive cases. The Journal of trauma. 1994;36(2): 178-81.
9. Bode PJ, Niezen RA, van Vugt AB, Schipper J. Abdominal ultrasound as a reliable indicator for conclusive laparotomy in blunt abdominal trauma. The Journal of trauma. 1993;34(1):27-31.
10. Esposito T, Gamelli R. Injury to the spleen. Trauma. 2000;3:525-50.
11. Cales RH, Trunkey DD. Preventable trauma deaths: a review of trauma care systems development. Jama. 1985;254(8): 1059-63.
12. Davis JJ, Cohn Jr I, Nance FC. Diagnosis and management of blunt abdominal trauma. Annals of surgery. 1976; 183(6):672.
13. Richardson DJ. Changes in the management of injuries to the liver and spleen. Journal of the American College of Surgeons. 2005;200(5):648-69.

14. Sorkey AJ, Farnell MB, Wuliams HJ, Mucha P, Ilstrup DM. The complementary roles of diagnostic peritoneal lavage and computed tomography in the evaluation of blunt abdominal trauma. *Surgery*. 1989; 106(4):794-801.
15. Velmahos GC, Toutouzas K, Radin R, Chan L, Rhee P, Tillou A, et al. High success with nonoperative management of blunt hepatic trauma: the liver is a sturdy organ. *Archives of surgery*. 2003; 138(5):475-81.
16. Frumiento C, Vane DW. Changing patterns of treatment for blunt splenic injuries: an 11-year experience in a rural state. *Journal of pediatric surgery*. 2000;35(6):985-9.
17. Haan JM, Bochicchio GV, Kramer N, Scalea TM. Nonoperative management of blunt splenic injury: a 5-year experience. *Journal of Trauma and Acute Care Surgery*. 2005;58(3):492-8
18. Santucci RA, Fisher MB. The literature increasingly supports expectant (conservative) management of renal trauma—a systematic review. *Journal of Trauma and Acute Care Surgery*. 2005;59(2):491-501.
19. Stein DM, Scalea TM. Nonoperative management of spleen and liver injuries. *Journal of Intensive Care Medicine*. 2006;21(5):296-304.
20. Konstantakos AK, Barnoski AL, Plaisier BR, Yowler CJ, Fallon Jr WF, Malangoni MA. Optimizing the management of blunt splenic injury in adults and children. *Surgery*. 1999;126(4):805-13.
21. Sclafani SJ, Shaftan GW, Scalea TM, Patterson LA, Kohl L, Kantor A, et al. Nonoperative salvage of computed tomography-diagnosed splenic injuries: utilization of angiography for triage and embolization for hemostasis. *Journal of Trauma and Acute Care Surgery*. 1995;39(5): 818-27.
22. Hagiwara A, Yukioka T, Ohta S, Nitatori T, Matsuda H, Shimazaki S. Nonsurgical management of patients with blunt splenic injury: efficacy of transcatheter arterial embolization. *AJR American journal of roentgenology*. 1996; 167(1): 159-66.
23. Liu PP, Lee WC, Cheng YF, Hsieh PM, Hsieh YM, Tan BL, et al. Use of splenic artery embolization as an adjunct to nonsurgical management of blunt splenic injury. *Journal of Trauma and Acute Care Surgery*. 2004;56(4):768-73.
24. Haan JM, Biffl W, Knudson MM, Davis KA, Oka T, Majercik S, et al. Splenic embolization revisited: a multicenter review. *Journal of Trauma and Acute Care Surgery*. 2004;56(3):542-7.
25. Misselbeck TS, Teicher EJ, Cipolle MD, Pasquale MD, Shah KT, Dangleben DA, et al. Hepatic angioembolization in trauma patients: indications and complications. *Journal of Trauma and Acute Care Surgery*. 2009;67(4):769-73.
26. Mohr AM, Lavery RF, Barone A, Bahramipour P, Magnotti LJ, Osband AJ, et al. Angiographic embolization for liver injuries: low mortality, high morbidity. *Journal of Trauma and Acute Care Surgery*. 2003;55(6): 1077-82.
27. Carmont M. The Advanced Trauma Life Support course: a history of its development and review of related literature. *Postgraduate medical journal*. 2005;81(952): 87.

28. Root HD, Hauser CW, McKinley CR, LaFave JW, Mendiola RP. Diagnostic peritoneal lavage. *Surgery*. 1965;57(5):633-7.
29. Gonzalez M, Bucher P, Ris F, Anderegg E, Morel P. Splenic trauma: predictive factors for failure of non-operative management. *Journal de chirurgie*. 2008; 145(6):561 - 7.
30. Bakker J, Genders R, Mali W, Leenen L. Sonography as the primary screening method in evaluating blunt abdominal trauma. *Journal of Clinical Ultrasound*. 2005;33(4): 155-63.
31. Stengel D, Bauwens K, Sehouli J, Porzsolt F, Rademacher G, Mutze S, et al. Systematic review and meta-analysis of emergency ultrasonography for blunt abdominal trauma. *British journal of surgery*. 2001 ;88(7):901 -12.
32. Bode P, Edwards M, Kruit M, Van Vugt A. Sonography in a clinical algorithm for early evaluation of 1671 patients with blunt abdominal trauma. *AJR American journal of roentgenology*. 1999; 172(4):905-11.
33. Schnuriger B, Kilz J, Inderbitzin D, Schafer M, Kickuth R, Luginbuhl M, et al. The accuracy of FAST in relation to grade of solid organ injuries: a retrospective analysis of 226 trauma patients with liver or splenic lesion. *BMC Medical Imaging*. 2009;9( 1): 1 -6.
34. Rozycki GS, Ballard RB, Feliciano DV, Schmidt JA, Pennington SD. Surgeon-performed ultrasound for the assessment of truncal injuries: lessons learned from 1540 patients. *Annals of surgery*. 1998;228(4):557.
35. Miller MT, Pasquale MD, Bromberg WJ, Wasser TE, Cox J. Not so FAST. *Journal of Trauma and Acute Care Surgery*. 2003;54( 1):52-60.
36. Deunk J, Brink M, Dekker HM, Kool DR, van Kuijk C, Blickman JG, et al. Routine versus selective computed tomography of the abdomen, pelvis, and lumbar spine in blunt trauma: a prospective evaluation. *Journal of Trauma and Acute Care Surgery*. 2009;66(4): 1108-17.
37. Deunk J, Brink M, Dekker HM, Kool DR, Blickman JG, van Vugt AB, et al. Predictors for the selection of patients for abdominal CT after blunt trauma: a proposal diagnostic algorithm. *Annals of surgery*. 2010;251(3):512-20.
38. Brink M, Deunk J, Dekker HM, Kool DR, Edwards M, van Vugt AB, et al. Added value of routine chest MDCT after blunt trauma: evaluation of additional findings and impact on patient management. *AMERICAN JOURNAL OF ROENTGENOLOGY-NEW SERIES-*. 2008; 190(6): 1591.
39. Catalano O, Aiani L, Barozzi L, Bokor D, De Marchi A, Faletti C, et al. CEUS in abdominal trauma: multi-center study. *Abdominal imaging*. 2009;34(2):225-34.
40. Mullinix AJ, Foley WD. Multidetector computed tomography and blunt thoracoabdominal trauma. *Journal of computer assisted tomography*. 2004;28:S20-S7.
41. Miller LA, Shanmuganathan K. Multidetector CT evaluation of abdominal trauma. *Radiologic Clinics*. 2005;43(6): 1079-95.
42. Jayaraman S, Sethi D, Chinnock P, Wong R. Advanced trauma life support training for hospital staff. *Cochrane Database of Systematic Reviews*. 2014(8).

43. Deunk J, Dekker HM, Brink M, van Vugt R, Edwards MJ, van Vugt AB. The value of indicated computed tomography scan of the chest and abdomen in addition to the conventional radiologic work-up for blunt trauma patients. *Journal of Trauma and Acute Care Surgery*. 2007;63(4):757-63.
44. Huber-Wagner S, Lefering R, Qvick L-M, Korner M, Kay MV, Pfeifer K-J, et al. Effect of whole-body CT during trauma resuscitation on survival: a retrospective, multicentre study. *The Lancet*. 2009;373(9673): 1455-61.
45. Chan O. Primary computed tomography survey for major trauma. *Wiley Online Library*; 2009. p. 1377-8.
46. Brenner DJ, Hall EJ. Computed tomography—an increasing source of radiation exposure. *New England journal of medicine*. 2007;357(22):2277-84.
47. Saltzherr TP, Jin P, Bakker FC, Ponsen KJ, Luitse JS, Scholing M, et al. An evaluation of a Shockroom located CT scanner: a randomized study of early assessment by CT scanning in trauma patients in the bi-located trauma center North-West Netherlands (REACT trial). *BMC Emergency Medicine*. 2008;8(1): 1-5.
48. Barbiera F, Nicastrò N, Finazzo M, Runza G, Bartolotta T, Midiri M. The role of MRI in traumatic rupture of the diaphragm. Our experience in three cases and review of the literature. *La Radiologia Medica*. 2003; 105(3): 188-94.
49. Shanmuganathan K, Mirvis SE, White CS, Pomerantz S. MR imaging evaluation of hemidiaphragms in acute blunt trauma: experience with 16 patients. *AJR American journal of roentgenology*. 1996; 167(2):397-402.
50. Marsh MS, Nashef L, Brex PA. Neurology and pregnancy. *Clinical Management, Informa Healthcare*. 2012;21:214-21.
51. Cirillo RL, Koniaris LG. Detecting blunt pancreatic injuries. *Journal of gastrointestinal surgery*. 2002;6(4):587-98.
52. Fulcher AS, Turner MA. Magnetic resonance pancreatography (MRP). *Critical reviews in diagnostic imaging*. 1999;40(5):285-322.
53. McGehee M, Kier R, Cohn SM, McCarthy SM. Comparison of MRI with postcontrast CT for the evaluation of acute abdominal trauma. *Journal of computer assisted tomography*. 1993;17(3):410-3.
54. Sauaia A, Moore FA, Moore EE, Moser KS, Brennan R, Read RA, et al. Epidemiology of trauma deaths: a reassessment. *Journal of Trauma and Acute Care Surgery*. 1995;38(2): 185-93.
55. Zwingmann J, Schmal H, Stidkamp N, Strohm PC. Injury severity and localisations seen in polytraumatised children compared to adults and the relevance for emergency room management. *Zentralblatt fur Chirurgie*. 2008; 133(1):68-75.
56. Kozar RA, Crandall M, Shanmuganathan K, Zarzaur BL, Coburn M, Cribari C, et al. Organ injury scaling 2018 update: spleen, liver, and kidney. *Journal of Trauma and Acute Care Surgery*. 2018;85(6): 1119-22.
57. MM kumar MV, I.Venkatrathnam Prospective evaluation of Blunt abdominal trauma by CT. *IJRL* 2005; 15(2): 167-73.
58. Leung E, Wong L, Taylor J. Non-operative management for blunt splenic trauma in children: An updated literature review. *Surgical Practice*. 2007; 11(1):29-35.

59. Report. NTDB. Am Coll Surg 2005.
60. Tien HC, Tremblay LN, Rizoli SB, Gelberg J, Spencer F, Caldwell C, et al. Radiation exposure from diagnostic imaging in severely injured trauma patients. *Journal of Trauma and Acute Care Surgery*. 2007;62(1): 151-6.
61. Fabian T, Croce M. Abdominal Trauma including indications for celiotomy In: in Feliciano DV ME, Mattox KL (ed), editor. *Trauma*. 3rd Ed. ed. Stamford, Connecticut.: Appleton & Lange; 1996. p. 441-59.
62. Richards JR, Schleper NH, Woo BD, Bohnen PA, McGahan JP. Sonographic assessment of blunt abdominal trauma: 4-year prospective study. *Journal of clinical ultrasound*. 2002;30(2):59-67.
63. Boulanger BR, Brenneman FD, McLellan BA, Rizoli SB, Culhane J, Hamilton P. A prospective study of emergent abdominal sonography after blunt trauma. *Journal of Trauma and Acute Care Surgery*. 1995;39(2):325-30.
64. Sanjay B, Sanjeevi C. A Comparative Study of Ultrasonography and Contrast Enhanced Computed Tomography in Acute Abdominal Trauma.
65. Uma Maheswara Reddy V RMG, Ramakrishna Baru, Sunitha, Gowtham, Surya Duddu. . A comparative study of ultrasonogram and computed tomography in cases of blunt abdominal trauma. *International Journal of Contemporary Medicine Surgery and Radiology*. 2018;3(2):B152-B5.
66. Salim A, Sangthong B, Martin M, Brown C, Plurad D, Demetriades D. Whole body imaging in blunt multisystem trauma patients without obvious signs of injury: results prospective study. *Archives of Surgery*. 2006; 141 (5):468-75.
67. Mohapatra S, Pattanayak SP, Rao K, Bastia B. Options in the management of solid visceral injuries from blunt abdominal trauma. *Indian J surg*. 2003;65(3):263-8.
68. Kulkarm M, Hindlekar M. Primary repair or colostomy in the management of civilian colonic trauma. *Indian Journal of Gastroenterology: Official Journal of the Indian Society of Gastroenterology*. 1995; 14(2):54-6.
69. Farahmand N, Sirlin CB, Brown MA, Shragg GP, Fortlage D, Hoyt DB, et al. Hypotensive patients with blunt abdominal trauma: performance of screening US. *Radiology*. 2005;235(2):436-43.
70. P.RAMACHANDRAN. A STUDY OF COMPUTED TOMOGRAPHY EVALUATION OF BLUNT ABDOMINAL INJURY. Masters thesis, Coimbatore Medical College, Coimbatore. 2019.
71. Kawashima A, Sandler CM, Corriere Jr JN, Rodgers BM, Goldman SM. Ureteropelvic junction injuries secondary to blunt abdominal trauma. *Radiology*. 1997;205(2):487-92.
72. Ramchandani P, Buckler PM. Imaging of genitourinary trauma. *American journal of roentgenology*. 2009; 192(6): 1514-23.
73. Jeffrey Jr RB. CT diagnosis of blunt hepatic and splenic injuries: a look to the future. *Radiology*. 1989;171(1): 17-8.
74. Ilahi O, Bochicchio GV, Scalea TM, Aaland MO. Efficacy of computed tomography in the diagnosis of pancreatic injury in adult blunt trauma patients: a single-institutional study/discussion. *The American surgeon*. 2002;68(8):704.

75. Sclafani SJ, Becker JA, Shaftan GW, Phillips TF, Goldstein AS, Haller J, et al. Strategies for the radiologic management of genitourinary trauma. *Urologic radiology*. 1985;7(1):231-44.
76. Lupetin AR, Mainwaring B, Daffner R. CT diagnosis of renal artery injury caused by blunt abdominal trauma. *American Journal of Roentgenology*. 1989; 153(5): 1065-8.
77. Weishaupt D, Hetzer F, Ruehm S, Patak M, Schmidt M, Debatin J. Three-dimensional contrast-enhanced MRI using an intravascular contrast agent for detection of traumatic intra- abdominal hemorrhage and abdominal parenchymal injuries: an experimental study. *European Radiology*. 2000; 10(12): 1958-64.