

Original Research Article

Lipoma Arborescens: Unusual cause of articular swelling-Report of four cases and review of literature

Dr. Priyanka Kiyawat¹ (Asst. Prof), Dr. Seema Jindal² (Consultant Pathology),
Dr. Piyush Dwivedi³, (Lab Director Unipath, Indore), Dr. Devendra Baghel⁴,
Dr. Amit Kumar Semil⁵ & Dr. Yogendra Singh Gamad⁶, (Resident Medical Officer)

Dept. of Pathology, MGM, Medical College & M.Y. Hospital, Indore, M.P.^{1,4,5&6}

Corresponding Author Dr. Devendra Baghel

Abstract

Lipoma arborescens is a chronic, slowly progressive intra-articular condition characterised by villous lipomatous proliferation of the synovium, usually involving the suprapatellar pouch of the knee joint. It is an uncommon cause of intra-articular masses that presents as slowly progressive painless swelling of the joint, which persists for many years and is associated with intermittent effusions. We present this condition to raise awareness of its clinical spectrum and imaging features, so that early diagnosis and appropriate treatment can be given, and misdiagnosis of this type of rare benign condition as other more complex intra-articular masses is avoided.

Keywords: *benign, intra articular masses, lipoma arborescens, imaging, lipomatous*

1. INTRODUCTION

Lipoma arborescens (L.A) is a rare benign intra-articular lesion characterised by papillary villous synovial hypertrophy and proliferation of mature adipose tissue(1). The term arborescens meaning “tree-like” in Latin, describes the unique villous and frond-like appearance of this rare unusual condition(2.). We highlight this condition to raise awareness to be kept as a differential diagnosis in knee joint affected by various slow, progressive chronic inflammatory conditions. Incidence in children and female is rare. Out of 3 cases we have one case with female preponderance. Exact cause of lipoma arborescens is unknown, it has been supposed to be a nonspecific reactive synovial fatty proliferation in response to chronic traumatic or inflammatory stimuli rather than a malignant process. (3,4)

CASE REPORT 1

50 years male came with complains of left knee swellings since 2 years. The swelling increased since past 1 year. Intensity of pain was mild and not affecting routine day to day activities. No night pains. No complains of fever, multiple joint pain, bleeding tendencies, loss of weight, and trauma. Conservative treatment was taken at multiple places in form of medication, physiotherapy, knee aspiration, and also local Kenacort injection given. Clinical examination revealed massive joint swelling with terminal range of motion restricted and painful. No signs of inflammation noted X-ray showed osteoarthritis changes with area of dense soft-tissue opacity in the supra patellar region.

Blood investigation showed increase in erythrocyte sedimentation rate: 80 mm and C-reactive protein: 32 mg/dl levels, anti-cyclic citrullinated peptide, S. uric acid, ANA, Rheumatoid factor, bleeding time, clotting time, and blood counts were within normal limit.

MRI showed large effusion distending the suprapatellar and infrapatellar region with frond like fatty area seen in peri condylar and joint cavity. Synovial thickening and hypertrophy noted. Arthroscopic synovectomy was done and material sent for histopathological examination. MRI and histopathological diagnosis suggested Lipoma Arborescens.

Case Report 2

A 48 years old male presented with swelling in knee joint not associated with pain. On examination, there was painless, diffuse swelling in the suprapatellar area with presence of effusion in the right knee joint. The patient had a restricted terminal flexion and showed no signs of meniscal lesions.

X-ray showed enhanced soft tissue shadow in the suprapatellar pouch. MRI depicted frondlike villous projections of fat signal seen arising from the lower portion of the suprapatellar recess, in the popliteal fossa, and the infrapatellar region associated with gross collection in the suprapatellar recess into the joint from the synovium. Degenerative changes were noted in the meniscus, anterior cruciate ligament, and osteoarthritic changes with subarticular geodes in the lateral tibial condyle.

The patient underwent diagnostic arthroscopy and open total synovectomy. Sample sent for histopathology. Received excised multiple grey yellow nodular soft tissue pieces. Microscopy showed hypertrophic villous projections of fat lined by synovial cells. The diagnosis of lipoma arborescens was confirmed on histological examination.

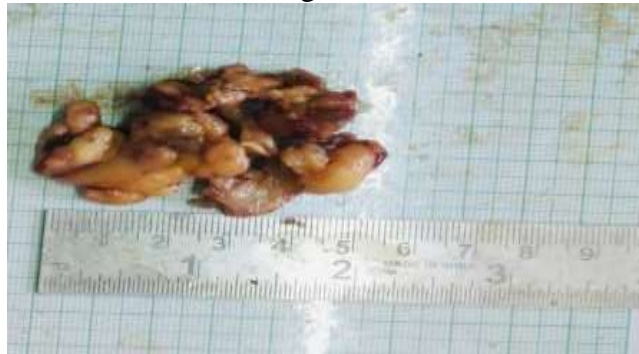
Case Report -3

15 years female complains of swelling and occasional pain in the left ankle without any triggering traumatic event since 2 years. Her symptoms were relieved with physical therapy. She also presented a palpable mass of soft to firm in consistency which was painless and moderate joint effusion. Plain radiographs of the ankle showed reduced joint space, subchondral sclerosis, and reactional osteophytes. The patient underwent diagnostic arthroscopy. Sample received in histopathology department as grey yellow soft tissue pieces aggregate measuring 2.5*2*1.8 cm. Microscopy revealed hypertrophic villous projections of fat lined by synovial cells, variable scattered inflammatory cells. The diagnosis of lipoma arborescens was confirmed on histological examination.

Case Report 4

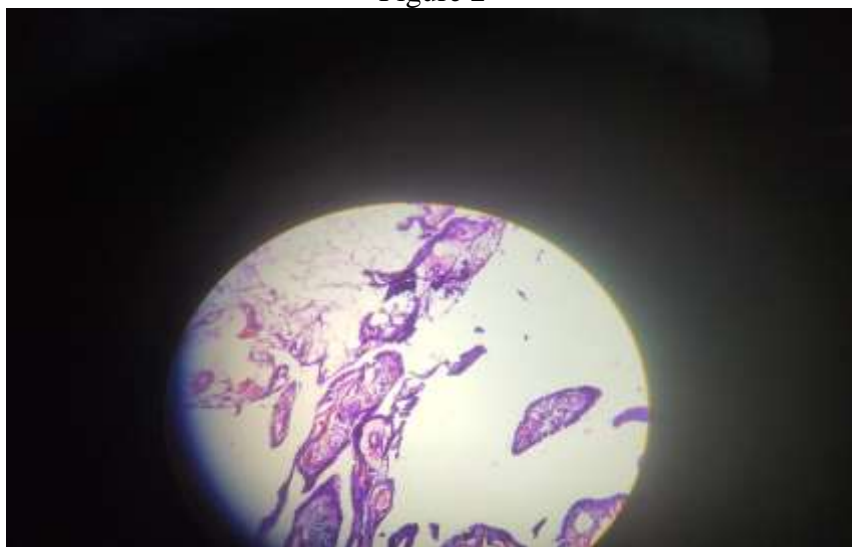A 25-year male complain of left ankle joint swelling since 2.5 year with no history of trauma. Pain was mild in nature and not affected daily activity. He was also complaining a palpable mass which is gradually increase in size. X Ray showed hyperechoic non-inflammatory mass. MRI showed fat containing frond like synovial mass and joint effusion. Sample received in histopathology department as grossly appear yellow nodular soft tissue pieces aggregate measuring 5*4*1.5 cm. microscopically shows synovial tissue having papillary architecture completely replaced by mature adipocytes. The diagnosis of lipoma arborescens was confirmed on histological examination.

Figure 1



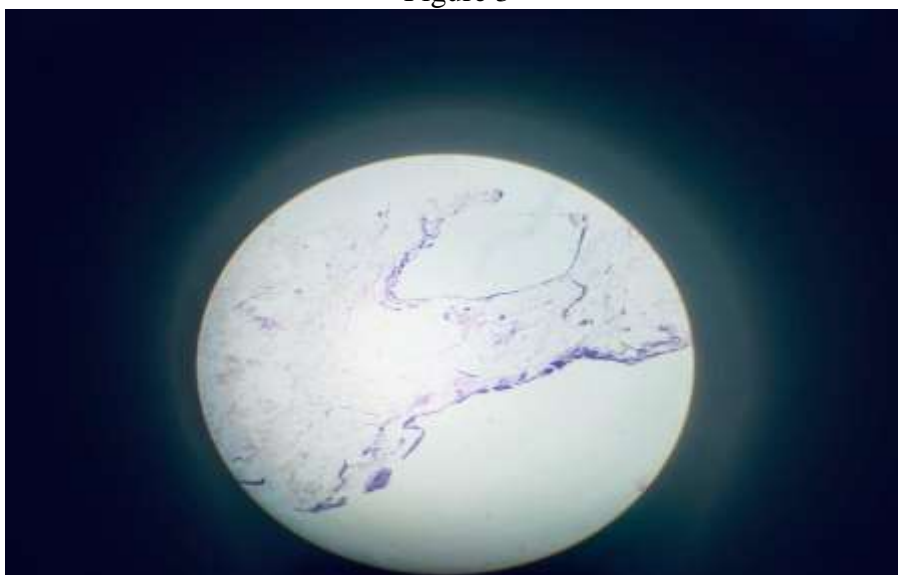
Gross- Yellow nodular soft tissue pieces.

Figure 2



(Hematoxylin and eosin, high power view) villous proliferation of the synovium, with focal and diffuse infiltration by mature adipocytes.

Figure 3



(Hematoxylin and eosin, high power view) Synovial tissue having papillary architecture completely replaced by mature adipocytes

2. DISCUSSION

Hoffa first described lipomaarborescens in 1904.(6) It is a rare benign tumor of synovium and very few cases have been reported in the literature.(5) Incidence varies from 0.14–0.25% . (4) The peak incidence is between the third and fifth decades, with a predilection for male (15). Lipomaarborescens is a rare pathology which is described from the early 20th century, it has been consolidated as a disorder related to slowing evolving, recurrent, and generally painless monoarthritis and progresses with articular effusion and decreased range of movement.(6).Lipomaarborescens can be classified as either primary or secondary depending on the underlying condition or age of presentation (4,7).There has been fewer than 100 cases reported in the literature .(8).15 were children, making it extremely rare in this age group. (9,10). The term lipoma is misleading as this condition does not show any features of lipoma and do Hallel et al. suggested that lipomatous proliferation of the synovial membrane would be an appropriate term(11).Usually, patients present with a history of trauma preceding swelling. Swelling is slowly progressive associated with pain, joint effusion, limited range of motion, locking, and degenerative changes. Diffuse synovial thickening is noted on examination. The diagnosis of lipomaarborescens is based on typical findings on MRI and is considered as the gold standard. (12) Other tests such as laboratory investigation, joint fluid aspirate, and X-rays, anti-ccp, RA factor can be used to rule out other causes of monoarthritis with effusion. Macroscopically, lipomaarborescens appears as a yellowish synovial proliferation, with broad villous projections of fatty tissue arranged in an arborescent pattern, usually filling the suprapatellar pouch and both gutters. Histologically, papillary proliferation of synovial villi massive infiltration of the synovium by mature adipose cells is characteristic for lipomaarborescens. Enlarged hyperemic capillaries and focal chronic inflammatory infiltration are usually observed (13).Lipomaarborescens in the pediatric population should be differentiated from other atraumatic chronic knee swellings such as juvenile rheumatoid arthritis, Lyme disease, acute rheumatic fever, hemophilia, mycobacteria tuberculosis, pigmented villonodularsynovitis, synovial osteochondromatosis, and synovial hemangiomas. CBC, ESR, C- reactive protein, rheumatoid factor, anti- CCP, and screening for Lyme disease in endemic areas should be done as part of the laboratory investigations to rule out the other differential diagnosis though these are nonspecific. Lipomaarborescens treated by arthroscopic or open excisional biopsy depending on the extent of the lesion and the surgeon's personal experience. Recurrence after surgical excision is rare.(14)

3. CONCLUSION

Lipomaarborescens(LA) is a rare intra- articular condition characterized by villonodular proliferation of the synovium. LA more commonly affects male but in our study case 3 patient is female and it affects 3-4 decade but we found children are also affected out of 4 case we have one case which affects children.

This entity can be diagnosed by its characteristic features on various imaging modalities, particularly MR imaging along with histopathological co-orelation. Awareness of its clinical and imaging findings and possible differential diagnoses is essential for early diagnosis and treatment, to avoid misdiagnosis of this condition as other aggressive articular masses

4. REFERENCES

1. Hallel T, Lew S, Bansal M. Villous lipomatous proliferation of the synovial membrane (lipomaarborescens). *J Bone Joint Surg Am*. 1988;70:264- 270
2. Sanamandra SK, Ong KO. Lipomaarborescens. *Singapore Med J*. 2014;55(01):5- 10; quiz 11. doi: 10.11622/smedj.2014003
3. Ryu KN, Jaovishida S, Schweitzer M, Motta AO, Resnick D. MR imaging of lipomaarborescens of the knee joint. *Am J Roentgenol*. 1996;167:1229–32
4. Vilanova JC, Barceló J, Villalón M, et al. MR Imaging of Lipomaarborescens and the associated lesions. *Skeletal Radiol*. 2003;32:504–9
5. Hoffa A. “The influence of the adipose tissue with regard to the pathology of the knee joint.” *JAMA* 1904;43(12):795–796. DOI: 10.1001/ jama.1904.92500120002h
6. Taissa Pinto de Souza1, Juliana Brandao Pinto Carneiro1, Monique Freire dos Reis2, et al. Case Report:Primarylipomaarborescens of the knee. *European journal of rheumatology*. DOI:10.5152/eurjrheum.2017.17014.
7. Patil PB, Kamalapur MG, Joshi SK, Dasar SK, Rao RV. Lipomaarborescens of knee joint: role of imaging. *J Radiol Case Rep*. 2011;5:17- 25. doi: 10.3941/jrcr.v5i11.783
8. De Vleeschhouwer M, Van Den Steen E, Vanderstraeten G, Huysse W, DeNeve J, VandenBossche L. Lipomaarborescens: review of an uncommon cause for swelling of the knee. *Case Rep Orthoped*. 2016;2016:1- 5
9. Sailhan F, Hautefort P, Coulomb A, Mary P, Damsin JP. Bilateral lipomaarborescens of the knee: a case report. *J Bone Joint Surg Am*. 2011;93:195-198. doi: 10.2106/JBJS.I.01418
10. Nevins LCE, Tenfelde AM. Lipomaarborescens in a 10-year-old boy. *J Am AcadOrthopSurg Glob Res Rev*. 2020;4:e20.00108. doi: 10.5435/JAAOSGlobal-D-20-00108
11. Sanat Kumar Sanamadra, Ken OonOng. CME Article LipomaArbroscence. *Singapore Med J*. 2014;55(1):5–11.
12. GozdeErcanZeybek, et al. Progressive bilateral lipomaarborescens of the knee caused by uncontrolled juvenil idiopathic arthritis. *North ClinIstanb*. 2020;7(5):512–51
13. Soler T, Rodríguez E, Bargiela A, Da Riba M. Lipomaarborescens of the knee:MR characteristics in 13 joints. *J Comput Assist Tomogr*. 1998;22:605–9
14. Gandhi V, Shory S, Kumar A, et al. Lipomaarborescens- a rare cause of monoarticular knee joint swelling in adolescents- case report. *OrthopedRheumatol Open Access J*. 2019;14:53- 57
15. P. Kloen, S. B. Keel, H. P. Chandler, R. H. Geiger, B. Zarins, and A. E. Rosenberg, “Lipomaarborescens of the knee,” *The Journal of Bone & Joint Surgery—British Volume*, vol. 80, no. 2, pp. 298–301, 1998.