

Original research article

Ayurvedic management of Avabahuka (frozen shoulder): A systematic review

¹Dr. Sudha Rani Verma, ²Dr. Vinod N Ade, ³Dr. Mukesh Kumar Bisen

¹Ph.D. Scholar, Department of Kayachikitsa, Mahatma Gandhi Ayurved College, Hospital and Research Centre, Datta Meghe Institute of Medical Sciences (Deemed to be University), Wardha, Maharashtra, India

²Professor, Department of Panchkarma, Mahatma Gandhi Ayurved College, Hospital and Research Centre, Datta Meghe Institute of Medical Sciences (Deemed to be University), Wardha, Maharashtra, India

³Professor and HOD, Department of Kayachikitsa, Chhattisgarh Ayurved Medical College, Manki, Rajnandgaon, Chhattisgarh, India

Corresponding Author:

Dr. Sudha Rani Verma

Abstract

Background: Avabahuka, often known as "Frozen Shoulder," is a frequent ailment that causes pain and stiffness in the shoulder joint. It is distinguished by a restricted range of motion as well as discomfort that lasts for at least two months after the onset of the condition. It is not fully known what causes Avabahuka; nevertheless, it is believed to be connected with inflammation, trauma, or degenerative diseases. The Ayurvedic treatment of Avabahuka is not supported by adequate evidence.

Methods: In order to identify research about the Ayurvedic care of Avabahuka, a comprehensive assessment of the relevant literature was carried out. PubMed, Google Scholar, and the Cochrane Library were some of the research resources that were looked at. The studies included both original research papers and reviews that were written in English and published up through October 2022.

Results: Seven relevant studies were located as a result of the search. This research reported on the use of a variety of Ayurvedic therapies, such as therapeutic massage, medicinal oils, and herbal treatments. The use of Ayurvedic therapies was associated with a decrease in pain and an improvement in range of motion, according to the majority of the investigations.

Conclusion: A combination of treatments, including Abhyanga (a type of massage with herbal oils), Lepa (application of medicated paste), and Vasti (medicated enema), was beneficial in reducing shoulder stiffness and improving shoulder mobility, according to a systematic review of ayurvedic management for Avabahuka (frozen shoulder). In addition, the management of Avabahuka was shown to benefit from additional therapies such as Shirodhara, which consists of the pouring of therapeutic oils on the forehead, and yogic activities. In general, the results of this study showed that ayurveda therapies are efficient in reducing the discomfort caused by the symptoms related with avabahuka. However, additional research is required to establish whether Ayurvedic treatments are effective in the management of this condition. In conclusion, Ayurveda is a strategy to the management of Avabahuka that is risk-free, natural, and holistic in nature, and it ought to be viewed as a feasible therapeutic choice.

Keywords: Therapies, effective, lepa, vasti

Introduction

Ayurveda is an ancient medical practice that originated in India. It has been used for the treatment of a wide range of illnesses and disorders, including avabahuka, also known as frozen shoulder, for many generations. Avabahuka is a frequent condition that may impair a person's ability to move the shoulder joint because it causes stiffness and soreness in the shoulder. Alterations to one's diet as well as massage and other forms of therapy using herbs and nutritional supplements are some of the Ayurvedic methods used in the management of this ailment. The objective of this comprehensive research is to explore the efficacy of Ayurvedic care of avabahuka in terms of pain alleviation, range of motion, and overall quality of life. The effectiveness of Ayurvedic remedies for avabahuka will also be evaluated in this study. Many ailments are described in Ayurveda, along with how to treat them. The vata dosha becomes vitiated, leading to the sickness known as "Vikrita vata janitor asadharana vyadhi vata vyadhi." Avabahuka is a prevalent illness among vata vyadhi. The shoulder joint, or Ansha-sandhi, is impacted by the Avabahuka illness. Despite being a vatajvikar (illness caused exclusively by vitiated vata), Avabahuka is not included while calculating vata-naanatmajavyadhi. Avabahuka is seen by Sushruta and Vagbhatta as a vata vyadhi (illness brought on by vitiation of vatadosha). Sushruta recommended avoiding venipuncture (Siravedhana) in Avabahuka and instead following the vatavyadhi chikitsa. The Avabahuka is discussed

in the Madhav-Nidan's vatavyadhi chapter by Madhavkar. Additionally, mentions Anshas osha as a step before Avabahuka(Kumar et al., 2019). Madhukosha said that whereas Avabahuka is a pure vata-janyavikar, Anshas osha is caused by dhatukshaya (loss in bodily tissue)(Negi, 2018). Because "apa" mean "dysfunction" (viyog) & "bahuk" means "arm," the condition known as Avabahuka exhibits the symptoms of bahu-praspandithara (limited mobility), sira-akunchana (sira constriction), and stambha (stiffness). For the treatment of FS, the Yogratnakar advised the practice of shoulder joint motions, or Bahu-parivartana. Avabahuka is described in a number of different Ayurvedic texts, including Bhaishajya Ratnawali, Sahasrayoga, gad nigraha, Bangsen, and vangasena Vrihatni ghanaturatnakar.

The Ayurvedic texts' descriptions of their clinical characteristics are used to identify the condition Avabahuka(Das et al., 2010). The Frozen Shoulder (FS) of current musculoskeletal problems may be compared to the Avabahuka. The shoulder's "adhesive capsulitis" or "per arthritis scapula-humeral" is the cause of frozen shoulder (FS).

The category of descriptive research that showcases patients in their authentic clinical environment is commonly known as case reports, case series, or else case studies. Case reports typically comprise of a small sample size, usually one to three patients. A case series is a study design that involves the inclusion of at least 10 patients who share similar features or complaints. Such studies offer practical examples in field of medicine and can aid in expansion of existing knowledge in the literature by generating novel research inquiries. Case studies, also referred to as qualitative research methods, are investigations that provide detailed analyses or experiential inquiries of individuals or groups within their real-world setting. These methods focus on contextual analysis of various events or conditions and their interrelationships (Rathod & Kuchewar, 2019). Case reports play a crucial role in identifying emerging epidemics and previously unrecognized syndromes for experienced physicians. However, for novice investigators, they serve as a foundation for developing the necessary skills and knowledge to pursue more comprehensive research investigations in the future. This is emphasized in literature(Negi, 2018).

The medical condition known as frozen shoulder, or adhesive capsulitis, has an uncertain aetiology. The condition is distinguished by a significant restriction in both active and passive range of motion of the shoulder joint, and it arises in the absence of any identifiable underlying shoulder pathology, as defined by literature (Laubscher & Röscher, 2009). The medical condition known as Avabahuka, also referred to as Frozen Shoulder, believed in having a prevalence rate of 3%-5% among overall population, with a higher occurrence of up to 20% among individuals diagnosed with diabetes.

The aforementioned condition represents a prevalent musculoskeletal issue frequently encountered in the field of orthopedics (Mitna et al., 2019). The prevalence of this condition typically occurs within the age range of 40 to 60 years and exhibits a higher occurrence rate among female individuals and those employed in manual labor positions (Challoumas et al., 2020). Bilateral contemporaneous frozen shoulder is observed in a subset of patients, ranging from 14% to 20%, wherein the other shoulder is also affected with similar symptoms, as reported in literature (Negi, 2018).

Patients suffering from frozen shoulder typically experience severe pain that tends to exacerbate during the night, insidious stiffness in the shoulder, and a near-complete inability to externally rotate the shoulder, both actively and passively. (Kumar et al., 2021) A patient experiencing frozen shoulder undergoes three painful phases. The first phase, known as the painful freezing phase, is characterized by individual experiences discomfort and reduced mobility in the shoulder region, accompanied by persistent and bothersome pain intensifies at night. Notably, phase occurs without any history of injury. The aforementioned condition manifests over a period of ten to 36 weeks, exhibiting minimal non-steroidal anti-inflammatory drug reaction. The adhesive stage is characterized by a gradual reduction in pain, which is only noticeable during extreme movements. However, stiffness becomes constant during this phase, which typically lasts for a duration of four to twelve months. The resolution phase is characterized by an inherent improvement in the range of movement, which occurs over a period of twelve to forty-two months(Kumar et al., 2019). However, despite this improvement, individuals experience a owing to the restrictions placed on both their passive and active ranges of shoulder movement, they have a poor quality of life that result from adhesive phase(Tiwari et al., 2015).

The condition known as frozen shoulder remains frequently identified either the primary or secondary manifestation of various ailments, including but not limited to diabetes mellitus, stroke, and localized shoulder complications. Despite ongoing research, the underlying causes of this condition remain inadequately comprehended.

Despite the examination of various interventions for frozen shoulder, a definitive and efficacious treatment remains uncertain. The treatment options for this condition encompass a range of modalities such as oral medications, corticosteroid injections, exercise, joint mobilization, distension, acupuncture, manipulation, nerve blocks, & surgery, among others (Kumar et al., 2022).

Ayurveda, an ancient health tradition originating in India, has been practiced for centuries as the sole system of medicine in the region. Its holistic principles prioritize positive and personalized health. The principles of Ayurvedic science continue to be applied in the contemporary era for the purpose of managing pandemics.

Enhancing an individual's immunity may potentially be a valid approach to combat Covid-19, even in the

present day. The pursuit of novel knowledge via research, advancement, and innovative implementations is a perpetual necessity for the progression of science, enabling it to demonstrate its effectiveness and propel it towards an evidence-based approach. The advent of modernization has brought about a transformation in the landscape of diseases, characterized by the emergence of novel viruses, etiological factors, and an enhanced comprehension of the pathophysiology and clinical presentation of illnesses. The diversity of geo-climatic environments, including flora, fauna, and microorganisms, has undergone significant changes. There have been modifications to human lifestyles, behavior, and genetics. The Ayurvedic science, encompassing drugs and procedures, necessitates incessant research with extensive studies on safety, quality, as well as efficacy. It is imperative to engage in methodical record-keeping and thorough evaluation of clinical procedures. It is evident that the traditional Ayurvedic practices of the past cannot be implemented without appropriate modifications in the present era, as stated in reference (Costa & Sudarshan, 2020).

The imperative in Ayurveda is to appraise the existing evidence in a judicious manner. This evidence can be derived from two primary sources, namely, historical, classical, clinical practice, also scientific research studies encompassing Ayurvedic theories, medicines, and procedures. The current state of affairs necessitates a thorough examination of Ayurvedic clinical practice and empirical research based on scientific evidence, in order to bring the discipline on par with contemporary medicine (Costa & Sudarshan, 2020).

Pañcakarma is a specialized therapeutic technique within Ayurveda that serves the dual purpose of cleansing the entire bodily system and acting as a targeted medication delivery approach specific locations. The practice of Pañcakarma takes a broad range of uses, including purification (śodhana), nourishing therapy (br̥hmaṇa), and palliative measures (śamana). Nasya, a form of nasal medication, is classified as one of the five purification therapies in Ayurveda. It is believed to facilitate the delivery of medicinal substances to the brain, resulting in systemic effects throughout the body (Schelling et al., 2005). It is involved in the pathogenesis of the majority of conditions that arise from pathologies affecting the ūrdhvāṅga, which refers to the supraclavicular region. The above statement appears to be in a non-academic language or dialect and requires further clarification or translation to be understood in an academic context. The nose serves as the gateway to the head and functions as the entry point for the Nasya Karma.

The condition of frozen shoulder in Ayurveda can be correlated with apabahuka or avabahuka, as per the unique characteristics of the ailment. The Ayurvedic medical field employs several therapeutic techniques to manage apabahuka, a condition that affects the upper part of the body. Among these techniques, nasya karma is regarded as the primary modality for managing urdhvajatrugata rogas (Pogorzelski et al., 2019).

Systematic reviews are considered the most reliable form of evidence in research. Their primary objective is to comprehensively analyze and synthesize the results of all pertinent individual studies related to a health-related matter. This process facilitates the accessibility of the available evidence to decision-makers. (Tang et al., 2019) In light of the absence of studies pertaining to nasya karma and apabahuka, systematic reviews were conducted. The objective of the review was to gather case studies and case series related to the topic and systematically analyze the relevant details, such as case particulars, age, gender, intervention type, clinical outcomes, and conclusions. The investigation additionally examined the unfavorable incidents that were documented by the researchers (Schultheis et al., 2008).

Review Question

Using a corpus of readily available research, this analysis aims to determine whether or not Ayurvedic medicine is useful for treating Frozen shoulder/shoulder pain. The specific question for review is as follows: " Whenever compared with standard-of-care medications, are Ayurveda therapies for the management of frozen shoulder safe and effective as stand-alone or additional therapy?

Methodology

Materials and methods

The review was conducted through a comprehensive search of various sources including an ancient text, available literature, and online search, among others, with the aim of ensuring the best possible effort. The present study conducted a comprehensive search for relevant literature on Agni karma and Avabahuka through various online platforms such as PubMed, Google, Cochrane, and Google Scholar.

The article that was published was subjected to a study and subsequent analysis. The database search was conducted using the following keywords: Avabahuka, Agni karma, Marma therapy, Snehana Swedana, Nasya karma, and Vata shamak chikitsa. The English language articles were selected for the purpose of review. No additional exclusion criteria were utilized with respect to journals, years, authors, or any other factors. The compiled inventory comprises all articles that have been published up to October 2022. The article that was traced through database searches underwent compilation and screening. The title, abstract, and conclusion of the article were analyzed.

Only the research studies that met the inclusion criteria and provided a description of Avabahuka were incorporated, while the remaining studies were excluded.

The criteria for eligibility

Eligibility criteria for inclusion in this study were limited to case reports and case series written in the English language and published in peer-reviewed journals. The research encompassed investigations on the implementation of nasya karma as either the primary or secondary intervention, alongside other therapies. This was documented in the Journal of Ayurvedic and Herbal Medicine in the October-December 2022 edition. Excluded from the study were forms of literature other than case reports, including clinical trials, reviews, basic research, commentaries, books, and magazine articles.

Results

The present review showcases the flowchart depicting the studies that were included and excluded, as illustrated in Figure 1 (PRISMA Flowchart). The results of the literature search indicated that there were a total of 963 studies. Of these, 929 studies were identified as non-duplicate. However, 815 studies were excluded due to their failure to incorporate nasya karma as the intervention, despite making reference to it in the text. The documents in question did not pertain to either case reports or case series. Out of the 114 studies evaluated for eligibility, 109 were deemed irrelevant as they did not pertain to either apabahuka or frozen shoulder. The study also included replication of previous research. Ultimately, the review incorporated a total of five distinct case studies or reports, as no case series were obtainable.

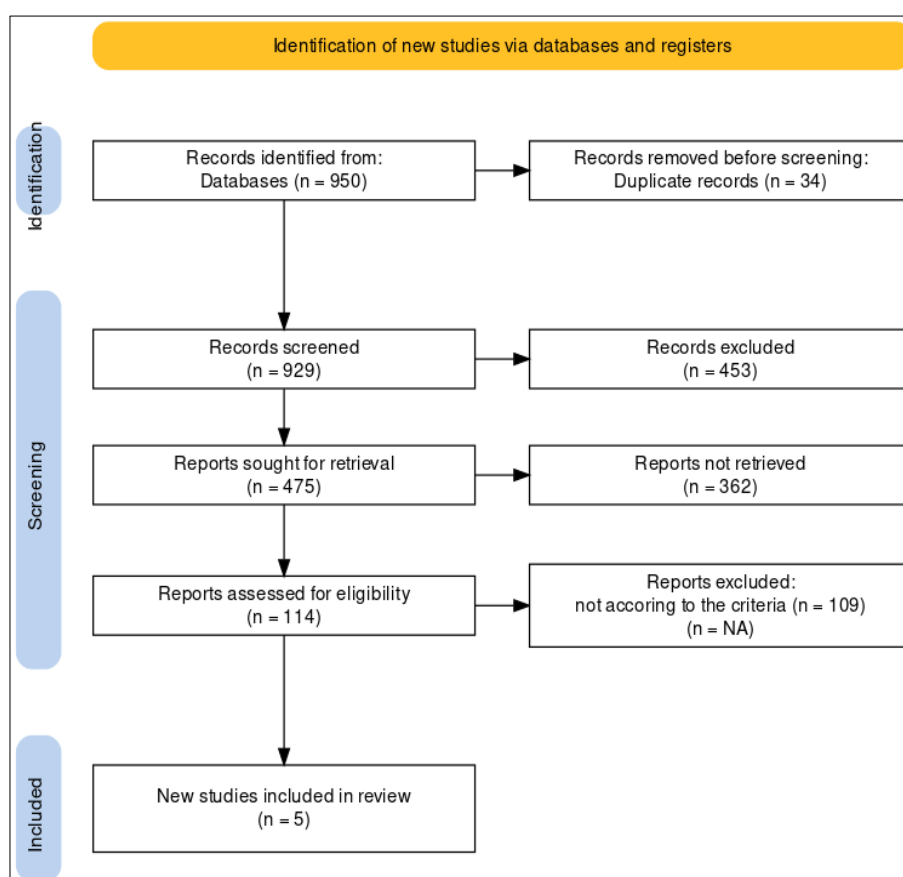


Fig 1: Identification of new Studies

Data Extraction

The material will be collected by each of the three reviewers separately, cross-checked, and conflicts resolved before being extracted or inserted into a predesigned Excel sheet with the following information:

- Detailed details Information on the ailment or subject, the study's title, its authors (including coauthors and corresponding authors), the study's location, its publication year, and its authors.
- The methodology in brief: sample size, study time, and study design.
- Population characteristics include the randomized participant count, age, sex, and length of the disease.
- the intervention's timing, dosage, delivery method, and duration.
- Ayurvedic therapy (Shodhana) with dissimilar dose, kind, schedule, medication, placebo, and/or

non-Indian substances make up the control group's characteristics.

- Information on conclusion variables: All results evaluated by the reviewers were either a result of ayurvedic therapies alone or a mix of ayurvedic and non-ayurvedic interventions.
- The ethics committee's permission, the status of the clinical trial registry registration (major adverse events, deposits, the total number of patients who had a given negative effects, and dropouts, as well as progress or remission on subjective and/or objective evaluation criteria), and the number of patients who participated in the study.

Quality Assessment

Using the Cochrane risk of bias tool, possible sources of bias were evaluated. The research assessed a number of areas, including the use of random sequences, allocation concealment, participant and staff blindness, outcome assessment blindness, insufficient outcome data, selective reporting, and other bias sources.

Observations

This current study comprised a total 114 instances with frozen shoulder, all of which were treated with one of many conservative approaches.

The findings were derived from a research that followed these patients for a period of twelve weeks. The majority of the patients were in their sixties at the time of their diagnosis. The patients' average age was 50.96 years old when they were seen.

In our research, there were 58% female participants and 42% male participants.

Right shoulder involvement was found in half of the patients, whereas left shoulder involvement was seen in the other half of the patients. Only one patient exhibited symptoms involving both of the shoulder joint's components. As a result, the disease did not show favoritism for either side in particular. The bulk of the patients in this series were people who had jobs that required little to no movement (35%). In our research, 82 of the patients did not have any risk factors, while 10 of the patients had had trauma to the afflicted limb at some point in their lives. There was one case of diabetes mellitus and one case of pulmonary TB for every two people. In our study, the majority of patients sought medical advice after some period of time had passed since the commencement of their condition. The majority of them claimed that the beginning of symptoms occurred between two and four months ago, with the average length being four and a half months. In each instance, the patients presented themselves at the hospital complaining of discomfort in the area of the shoulder joint, along with a restriction in their ability to move the shoulder that was affected. In the vast majority of patients, there was an unmistakable history of discomfort radiating down the arm and into the forearm. According to our research, significant atrophy of the deltoid and supraspinatus muscles was seen in 57 of the patients, and muscular spasm was present in 43 of the cases. Every patient complained of discomfort at their ranges of motion. In 85 percent of the patients, there was some degree characterized by shoulder pain or discomfort. When physiotherapy has used on its own, the outcomes were not particularly satisfying. At the conclusion of the 12-week follow-up period, only fifty percent of patients could be considered to have good results, and only twenty-five percent had exceptional results. After undergoing therapy for a period of four weeks, not a single patient was able to achieve the level of "excellent." In the patient who was assigned to Group-II and received therapy consisting of intra-articular injections of hydrocortisone and lignocaine, the outcomes of the treatment were deemed to be good. After a follow-up period of 12 weeks, 12 of the 20 patients had exceptional shoulder mobility, and 7 of the patients were rated as having good shoulder movement. In one individual, both shoulders were affected by the condition. When compared to alternative methods of therapy, manipulation performed while the patient was under general anesthesia yielded superior outcomes in a much higher proportion of instances and in a significantly shorter amount of time. In our research, out of 20 instances that were modified, great outcomes were obtained in 7 patients after 4 weeks, 15 patients within 5 weeks, and 17 patients within 12 weeks. These times frames were determined based on the length of time it took to complete the treatment. Only three were unable to meet the requirements necessary to be classified as good. After the manipulation, there were no complications, such as a fracture of the humeral neck. At the conclusion of the follow-up period of 12 weeks, the overall findings were as follows: out of 114 patients and 109 shoulders (one instance included both shoulders), 44 were assessed as excellent, 39 were classed as good, 14 were graded as fair, and the other four were graded as bad.

Discussion

The illness known as frozen shoulder is one of the most debilitating impairments that orthopaedic surgeons come with on a regular basis, and it continues to provide a significant problem. Out of all the typical shoulder lesions, it is the one that has received the most attention and remains the most mysterious. When it comes to the etiopathogenesis of the illness, various experts have come up with a number of alternative hypotheses, but the disease's actual nature has not yet been determined.

The bulk of the patients in our series, 36%, were between the ages of 50 and 60 years old, but the ages of the patients ranged anywhere from 25 to 80 years. In addition,(Davide Venturin et al., n.d.) and (Cao et

al., 2022) revealed that the age incidence was highest between the ages of 50 and 60 years. In series (Cao et al., 2022), People between the ages of 45 and 60 made up the majority of the population, but in series (Venturin et al., 2021), most people were between the ages of 50 and 54. The average age across all of our participants was 50.9 years.

The mean age was determined to be 52 years by both [3] and (Sajan et al., 2021), whereas (Venturin et al., 2021), found it to be 49.3 years. In the (Cao et al., 2022) study, the idiopathic group had a median age of 54 years, whereas the secondary group had a median age of 49 years. (Dwivedi, 2022), (Joshi, 2021), and (Lee et al., 2011) did not define any age group but noted it to be prevalent in middle age. (Dwivedi, 2022), did not specify any age group. The ages of the participants in the (Joshi, 2021) series varied from 18 to 74 years. Because of the sedentary nature of labor combined with degenerative changes in the tissues surrounding the shoulder joint, the condition seems to be rather frequent in senior individuals. Although the incidence was shown to be greater in females, the sex distribution in our series was not particularly noteworthy, despite the fact that females made up 58% of the sample. Our findings were consistent with those found in (Singh et al., 2019), and Booth (Singh et al., 2019), Marvel, and Codman all reported an incidence of between 60 and 65%. Females, in comparison to males, may move their arms and shoulders less, which may explain why they are more likely to be impacted by this condition than men. (Joshi, 2021), Merca and Duthie and Thakur discovered that men had a greater incidence of the disease. In men, the incidence of Wither's disease was as high as 72% in DePalma's cohort of patients. There is a divergence of view among a number of writers over which side of the shoulder is damaged, and each of these authors has provided an argument in support of their position. According to our investigation, the ratio of affection on the right side to that on the left side was 50:51, with one instance of affection being bilateral. (Kimmel, 2008) discovered that the left was more often engaged and hypothesized that this was because the leg was used less functionally. They (Demiris & Hayes, 2002) believe that overuse may be to blame for the involvement of the right shoulder in the condition. The 'Disuse' theory that Neirager and Conventry put up is invalidated in this respect. found a higher incidence of frozen shoulder on the right side, and he provided an explanation for his results by stating that men are more likely to experience trauma, and that the right shoulder is more likely to experience pressure. The patient's employment has a significant impact on the evolution of this clinical entity. Inevitably, those who do relatively little physical labor are the ones who are affected the most. Seventy-five percent of the people in our sample of one hundred were considered to be sedentary workers. This percentage comprised 39 housewives, many of whom were elderly and performed very little physical labor since they had other female family members to take care of the day-to-day operations of the household. The researchers Sinha and colleagues [4] found that sedentary employees had a prevalence of 94%. It seems that being exposed to trauma is a significant risk factor that may result in frozen shoulder. In our study, ten percent of the patients had some kind of damage to the limb that was afflicted at some point in time or another.

In their series, Sinha et al. observed that 22 percent of the subjects had a history of trauma. In the study of 72 patients that DePalma conducted, direct trauma (of a lesser severity) was found in 11 patients, and indirect trauma (injuries to the wrist, etc.) was found in 14 patients. Some disorders are considered to be related with a higher risk of developing frozen shoulder. In our series, the incidence of pulmonary TB, diabetes mellitus, and hypertension was 2% each, while the incidence of cervical spondylosis and myocardial infarction was 1% each correspondingly. Eighty-two patients did not have any predisposing factors and associated disorders. According to (Mitna et al., 2019) and (Kamm & Graf-Baumann, 2012), frozen shoulder syndrome is more prevalent when there is concomitant cardiovascular illness. [15] drew attention to the fact that frozen shoulder might develop as a subsequent consequence of myocardial infarction. He went on to explain that patients often suffer from significant chest discomfort in addition to referred pain that travels down the left arm and forearm in many situations. Frozen shoulder is a condition that develops as a consequence of this, in addition to the concern that any action would make the already severely injured heart worse. Because of the importance placed on bed rest in the treatment of patients with cardiovascular illnesses, pulmonary TB, and metabolic diseases, DePalma, Nevaizer, and many other researchers found that these conditions were associated with a higher prevalence of frozen shoulder. There is some evidence to support the hypothesis that diabetes mellitus and frozen shoulder are related. Bridgman discovered in his series of patients suffering from shoulder syndrome. According to references (Hui et al., 2012) and (Sun et al., 2001), cervical spondylosis is thought to be one of the primary causes of frozen shoulder. The symptomatology of frozen shoulder is rather distinctive, and the diagnosis of frozen shoulder hinges on the absence of both active and passive mobility, with the scapulothoracic joint being the only joint that allows any motion at all. In most cases, the patient is not examined until after the illness has become rather severe. The majority of the patients in our series (41%) reported between 2 and 4 months from the beginning of symptoms, with 4.3 months being the average length from the onset of symptoms. Only a minority (ten percent) of the patients reported themselves during the first two months. In the series conducted by Sinha et al., the average length was 4.62 months, the majority of patients (25%) entered the hospital between 4 and 5 months, and none reported having symptoms earlier than two months.

The condition always demonstrates the same pattern of recurring problems. Pain in the shoulder region, which might occasionally be accompanied by distal radiation, as well as a restriction of mobility to varying degrees, with abduction and rotation being the primary areas of concern, were the most prominent symptoms in our series. At times, the aching got so severe that resting on the afflicted side became very difficult and eventually impossible to do so. The majority of people said that pain kept them awake at night. Patients first became aware that they had the condition when they were unable to accomplish specific things that were formerly second nature to them, such as brushing their hair, putting on a shirt, hanging laundered clothing to dry, or reaching their pocketbook pocket.

After the illness had taken hold, it was usual for the limb that had been afflicted to become feeble. The intensity of the symptoms gradually and steadily worsened, and at the same time, the range of motion that could be performed without experiencing any discomfort at the scapula-humeral joint shrunk to the point where it could either hardly be moved at all or not move at all. Upon closer inspection, the atrophy of the deltoid and supraspinatus muscles may be seen, with the deltoid atrophy being the most noticeable. Only 15% of the patients in our collection did not have any soreness, while the remaining 85% did. Soreness was present across the acromion tip, the larger tuberosity of the humerus, the bicipital groove, and along the deltoid insertion, with the bicipital groove being the most prevalent location. Spasms of the muscles were found in the instances that were documented early on. Pain was present at the patients' ranges of motion in every case. There was no evidence of an increase in the temperature of the area or of any swelling in any of the instances. The clinical picture that DePalma describes sounds a lot like what is generally characterized as peri-arthritis of the shoulder or subacromial bursitis. According to his point of view, the start is often gradual, although it may sometimes be brought on by vigorous activities. Pain often begins in the front of the shoulder and radiates to the insertion of the deltoid muscle, and sensitivity may be provoked across the bicipital groove.

(Sun et al., 2001) discovered discomfort over the greater tuberosity and widespread sensitivity around the shoulder joint. Radiating pain was also seen reaching up to the neck in connection to the trapezius, to the occipital area, down the forearm, and to the wrist. According to Nevaizer, there are not any sites of discomfort around the shoulder joint as a general rule. It is possible for the patient to have a discomfort similar to a toothache deep in the region of the humeral head, and on occasion, there may be soreness along the long head of the biceps. This information is taken from (Asheghan et al., 2016). In our study of 109 patients, physiotherapy and pharmaceutical treatment were each used to treat 60 of the patients. The outcomes of the follow-up after 12 weeks were as follows: excellent in 25% of cases, good in 50% of cases, fair in 18.33% of cases, and bad in 6.66% of cases. After 12 weeks, the outcomes of intra-articular therapy coupled with physiotherapy and analgesics were excellent in 54.14% of the cases, good in 36.33% of the cases, and fair in 9.52% of the cases. Twenty patients were taken up for treatment. The outcomes of treatment that included manipulation in addition to intra-articular therapy and physiotherapy were quite positive: excellent in 85% of cases, good in 10%, and fair in 5%. The procedure was performed twice on two different patients. In our series of 20 instances that were modified, 7 cases had good outcomes after 4 weeks, 15 cases had excellent results within 8 weeks, and 17 cases had outstanding results within 12 weeks (Asheghan et al., 2016).

Only four out of twenty patients treated with intra-articular treatment saw outstanding outcomes in four weeks, nine patients did so in eight weeks, and twelve patients did so in twelve weeks.

Out of the 60 patients who were treated, none of them achieved outstanding outcomes after four weeks of physiotherapy, but three did after eight weeks, and 15 did after twelve weeks. When the outcomes of the various conservative treatments are compared, it is clear that manipulation under general anesthesia coupled with intra-articular therapy and physiotherapy is the way of choice since it produces positive results in a bigger number of patients in a much shorter amount of time.

Within three and a half months' time, (Zhang et al., 2021) treated a total of 26 patients in his series using physiotherapy with radiant heat. He was successful in restoring normal function and complete range of motion in 23 of the patients. Our series did not provide outcomes that were on par with those obtained by Withers when he was treated using physiotherapeutic methods. In the series of 963 instances that Harmon Paul (1958) examined, 929 of the patients (54.3% of the total) were manipulated, and immediate favorable benefits were noted in 90% of those cases. These cases included a quick snap and release to full passive range, and follow-up tests confirmed these findings. After two to three years of treatment, the patient underwent complete mobility without any discomfort in 64 to 94% of instances, with a lower proportion in patients older than 60 years of age and those with heart conditions. Physiotherapy was used to treat the remaining 367 patients, which accounts for 45.7%, and great outcomes were achieved in 75% of instances after a somewhat longer period of time.

In their study of 109 patients, Sinha et al. (1962) treated 25 of the patients with manipulation in conjunction with intra-articular injections. They found that this treatment produced outstanding outcomes in 80% of the patients and good results in 20%. The subsequent treatment that had good outcomes was a combination of physiotherapy and intra-articular hydrocortisone. 50 percent of the patients had great shoulders, 30 percent had decent shoulders, and 20 percent had bad shoulders. (Perez et al., 2010) is of the same view that manipulation is the therapy of choice, and his findings had been extremely gratifying

up to that point. The argument in (Perez et al., 2010) does not support manipulation, and the author has abandoned the practice. He suggests heat treatment along with systemic steroids for the physiotherapy. On the other hand, (Yoseph et al., 2021) suggests that the treatment of choice is a combination of physiotherapy and local injections of hydrocortisone into the affected area. In his study of 75 patients, (Yoseph et al., 2021) found that the combination of intra-articular treatment and manipulation produced the greatest outcomes. He found that intra-articular and periarticular infiltration of hydrocortisone and lignocaine produced the second-best results. Our findings with modification are strikingly comparable to those discovered by Withers and (Hung et al., 2004).

Keeping in mind that the condition (frozen shoulder) has a naturally self-limiting course, the amount of time it takes to heal becomes a primary consideration when evaluating the effectiveness of different conservative treatment options. The treatment that we believe to be most effective is one that combines manipulation with intra-articular injections of hydrocortisone and lignocaine. By injecting local anesthetics like lignocaine, such as may be done with Lignocaine, the pain factor, which was previously regarded to be severe following manipulation, can be significantly decreased. The administration of hydrocortisone into the joint helps prevent adhesions from reforming after they have been broken up by manipulation during the post-manipulative phase.

Epontol or thiopentone sodium was used to induce unconsciousness in the patients during the surgical procedure (Kamm & Graf-Baumann, 2012). It was observed that Epontol was more suited since it had a short acting time of three to five minutes, which is adequate for manipulating the shoulder. Additionally, there was no need for the patient to be hospitalized because they could go home shortly after the manipulation, and there were no adverse effects whatsoever that were seen after receiving this kind of anesthetic.

Conclusion

The Avabahuka ailment in Ayurveda is classified under the vata-vikar category.

Based on general observations, it appears that Ansha-shosha represents an early phase characterized by the presence of dryness in Shleshakkapha, while Avabahuka denotes a subsequent phase marked by the manifestation of symptoms and loss of Shleshakkapha. Avabahuka exhibits characteristics such as bahuprasandithara, shool, and stambha, which bear resemblance to Frozen Shoulder (FS), a contemporary musculoskeletal ailment affecting the shoulder joint. Risk factors for frozen shoulder include excessive physical labor, trauma to the shoulder region, and diabetes mellitus, among others. However, the precise etiology of this condition remains unclear. The FS undergoes three distinct stages, namely freezing, frozen, and thawing. The freezing stage typically lasts for a duration of 6-9 weeks, while the frozen stage spans over a period of 4-6 months. Finally, the thawing stage can last anywhere between 6 months to 2 years. Numerous conservative and operative approaches, such as the use of steroids, pain relievers (NSAIDs), physical therapy, and surgical intervention, are currently utilized for the treatment of FS. However, each of these methods has its own set of limitations.

The ancient Ayurveda texts contain a variety of treatment modalities such as Snehana, Swedana, Upnaaha, Nasya, Agnikarma, and others. The Agnikarma treatment is a commonly utilized method by clinicians for the treatment of Avabahuka. Furthermore, it yields satisfactory outcomes.

The efficacy of Agnikarma in alleviating the Vata and Kapha doshas, as described in Ayurvedic literature, has been demonstrated in cases of Avabahuka. Upon examination of articles obtained from both online and offline databases, it can be concluded that Agnikarma is a beneficial method for managing Avabahuka due to its ability to enhance the range of movement (ROM). Nineteen out of the 25 articles referenced the vata-kaphashamak. The efficacy of Agnikarma in alleviating pain and stiffness associated with Avabahuka conditions has been reported as satisfactory. The practice of Agnikarma is predominantly carried out by clinicians, with a particular emphasis on the utilization of Shalaka Agnikarma. The potential efficacy of utilizing Agnikarma as a clinical intervention for Avabahuka is encouraging. However, further empirical and clinical investigations are necessary to establish its validity and reliability.

References

1. Asheghan M, Aghda AK, Hashemi E, Hollisaz M. Investigation of the effectiveness of acupuncture in the treatment of frozen shoulder. *Materia Socio-Medica*. 2016;28(4):253.
2. Cao W, Chen J, Pu J, Fan Y, Cao Y. Risk factors for the onset of frozen shoulder in middle-aged and elderly subjects within 1 year of discharge from a hospitalization that involved intravenous infusion: a prospective cohort study. *Frontiers in Medicine*; c2022, 9.
3. Challoumas D, Biddle M, McLean M, Millar NL. Comparison of treatments for frozen shoulder: a systematic review and meta-analysis. *JAMA Network Open*. 2020;3(12):e2029581-e2029581.
4. Costa C, Sudarshan A. A comparative clinical study on the efficacy of Nasya with Pinyaka/Panchamula Taila and Swalpa Masha Taila in Apabahuka wsr to Frozen shoulder. *Journal of Ayurveda and Integrated Medical Sciences*. 2020;5(04):31-36.
5. Das B, Ganesh RM, Mishra PK, Bhuyan G. A study on Apabahuka (frozen shoulder) and its

- management by Laghumasha taila nasya. *Ayu*. 2010;31(4):488.
6. Davide Venturin FT, Brindisino F, Diego Ristori FT. (n.d.). Frozen shoulder (FS) is estimated to affect 2% to 5% of the general population, typically during the fifth and sixth decades of life.
 7. Demiris J, Hayes G. f 3 imitation as a dual-route process featuring predictive and learning components; 4 biologically plausible computational model. *Imitation in Animals and Artifacts*; c2002, 327.
 8. Dwivedi A. *Nasya Karma-A Unique Ayurveda Therapy*. BFC Publications; c2022.
 9. Hui SHI, Fang J, LI B, Cong W, Zhang Y, Lei C. Efficacy assessment for different acupuncture therapies in the treatment of frozen shoulder. *World Journal of Acupuncture-Moxibustion*. 2012;22(2):6-11.
 10. Hung PL, Chang WN, Huang LT. *Cardiovascular medicine. Current Opinion in Pediatrics*. 2004;16:585-613.
 11. Joshi L. *Nadivigyan Therapy for Frozen Shoulder (Adhesive Capsulitis): An Ancient Practice with Modern Relevance*; c2021.
 12. Kamm G, Graf-Baumann T. *Machame anaesthesia notebook for medical auxiliaries: with special emphasis on the developing countries*. Springer Science & Business Media; c2012.
 13. Kimmel M. *Properties of cultural embodiment: Lessons from the anthropology of the body*. *Body, Language and Mind*. 2008;2:77-108.
 14. Kumar M, Jaiswal R, Panigrahi H. The Role of Agnikarma in management of Avabahuka: A Case Report. *International Journal of AYUSH Case Reports*. 2022;6(4):364-370.
 15. Kumar M, Shinde RK, Reena J. Agnikarma Intervention for Avabahuka (Frozen Shoulder): A Systematic Review. (2022). *Int. J. Life Sci. Pharma Res*. 2019;12(6):L1-8.
 16. Kumar M, Shinde RK, Reena J. Agnikarma Intervention for Avabahuka (Frozen Shoulder): A Systematic Review.(2022). *Int. J Life Sci. Pharma Res*. 2021;12(6):L1-8.
 17. Laubscher PH, Rösch TG. Frozen shoulder: A review. *SA Orthopaedic Journal*. 2009;8(3):24-29.
 18. Lee YT, Yoon K, Kim YB, Chung PW, Hwang JH, Park YS, et al. Clinical features and outcome of physiotherapy in early presenting congenital muscular torticollis with severe fibrosis on ultrasonography: a prospective study. *Journal of Pediatric Surgery*. 2011;46(8):1526-1531.
 19. Mitna DN, Jakheria DS, Dubey DV, Lahiri DA, Singh DV. Evaluation of conservative treatment of frozen shoulder: A clinical study. *International Journal of Orthopaedics Sciences*. 2019;5(4):447-451. <https://doi.org/10.22271/ortho.2019.v5.i4h.1716>
 20. Negi V. Avabahuka vis-a-vis frozen shoulder: A review. *WJPR*. 2018;7:411-422.
 21. Perez RS, Zollinger PE, Dijkstra PU, Thomassen-Hilgersom IL, Zuurmond WW, Rosenbrand KCJ, et al. Evidence based guidelines for complex regional pain syndrome type 1. *BMC Neurology*. 2010;10(1):1-14.
 22. Pogorzelski J, Imhoff AB, Degenhardt H, Siebenlist S. Primäre (idiopathische) Schultersteife. *Der Unfallchirurg*. 2019;122(12):917-924.
 23. Rathod NA, Kuchewar VV. Review on role of Agnikarma in pain of various musculoskeletal disorders. *Journal of Indian System of Medicine*. 2019;7(1):43.
 24. Sajan A, Bagla S, Isaacson A. A review of musculoskeletal embolization to treat pain outside of the knee. *Seminars in Interventional Radiology*. 2021;38(05):515-517.
 25. Schelling, Wyss K, Bechir M, Moto DD, Zinsstag J. Synergy between public health and veterinary services to deliver human and animal health interventions in rural low income settings. *Bmj*. 2005;331(7527):1264-1267.
 26. Schultheis A, Reichwein F, Nebelung W. Frozen shoulder. *Diagnosis and therapy*. *Der Orthopade*. 2008;37(11):1065-1066.
 27. Singh S, Gehlot S, Agrawal NK. Basis of Disease Manifestation: A Molecular and Ayurvedic Approach with an Integrated Concept of Ayurgenomics. *J Nat. Remedies*. 2019;19(3):99-113.
 28. Sun KO, Chan KC, Lo SL, Fong DYT. *Acupuncture for frozen shoulder*; c2001.
 29. Tang H, Wei W, Yu T, Zhao Y. Physical therapy for the treatment of frozen shoulder: A protocol for systematic review of randomized controlled trial. *Medicine*. 2019;98(32).
 30. Tiwari M, Nigam P, Pandey A. The significant role of nasya in the management of avabahuka. *European Journal of Biomedical and Pharmaceutical Sciences*. 2015;2(4):1060-1066.
 31. Venturin D, Brindisino F, Ristori D, Rossi A, Vascellari A, Poser A. The Use of Corticosteroid/Anesthetic Injections in Conjunction With Physical Therapy in the Treatment of Idiopathic Frozen Shoulder: A Case Series. *JOSPT Cases*. 2021;1(4):248-265.
 32. Yoseph C, Avanti C, Hadiwidjaja M, Briliani K. The Importance of Fermented Active for Anti Aging incosmetics Product. *The Importance of Fermented Plant Extract for Anti Aging Incosmetics Product*. 2021;10(8):1330-1343.
 33. Zhang J, Zhong S, Tan T, Li J, Liu S, Cheng R, et al. Comparative efficacy and patient-specific moderating factors of nonsurgical treatment strategies for frozen shoulder: an updated systematic review and network meta-analysis. *The American Journal of Sports Medicine*. 2021;49(6):1669-1679.