

Negative Appendectomy Rate – Role of Alvarado Score and CT scan, A Prospective study in VIMSAR, Odisha

¹Dr. Himansu Shekhar Mishra, ²Dr. Abinasha Mohapatra*

1. Assistant Professor, Department of General Surgery, Shri Jagannath Medical College and Hospital, Puri, Odisha, India, 752002.

2. Assistant Professor, Department of General Surgery, Veer Surendra Sai Institute of Medical Science And Research(VIMSAR), Burla, Sambalpur, Odisha, India, 768017.*

Corresponding Author –Dr. Abinasha Mohapatra

ABSTRACT :

Objective: The objective of our study is to study the impact of combined use of Alvarado score and CT scan on Negative Appendectomy Rate.

Materials and methods: This prospective observational study comprising of patients presenting with clinical features of appendicitis admitted to department of general surgery, VIMSAR, Burla from November 2021 to October 2022, where Alvarado score and USG findings are mismatching each other. Alvarado scores calculated and categorized in 2 groups as negative (score <4) and positive (score ≥4). These patients were also subjected to USG and categorized as negative (USG –ve) and positive (USG +ve). Those patients having discrepancy in both the findings were subjected to CT scan. On histopathological examination, inflamed appendix in 63(97%) patients and non-inflamed in 2 (3%) Rest patients were either discharged (both –ve) or operated (both +ve).

Result: Total 84 patients showed discrepancy between Alvarado score and USG findings and are subjected to CT scan abdomen and pelvis. CT scan was positive for appendicitis in 65 cases (where appendectomy done) and negative for appendicitis in 19 cases (where the diagnosis is different).patient . Thus Negative Appendectomy NAR) is 3% in our study.

Conclusion: Alvarado score and Ultrasonography could not be used as absolute tool in doubtful and equivocal cases, where combined use of CT scan with Alvarado score and USG has definitely has an edge by diagnosing the differentials and reducing negative appendectomy followed by reduction in cost and length of hospital stay.

Key words- Alvarado score, CT Scan, USG, Negative Appendectomy Rate (NAR), Impact indicator

INTRODUCTION :

Acute appendicitis is one of the most common cause of acute abdomen which requires surgical intervention, with a life time risk of 6.7% in females and 8.6% in males¹. Historically, negative appendectomy rate of 15-25 % were considered acceptable^{2,3}. However, this is no longer acceptable because even though complication rates in the setting of negative appendectomy are low, can result in other comorbidities such as incisional hernias, intestinal obstruction secondary to adhesion and stump leaks^{4,5}.

Proper use of CT scan has improved the correct diagnosis of appendicitis over USG, Alvarado score and clinical judgement^{6,7,8}. NAR has been decreased from 20 -40 % for women in the pre CT era to as low as 7 % in women and 4-4.7 % overall^{9,10,11,12}.CT is thus credited with lowering NAR, but a proper protocol of its use is lacking.

AIM AND OBJECTIVES :

This study aimed to evaluate the performance statistics of combined use of Alvarado score and CT scan in addition to USG. Therefore we attempt to use the AS and USG to classify patients, for whom CT can be useful in diagnosing acute appendicitis and reduce NAR.

MATERIALS AND METHOD :

Place of study- Dept. of General Surgery, Veer Surendra Sai Institute of Medical Science And Research (VIMSAR), Burla, Sambalpur, Odisha, India, PIN- 768017

Period of study- November 2021 to October 2022.

Study design- Prospective study.

Study population-

Inclusion criteria-All patients presenting with clinical features of appendicitis admitted to department of general surgery, VIMSAR, Burla ,where Alvarado score and USG findings are mismatching each other.

Exclusion criteria- Pregnant women, patients allergic to contrast material

Sample size- 84

Sampling technique-The subjects will be selected from patients admitted to general surgery ward as provisional diagnosis of Appendicitis where the clinical and USG findings are not matching each other.

Methodology-

All patients admitted to VIMSAR ,Burla from November 2021 to October 2022 who underwent CT scan abdomen for mismatch in finding between Alvarado score and CT scan in suspected appendicitis, were enrolled in to the study .For each patients ,symptoms, signs and laboratory results were recorded and graded with the Alvarado score and performance of USG abdomen done .In patients having discrepancy in findings were subjected to CT scan abdomen. CT scan finding is considered positive if read as, Consistent with, compatible with, demonstrating acute appendicitis, enlarged and swollen appendix, can not exclude appendicitis. CT scan finding considered negative if read as, negative for appendicitis or normal appendix. Equivocal finding in USG is considered when appendix was not visualized but still had probe tenderness in the right iliac fossa region in the absence of any other pathology or when acute appendicitis was not ruled out. Alvarado score of ≥ 4 were considered significant in considering appendicitis.

Subjects having discrepancy in finding in USG and Alvarado score are subjected to CT scan and in positive cases appendectomy performed and specimen sent for histo-pathological examination. Subjects where histo-pathological finding is non-inflamed appendix are considered Negative appendectomy specimen.

Finally the statistical tests, such as sensitivity, specificity, positive predictive value, negative predictive value and diagnostic accuracy, were performed for the combined approach and negative appendectomy rate was calculated.

OBSERVATION :

A total 942 patients presented to surgery OPD and Emergency department for suspected appendicitis. Alvarado score was calculated followed by USG abdomen and pelvis. In 84 cases there was discrepancy between USG finding and Alvarado score. Those 84 cases are subjected to contrast enhanced

CT scan abdomen and pelvis.

CT scan was positive for appendicitis in 65 cases and negative for appendicitis in 19 cases, where the diagnosis is different. In those 65 cases appendectomy was performed. Laparoscopy in 48 cases and open method in 17 cases. In 10 cases appendix was looking macroscopically normal. As a standard protocol appendectomy was performed in all cases. The specimens were sent for histo-pathological examination. Appendix was found to be inflamed microscopically in 63(97%) patients and non-inflamed in 2 (3%) patients. Thus Negative appendectomy rate(NAR) is 3% in our study.

Length of hospital stay

Range was from 2 to 7 days.

Mean duration of stay is 4 days with a standard deviation of 1.25.

Table No. 1 :Type of operation

| Type of operation | Number | Percentage |
|-------------------|--------|------------|
| Laparoscopy | 48 | 74% |
| Open | 17 | 26% |
| Total | 65 | 100% |

Out of 65 operated cases, 48 underwent laparoscopic appendectomy and 17 underwent open appendectomy.

Alvarado scoring

Out of 942 cases evaluated, Alvarado score was calculated for all patients. Score was more than or equal to 4 in 738 patients and USG was positive in 782 patients. There was mismatch between two findings in 84 patients. These 84 patients were subjected to CT scan and found to be positive of appendicitis in 65 patients and alternative diagnosis in 19 patients. Among those 65 patients HPE was positive for Appendicitis in 63 patients and in 2 patients appendix was not inflamed. So NAR is 3%.

Table No. 2 :Prevalence of various clinical and laboratory parameters in acute appendicitis patients

| Clinical parameters | % in acute appendicitis | Number |
|---------------------|-------------------------|--------|
| MIGRATORY RIF PAIN | 38.09 | 32 |
| ANOREXIA | 50.00 | 42 |
| NAUSEA/VOMITING | 39.28 | 33 |
| RIF TENDERNESS | 51.19 | 43 |
| REBOUND TENDERNESS | 55.95 | 47 |
| FEVER | 40.47 | 34 |
| LEUKOCYTOSIS | 46.42 | 39 |
| SHIFT TO LEFT | 47.61 | 40 |

Table No. 3 : CT scan findings in our patients

| CT scan findings | Number of patients |
|------------------|--------------------|
|------------------|--------------------|

| | |
|-----------------------------|----|
| Acute appendicitis | 65 |
| Diverticulitis | 7 |
| Ileo-colitis | 3 |
| Pelvic inflammatory disease | 2 |
| Ruptured ovarian cyst | 1 |
| Polycystic ovary | 1 |
| Caecal malignancy | 1 |
| Renal calculi | 1 |
| Biliary calculi | 1 |
| Meckel's diverticulum | 1 |
| Epiploic-appendagitis | 1 |
| Total | 84 |

Table No. 4 :Histopathology findings of specimens

| | |
|-----------------------|--------------------|
| HPE findings | Number of patients |
| Inflamed Appendix | 63 |
| Non inflamed Appendix | 2 |
| Total | 65 |

Table No. 5 :USGVs HPE study

| | | | |
|-------|-------|-------|-------|
| | HPE + | HPE - | TOTAL |
| USG + | 32 | 1 | 33 |
| USG - | 31 | 1 | 32 |
| TOTAL | 63 | 2 | 65 |

*Sensitivity- 50.7%,

*Specificity- 50%,

*PPV- 96.9%,

*NPV- 3.1%, *

Diagnostic accuracy- 50.7%

Table No. 6 :Alvarado score Vs HPE study

| | | | |
|----------|-------|-------|-------|
| | HPE + | HPE - | TOTAL |
| Score ≥4 | 33 | 1 | 34 |
| Score <4 | 30 | 1 | 31 |
| Total | 63 | 2 | 65 |

*Sensitivity- 52.3% ,

*Specificity- 50%,

*PPV- 97.0%,

*NPV- 3.2%, *Diagnostic accuracy- 52.3%.

* As we have excluded a majority of patients with matching score of USG and Alvarado score (both +ve and both –ve), our statistical values are not matching with the previous literatures.

Table No. 7 :USGVs CT scan

| | CT + (Those with appendicitis on CT) | CT - (Those without appendicitis on CT) | Total |
|-------|--------------------------------------|---|-------|
| USG + | 33 | 10 | 43 |
| USG - | 32 | 9 | 41 |
| TOTAL | 65 | 19 | 84 |

Out of 43 USG positive patients, 33 (76.7%) were positive on CT scan and 10 (23.2%) were negative on CT scan.

Out of 41 USG negative patients, 9 (21.9%) were negative on CT scan and 32 (78%) were positive on CT scan.

As the p-value is 0.44, the difference in findings are statistically not significant.

Table No. 8 :AlvaradoVs CT scan

| | CT + (Those with appendicitis on CT) | CT - (Those without appendicitis on CT) | TOTAL |
|--------------|--------------------------------------|---|-------|
| Alvarado ≥ 4 | 34 | 7 | 41 |
| Alvarado <4 | 31 | 12 | 43 |
| TOTAL | 65 | 19 | 84 |

Out of 41 patients with Alvarado score ≥4, 34 (82.9%) were positive on CT scan and 7 (17%) were negative on CT scan.

Out of 43 patients with Alvarado score <4, 12(27.9%) were negative on CT scan and 31 (72%) were positive on CT scan.

As the p-value is 0.11, the difference in findings are statistically not significant.

DISCUSSION :

Physical examination, laboratory or radiological investigations, clinical suspicion and experience can lead to an accurate diagnosis of acute appendicitis. Accurate diagnosis is essential keeping in the mind of negative appendectomy, which leads to unnecessary morbidity and cost. Due to which various modalities were evaluated to supplement judgment in improving diagnostic accuracy among which Alvarado score, USG and CT scan are the modalities which we have used. Using CT scan it is possible to confirm appendicitis and exclude other causes which mimic it.

The Alvarado score of 1-3 points is considered as no risk of appendicitis, patients with a score of 4-6 require either observation or additional work-up, while patients with a score higher than 7 are considered as AA. Acute appendicitis can be correctly diagnosed in 70% of patients by using Alvarado scoring alone ¹⁶. NARs using ‘clinical judgment’ have been as high as 17–36%^{14,15}. With its inherent discipline, the Alvarado score has produced acceptable NARs of <8^{16,17} making it a valuable tool either for screening or as an alternative to CT or ultrasonography.

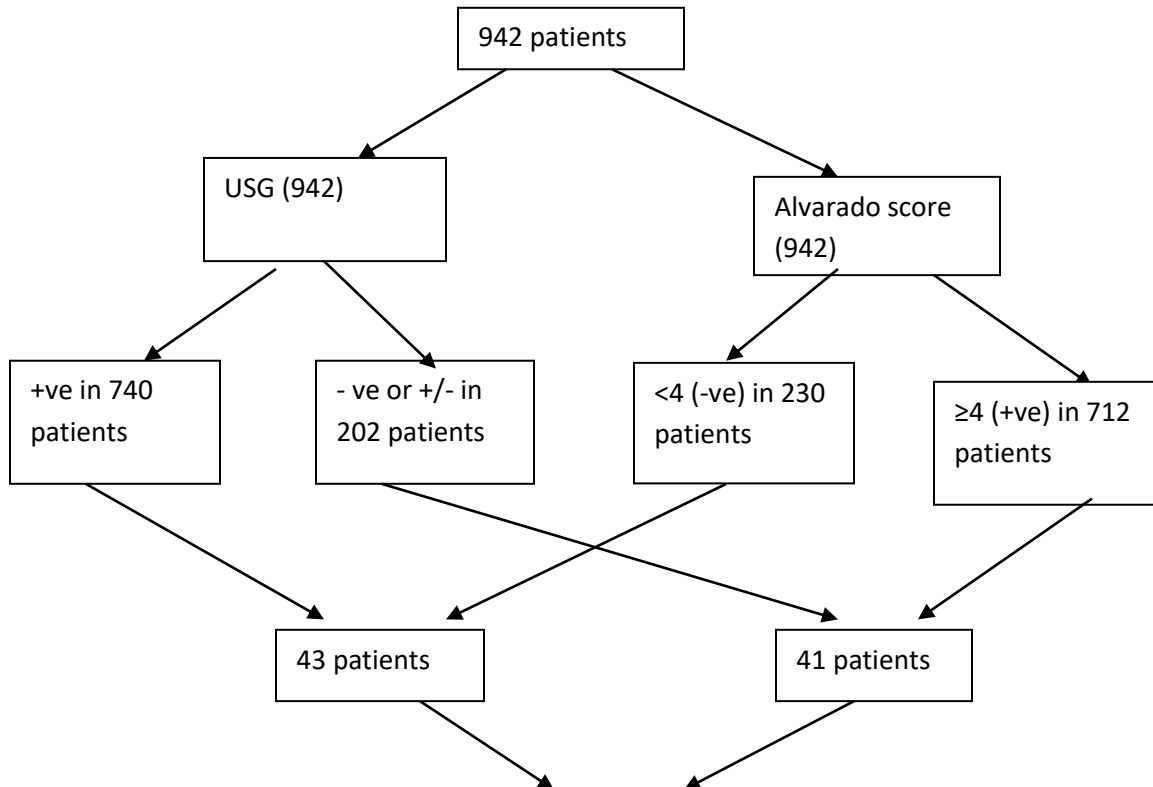
Petros Yanet *al*¹⁸: incorporated Alvarado scores and CT into the management of 1,630 patients with right lower quadrant pain and suspected appendicitis. 16 CT was performed in 56%, sparingly for

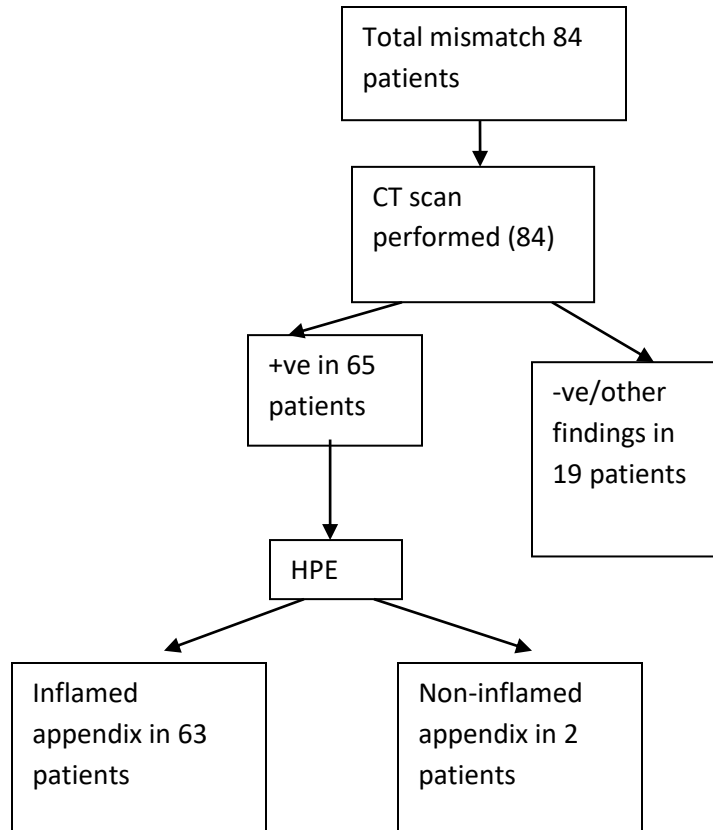
Alvarado scores of 8–10, somewhat more frequently for scores of ≤ 4 and commonly for scores of 5–7. The overall NAR was 6%, regardless of whether CT was performed or not. The biggest impact of CT was on the Alvarado 5–7 group, where the addition of CT reduced the NAR from 6.2% to 3.3%. In the prospective study of Antevilet *al*¹⁹, a reduction in NAR from 16% to 4% was achieved after implementing a pathway that included early surgical evaluation and CT for all female patients and only male patients with low suspicion for acute appendicitis¹⁹. Despite Alvarado scoring, imaging methods such as ultrasound (US) and computed tomography (CT) are utilized to avoid an unnecessary appendectomy and diagnose AA before perforation.

According to study conducted by Tan et al¹², patients with Alvarado score 3 and below were considered to be not having appendicitis and discharged and followed up as outpatients. Using AS cutoff value of < 4 to exclude acute appendicitis has an overall sensitivity of 94.2%. According to this study, we have assumed we cannot deny appendicitis in patients having $AS \geq 4$. In our study we have used $AS \geq 4$ as positive and < 3 as negative finding.

We also performed USG and Alvarado scoring in all our 942 patients. USG was positive in 740 patients and negative in 202 patients. Alvarado score was ≥ 4 in 712 patients and < 4 in 230 patients. Cases where Alvarado score is < 4 and USG is negative, are being discharged with regular follow-up. Cases where Alvarado score ≥ 4 and USG is positive are being operated. These two categories of patients are not included in our study. Cases where $AS \geq 4$ with negative USG (41 cases) and $AS < 4$ with positive USG (43 cases) are included in our study. Total 84 patients were selected and CT scan was performed. 65 patients were positive for appendicitis and 19 patients were diagnosed with other conditions, who were managed according to their pathology. Appendectomy was performed in all 65 patients. HPE positive for appendicitis in 63 patients and in 2 patients appendix was non inflamed. In our study negative appendectomy rate was 3%.

Figure : Algorithmic overview of our study





In our study sensitivity ,specificity, positive predictive value, negative predictive value for USG was 50.7%, 50.0%,96.9%,3.1% respectively and for Alvarado score these values were 52.3%, 50.0%, 97.0%, 3.2% respectively. These values were not similar as other studies because we have excluded a majority of cases from the total admitted presenting as appendicitis. Out of 942 suspected cases of appendicitis, we have chosen only 84 cases, which were of doubtful significance of having appendicitis, where the USG finding and Alvarado score was mismatched, were subjected to CT scan. Rest 858 cases were either discharged with follow up or operated immediately.

Often retrocecal and high up paracolic appendicitis may be missed in USG but can be picked up correctly in CT scan. More ever many alternative conditions, which mimic Appendicitis can be easily be identified in CT scan.

According to a study conducted by Joshua and et al ²⁰patients who proceeded to surgery without imaging had a NAR of 19.2%. In comparison, patients who proceeded to surgery with one or more imaging studies had a NAR of 3.5%. A single US, CT, or MRI had a NAR of 9.7%, 2.5%, and 7.1%, respectively. If the US, CT or MRI result was consistent with appendicitis, the NAR were lower at 4.8%, 1.3%, and 2.3%, respectively . However, if the result was indeterminate or negative, the negative appendectomy rates were 32.9%, 26.7%, and 14.8%, respectively .Study published by JG Mariadason et al ¹³ showed Negative appendectomy rate around 3% after use of CT scan, which was around 10% before use of CT scan

In our study, we proposed an algorithm to use their combined use and evaluated negative appendectomy rate. Use of CT scan in addition to USG and Alvarado score in doubtful cases resulted in decrease in negative appendectomy rate(3%) which was earlier accepted as 20%.

CONCLUSION :

Acute appendicitis is a common problem with difficult diagnosis in many instances in extremes of ages and in women of child bearing ages. In that situations combined approach of radiological and clinical score can add accuracy to the diagnosis. Alvarado score is a simple diagnostic tool which gives comparable result to Ultrasonography when it comes to diagnosis of appendicitis. As we observed no major statistical difference between these two, neither of the two could be used as absolute tool in reducing negative appendectomy rate in doubtful and equivocal cases. In such cases CT is used to evaluate further and exclude other causes. CT scan not required in all cases, when there is discrepancy in finding of Alvarado score and USG, it is required. Thus it improves diagnostic accuracy. Thus in terms of cost benefit analysis selective combined use of Alvarado score and CT scan with USG has definitely has an edge by diagnosing the differentials and reducing negative appendectomy followed by reduction of cost and length of hospital stay.

DECLARATIONS

Funding: Department of Surgery, Veer Surendra Sai Institute of Medical Science And Research (VIMSAR), Burla, Sambalpur, Odisha, India, PIN - 768017

Conflict of interest: No

Ethical approval ; Taken

References-

1. Birnbaum BA, Wilson SR. Appendicitis at the millennium. *Radiology* 2000;215:337e348.
2. Colson M, Skinner KA, Dunnington G. High negative appendectomy rates are no longer acceptable. *Am J Surg.* 1997;174(6):723e726. discussion 726-727.
3. Lewis FR, Holcroft JW, Boey J, Dunphy E. Appendicitis. A critical review of diagnosis and treatment in 1,000 cases. *Arch. Surg. (Chicago, Ill: 1960).* 1975;110(5):677e684.
4. Velanovich V, Satava R. Balancing the normal appendectomy rate with the perforated appendicitis rate: implications for quality assurance. *Am Surg.* 1992;58(4):264e269.
5. Raja AS, Wright C, Sodickson AD et al. Negative appendectomy rate in the era of CT: an 18-year perspective. *Radiology* 2010; 256: 460–465.
6. Doria AS, Moineddin R, Kellenberger CJ, Epelman M, Beyene J, Schuh S, Babyn PS, Dick PT (2006) US or CT for diagnosis of appendicitis in children and adults? A meta-analysis. *Radiology* 241(1):83–94. doi:10.1148/radiol.2411050913
7. Kim K, Rhee JE, Lee CC, Kim KS, Shin JH, Kwak MJ, Kim JH, Suh GJ, Hahn SK, Singer AJ (2008) Impact of helical computed tomography in clinically evident appendicitis. *EmergMed J* 25(8):477–481. doi:10.1136/emj.2006.044552
8. Tsao KJ, Peter SDS, Valusek PA, Spilde TL, Keckler SJ, Nair A, Ostlie DJ, Holcomb GW (2008) Management of pediatric acute appendicitis in the computed tomographic era. *J Surg Res* 147(2):221– 224. doi:10.1016/J.Jss.2008.03.004

9. Lewis FR, Holcroft JW, Boey J, Dunphy E (1975) Appendicitis. A critical review of diagnosis and treatment in 1,000 cases. *Arch Surg* 110(5):677–684
10. Bendeck SE, Nino-Murcia M, Berry GJ, Jeffrey RB Jr (2002) Imaging for suspected appendicitis: negative appendectomy and perforation rates. *Radiology* 225(1):131–136. doi:10.1148/radiol.2251011780
11. Balthazar EJ, Rofsky NM, Zucker R (1998) Appendicitis: the impact of computed tomography imaging on negative appendectomy and perforation rates. *Am J Gastroenterol* 93(5):768–771. doi:10.1111/j. 1572-0241.1998.222_a.x
12. Winson Jianhong Tan, Sanchalika Acharyya, Yaw Chong Goh, Weng Hoong Chan, Wai Keong Wong, London Lucien Ooi, Hock Soo Ong (2015), Prospective Comparison of the Alvarado Score and CT Scan in the Evaluation of Suspected Appendicitis: A Proposed Algorithm to Guide CT Use. doi:10.1016/j.jamcollsurg.2014.10.010
13. JG Mariadason, WN Wang, MK Wallack, A Belmonte, H Matari (2012): Negative appendectomy rate as a quality metric in the management of appendicitis: impact of computed tomography, Alvarado score and the definition of negative appendectomy. doi 10.1308/003588412X13171221592131
14. Mohebbi HA, Mehrvarz S, Kashani MT et al. Predicting negative appendectomy by using demographic, clinical, and laboratory parameters: a cross-sectional study. *Int J Surg* 2008; 6: 115–118.
15. Das MK, Gautam D, Roy H et al. Unnecessary appendectomy in suspected cases of acute appendicitis. *J Indian Med Assoc* 2009; 107: 354, 356–357.
16. Subotic AM, Sijacki AD, Dugalic VD et al. Evaluation of the Alvarado score in the diagnosis of acute appendicitis. *Acta Chir Iugosl* 2008; 55: 55–61.
17. Alvarado A. A practical score for the early diagnosis of acute appendicitis. *Ann Emerg Med*. 1986;15(5):557–564.
18. Petrosyan M, Estrada J, Chan S et al. CT scan in patients with suspected appendicitis: clinical implications for the acute care surgeon. *Eur Surg Res* 2008; 40: 211–219.
19. Antevil JL, Rivera L, Langenberg BJ et al. Computed tomography-based clinical diagnostic pathway for acute appendicitis: prospective validation. *J Am Coll Surg* 2006; 203: 849–856.
20. Joshua Tseng, Tara Cohen, Nicolas Melo, Rodrigo F. Alban, Imaging utilization affects negative appendectomy rates in appendicitis : An ACS-NSQIP study, doi: 10.1016/j.amjsurg.2018.12.072