Journal of Cardiovascular Disease Research

ISSN:0975 -3583,0976-2833 VOL14, ISSUE 11, 2023

A RETROSPECTIVE STUDY ON HISTOPATHOLOGICAL SPECTRUM OF LEPROSY IN A TERTIARY CARE CENTER AT GWALIOR REGION

FIRST AUTHOR - DR. SUNITA RAI
(ASSISTANT PROFESSOR, DEPARTMENT OF PATHOLOGY, GAJRA RAJA MEDICAL COLLEGE, GWALIOR)
SECOND AUTHOR- DR. NAVEENA BANSAL
(JR-3, DEPARTMENT OF PATHOLOGY, GAJRA RAJA MEDICAL COLLEGE, GWALIOR)
THIRD AUTHOR- DR. VIPIN KUMAR PARIHAR
(JR-3, DEPARTMENT OF PATHOLOGY, GAJRA RAJA MEDICAL COLLEGE, GWALIOR)
CORRESPONDING AUTHOR- DR. SUDHA IYENGAR
(PROFESSOR, DEPARTMENT OF PATHOLOGY, GAJRA RAJA MEDICAL COLLEGE, GWALIOR)
DR. RAJESH GAUR
(PROFESSOR AND HEAD, DEPARTMENT OF PATHOLOGY, GAJRA RAJA MEDICAL COLLEGE, GWALIOR)

ABSTRACT

BACKGROUND: Leprosy, Hansen's disease, is a chronic granulomatous infectious disease caused by Mycobacterium leprae. It is a slowly progressive, chronic infectious disease which mainly affects peripheral nerve and skin.

AIMS AND OBJECTIVES: This article aims to study the various histological types of leprosy in a tertiary care hospital.

MATERIALS AND METHODS: It was a retrospective study carried out from January 2021 to September 2023. A series of 109 clinically suspected skin lesions of leprosy were examined histopathologically.

RESULTS: In our study, out of the 109 cases the most common histopathological type of leprosy was borderline tuberculoid i.e. 43 cases (39.4%). 2nd most common type in our study was tuberculoid type which included 16 cases (14.6%). Borderline borderline type had 11 cases (10.0%), lepromatous type 14 cases (12.8%), indeterminate 14 cases (12.8%) and histoid type 2 cases (1.8%).

CONCLUSION: The spectrum of leprosy presentation is very wide. The findings in our study were more common in males and present mostly in the 21 to 40 years of life. Most common histopathological finding was borderline tuberculoid type.

KEYWORDS: LEPROSY, HISTOPATHOLOGY, BORDERLINE TUBERCULOID, SKIN BIOPSIES.

INTRODUCTION

Leprosy, Hansen's disease, is a chronic granulomatous infectious disease caused by Mycobacterium leprae. It is a slowly progressive, chronic infectious disease which mainly affects peripheral nerve and skin which can express itself in different clinicopathological forms depending on immune status of host.(1)Depending on degree of immunity, clinical and histopathological features various types of leprosy gradually may develop.(2)With developed programmes and unified approach there have been substantial reduction in the disease burden but leprosy is still one of the major public health problem in India. In the absence of

ISSN:0975 -3583,0976-2833 VOL14, ISSUE 11, 2023

treatment leprosy tends to be progressive and can cause permanent damage to skin, nerves, limbs and eyes leading to disfigurement. Hence, histopathological examination remains a cornerstone in the diagnosis and appropriate management of this disease. (3)
Leprosy mainly affects the skin, causing lesions and
anaesthesia, along with enlarged and thickened peripheral nerves. (4) It has different histopathological forms depending on the immunity of the patient. (5) The Ridley-Jopling classification is the most widely used and divides the disease into tuberculoid (TT), borderline tuberculoid (BT), mid-borderline (BB), borderline lepromatous (BL) and lepromatous leprosy
(LL), based on clinical, immunological and histomorphological factors. (6) Indeterminate forms include types that do not fit into any of the five categories. Histoid leprosy is an uncommon type of LL that shows nodules or plaques over apparently normal skin. (7)

AIM

This article aims to study the various histological types of leprosy in a tertiary care hospital.

MATERIAL AND METHOD

A retrospective study was conducted in Department of Pathology, Gajra Raja Medical College, Gwalior over a period of 2 years 9 months (January 2021 to September 2023). Clinically diagnosed patients of leprosy of all age groups and both sexes were included. A 3 mm lesional skin punch biopsies obtained by dermatologists. These biopsies were formalin-fixed, routinely processed and stained with H&E. The lesions were graded as per the Ridley-Jopling classification into tuberculoid leprosy, borderline tuberculoid, borderline, borderline lepromatous and lepromatous leprosy. A new variant of leprosy was described by Wade, known as Histioid leprosy [11]. Indeterminate forms include types that do not fit into any of the five categories.

Inclusion criteria:

- All age group patients who are clinically suspected cases of leprosy willing to participate in the study.

Exclusion criteria**:**

- Autolysed / Inadequate Specimen

RESULTS

Total 109 cases were studied for a period of 2 and half years from January 2021 to September 2023. Leprosy cases were more common among men as compared to women in our study with a M:F ratio of 2.9:1. The age of patients varied from 11 to 80 years, with a maximum number of patients being between age group 21 to 40 years. On histopathological examination, epidermal and dermal changes were noted in the skin biopsies. Epidermal changes noted were presence or absence of atrophy, hyperplasia, hyperkeratosis, ulceration, orthokeratosis, spongiosis and acanthosis. Dermal changes noted were presence or absence of Grenz zone, perineural and perivascular inflammatory infiltrate, well-formed or ill-formed epithelioid cell granulomas, Langhans giant cells and foamy histiocytes.

ISSN:0975 -3583,0976-2833 VOL14, ISSUE 11, 2023

TABLE 1: AGE DISTRIBUTION

SL.NO.	AGE GROUP	NUMBER OF CASES	PERCENTAGE
1.	0-10	-	-
2.	11-20	12	11.0%
3.	21-30	18	16.5%
4.	31-40	32	29.3%
5.	41-50	17	15.6%
6.	51-60	12	11.0%
7.	61-70	15	13.7%
8.	>70	03	2.7%
	TOTAL	109	100%

- Majority belonged to the age group of 21 to 40 years.
- >60 years had 18 cases were as 12 cases were in < 20 years.

FIGURE 1: GENDER DISTRIBUTION

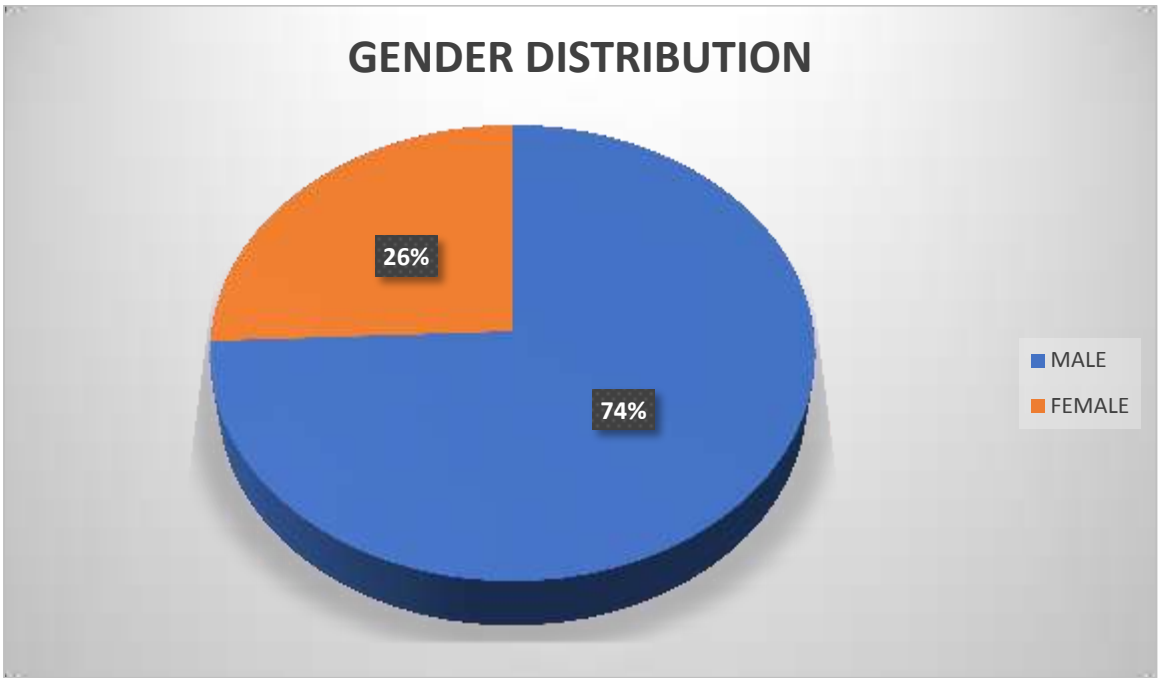

- Male patients predominated with male to female ratio of 2.9:1.

ISSN:0975 -3583,0976-2833 VOL14, ISSUE 11, 2023

TABLE 2: HISTOPATHOLOGICAL SPECTRUM

SL.NO	HISTOPATHOLOGICAL DIAGNOSIS	NO. OF CASES	PERCENTAGE
1	TUBERCULOID (TT)	16	14.6%
2	BORDERLINE TUBERCULOID(BT)	43	39.4%
3	BORDERLINE BORDERLINE(BB)	11	10.0%
4	BORDERLINE LEPROMATOUS(BL)	09	08.3%
5	LEPROMATOUS (LL)	14	12.8%
6	INDETERMINATE HANSEN'S(IL)	14	12.8%
7	HISTOID LEPROSY(HL)	02	01.8%
	TOTAL	109	100%

- In our study, most common histopathological lesion of leprosy was borderline tuberculoid type i.e. 43 cases (39.4%).
- 2nd most common type in our study was tuberculoid type which included 16 cases (14.6%).
- Borderline borderline type had 11 cases (10.0%) were as lepromatous type had 14 cases (12.8%).
- Indeterminate and histoid type included 14 cases (12.8%) and 2 cases (1.8%) respectively.

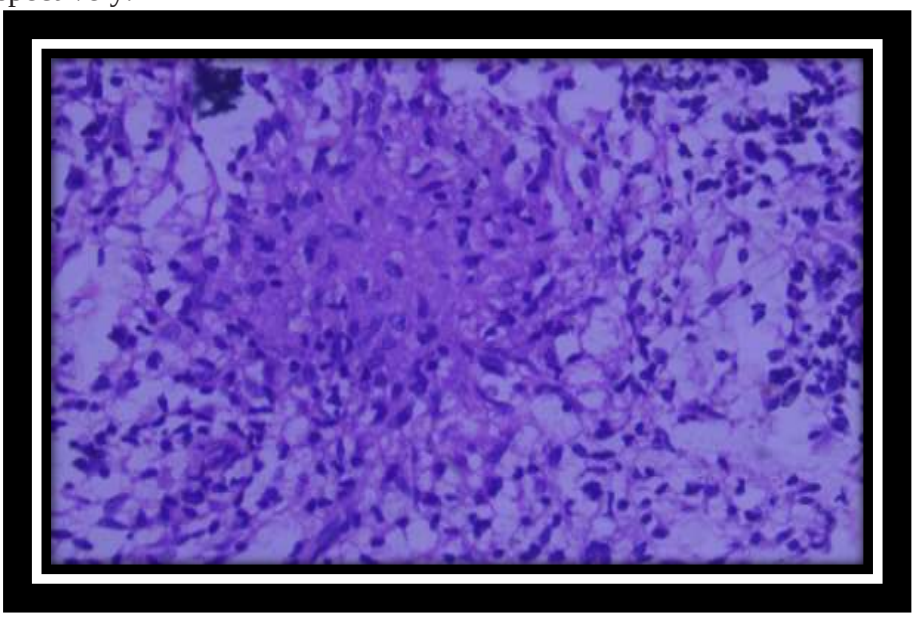

FIGURE 2: Borderline Tuberculoid (BT) Hansen's Disease showing ill formed granuloma surrounded by lymphocytes (40x)

ISSN:0975 -3583,0976-2833 VOL14, ISSUE 11, 2023

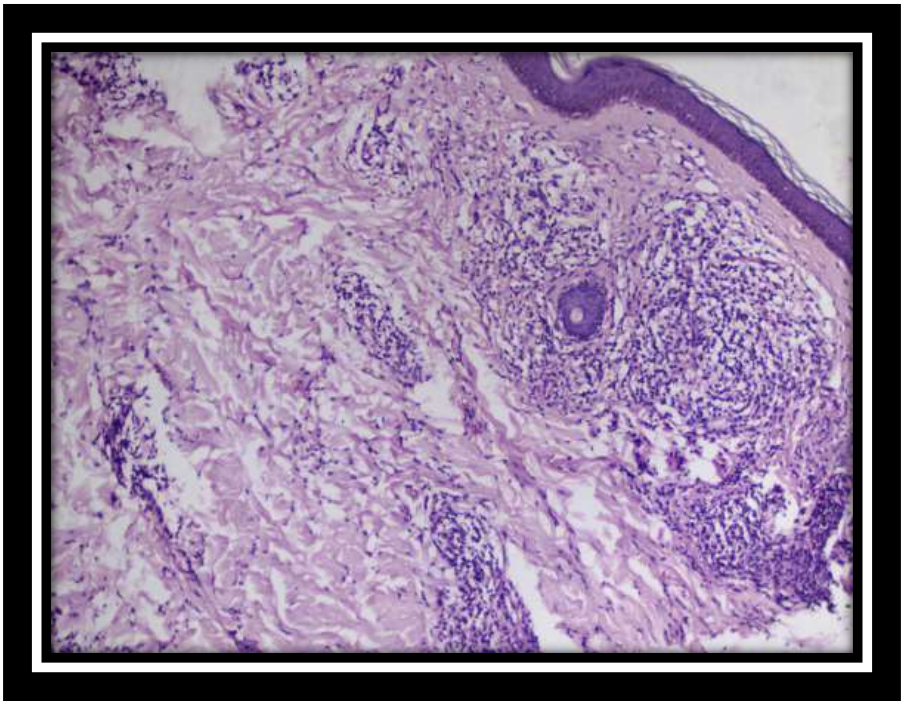

FIGURE 3: Tuberculoid (TT) Hansen's disease showing well formed granuloma (10x)

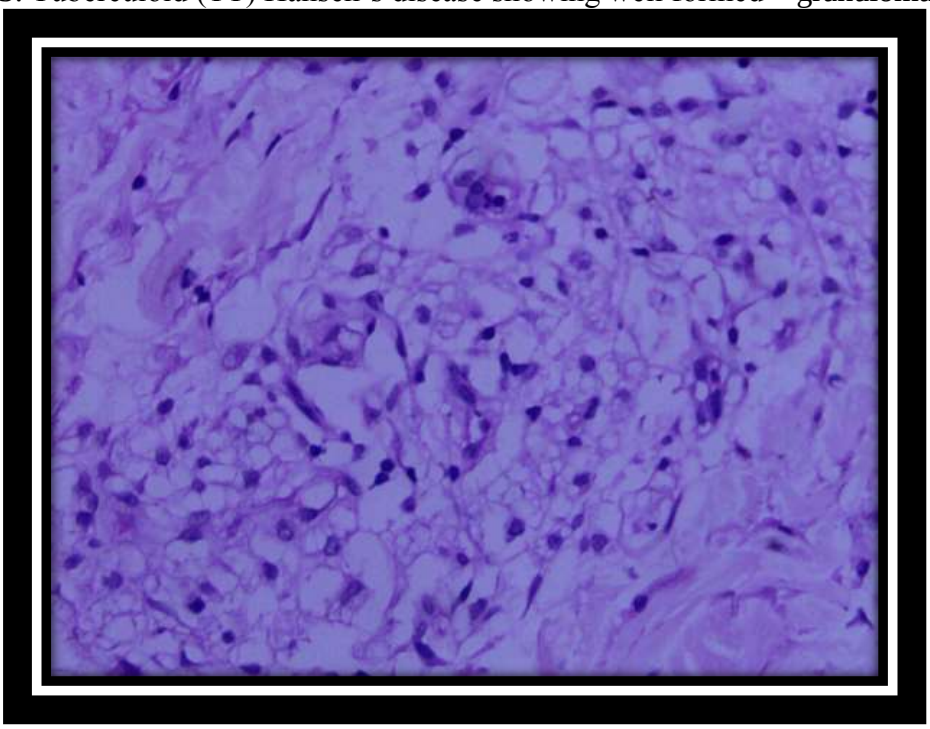

FIGURE 4: Lepromatous Hansens's disease (LL) showing diffuse infiltration of macrophages (40x)

ISSN:0975 -3583,0976-2833 VOL14, ISSUE 11, 2023

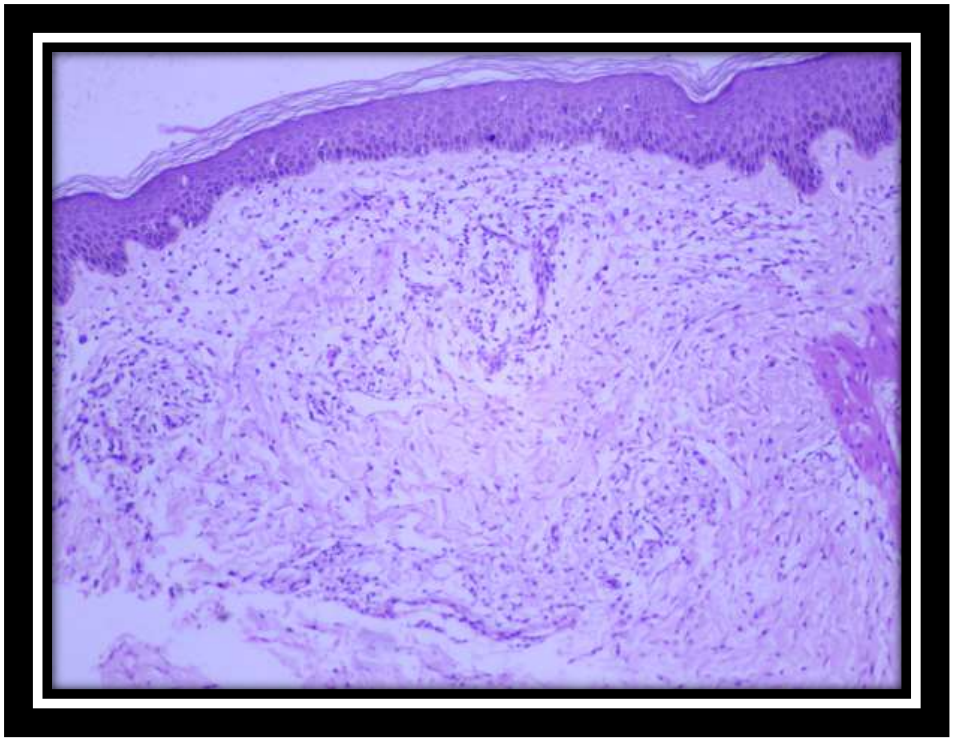

FIGURE 5: Borderline Lepromatous (BL) Hansen's disease (10x)

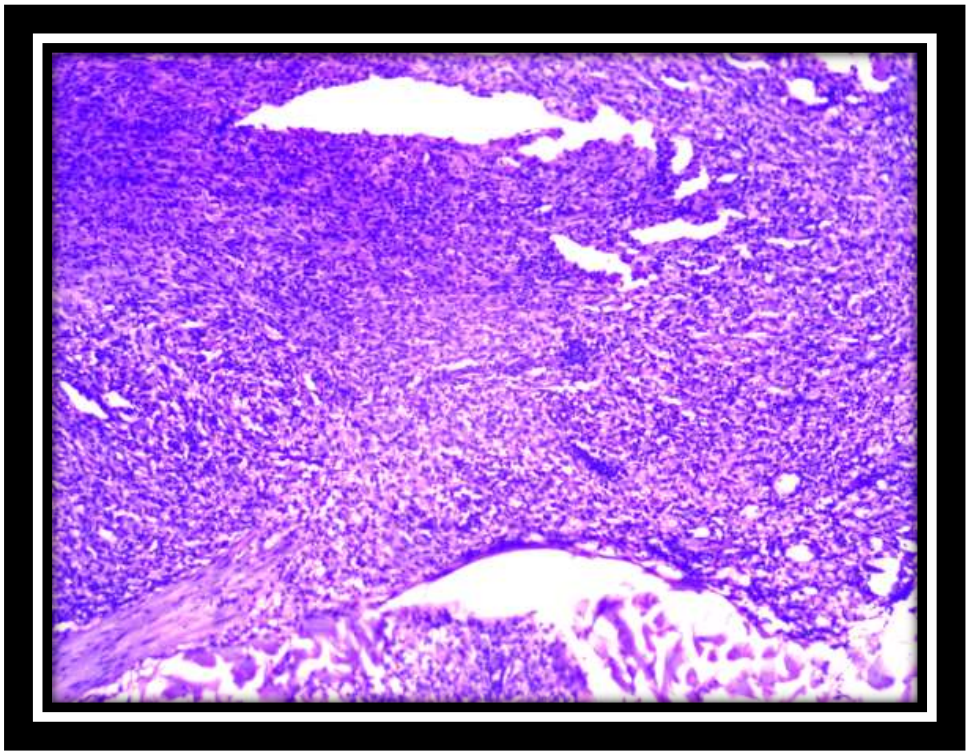

FIGURE 6: Histoid Leprosy showing spindled macrophages in the dermis (10x)

ISSN:0975 -3583,0976-2833 VOL14, ISSUE 11, 2023

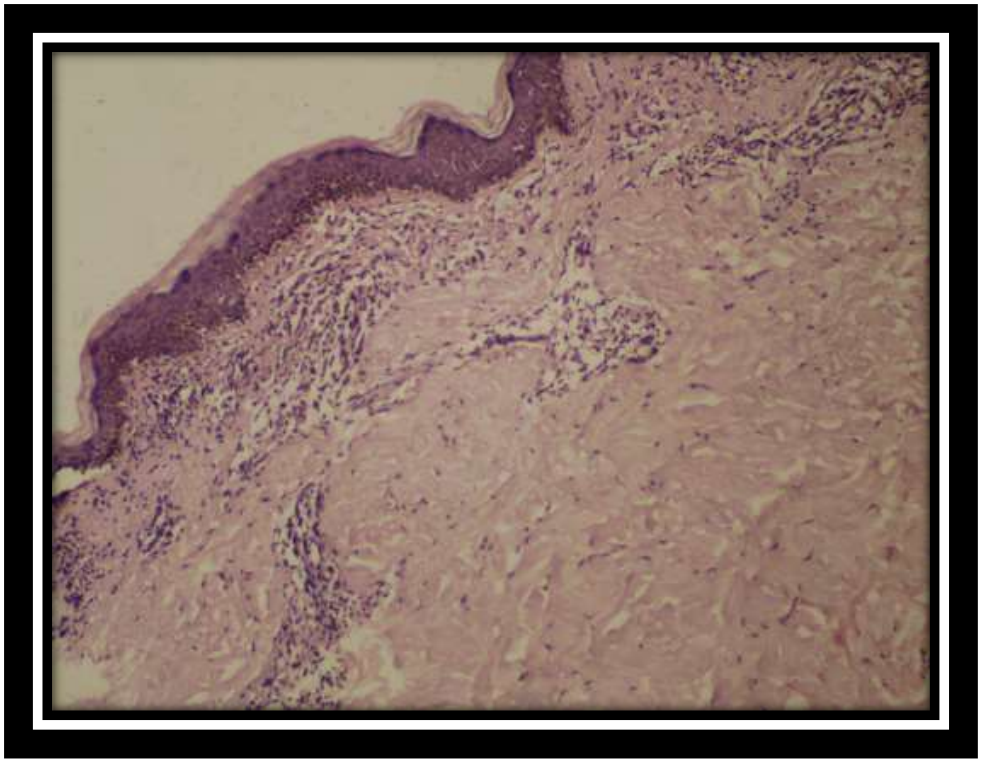

FIGURE 7: Indeterminate Hansen's Disease (40x)

DISCUSSION

In our study, 109 cases of clinically suspected leprosy skin lesions were studied histopathologically. Leprosy is known to occur at all ages ranging from early infancy to very old age. Maximum cases in our study were in age group 21 to 40 years i.e. 45.8% cases. Study conducted by Sehgal et al (8), Anusha et al (9), Suri et al (10) and Kaur et al (11) also found similar results with majority of the cases in 21-40 years age group. Male cases predominated in our study with a male to female ratio of 2.9:1 similar to other studies (12-15). In our study, borderline tuberculoid was the most common type of leprosy seen which included 43 cases (39.4%) similar to other studies as well (16-23). The second most common type was tuberculoid type with 16 cases (14.6%) similar to Roy et al (24) which also had tuberculoid type as the second most common type. Other types seen in our study were borderline borderline type 11cases (10.0%), lepromatous type 14 (12.8%) cases. Indeterminate and histoid type included 14 cases (12.8%) and 2 cases (1.8%) respectively.

CONCLUSION

The spectrum of leprosy presentation is very wide. Histopathological examination of skin lesions is a crucial method and the gold standard for accurate diagnosis and typing of leprosy. Leprosy is curable with multidrug therapy. Accurate diagnosis is required for proper treatment, preventing deformities and drug resistance. Biopsy is a minimally invasive and easy method as well. It supremely aids the clinician in better care and management of the leprosy patients.

ISSN:0975 -3583,0976-2833 VOL14, ISSUE 11, 2023

REFERENCES

1. Walker SL, Lockwood DN. The clinical and immunological features of leprosy. Br Med Bull 2006;78:103-21.
2. Pandya AN, Tailor HJ. Clinocohistopathological correlation of leprosy. Ind J Dermatol Venerol Leprol 2008;74:174-6
3. Ruchi Sinha et al., Histopathological Panorama of Leprosy Journal of Clinical and Diagnostic Research. 2019 Apr, Vol-13(4): EC12-EC15
4. Kumar A, Negi SR, Vaishnav K. A study of clinico-histopathological correlation of leprosy in a tertiary care hospital in western district of Rajasthan. J Res Med Den Sci. 2014;2(3):43-8.
5. Khamankar ST, Wagha S, Dawande P. Recent trend in leprosy: Histopathological study aspect in a tertiary care hospital. Indian Journal of Basic and Applied Medical Research. 2016;5(2):481-486.
6. Mohan N, Mishra N. Clinicohistopathological correlation within the spectrum of Hansen's disease: A multicentric study in North India. Int J Med Res Health Sci. 2013;2(4):887-892. 5. Punia RPS, Dhingra H, Baliyan A et al.
7. Clinicopathologic spectrum of Histoid leprosy. International Journal of Current Research. 2017;9(5):50765-50769.
8. Sehgal VN, Ghorpade A, Saha K. Urban leprosy an appraisal from Northern India. Lepr Rev. 1984;55:159-66.
9. Anusha R, Jayaraman J. A study on Clinicohistopathological correlation in Hansen's disease. Int J Clin and Biomed Res. 2016;2(1):10-12.
10. Suri SK, Iyer RR, Patel DU, Bandil S, Baxi S. Histopathology and Clinicohistopathological correlation in Hansen's disease. J Res Med Den Sci. 2014;2(1):37-44.
11. Kaur I, Indira D, Dogra S, Sharma VK, Das A, Kumar B. Relatively spared Zones in Leprosy: A Clinicopathological Study of 500 Patients. Int J Lep.s 2003;71(3):227-9.
12. Shivamurthy V, Gurubasavaraj H, Shashikala PS, Kumar P. Histomorphological study of leprosy. Afr J Med Health Sci. 2013;12:68-73.
13. Kumar A, Negi SR, Vaishnav K. A study of clinico-histopathological correlation of leprosy in a tertiary care hospital in western district of Rajasthan. J Res Med Den Sci. 2014;2(3):43-8.
14. Khamankar ST, Wagha S, Dawande P. Recent trend in leprosy: Histopathological study aspect in a tertiary care hospital. Indian Journal of Basic and Applied Medical Research. 2016;5(2):481-486.
15. Mohan N, Mishra N. Clinicohistopathological correlation within the spectrum of Hansen's disease: A multicentric study in North India. Int J Med Res Health Sci. 2013;2(4):887-892.
16. Ravindranath S. A histopathological study and clinico histopathological correlation of single lesions in leprosy. Int J Med Res Rev. 2016;4(2):151-156.
17. Rizvi AA, Sharma YK, Dash K et al. An epidemiological and clinicohistopathological study of leprosy in semiurban area under PimpriChinchwad Municipal Corporation in Pune district of Maharashtra. Med J DY Patil Univ. 2015; 8(5):609-13.
18. ManandharU, Adhikari RC, Sayami G. Clinico-histopathological correlation of skin biopsies in leprosy. Journal of Pathology of Nepal. 2013;3:452-458.

19. Moorthy BN, Kumar P, Chatura KR, Chandrasekhar HR, Basavaraja PK. Histopathological correlation of skin biopsies in leprosy. Indian J Dermatol VenereolLeprol. 2001;67(6):299-301.
20. Giridhar M, Arora G, Lajpal K, Chahal KS. Clinicohistopathological concordance in leprosy - A Clinical, Histopathological and Bacteriological study of 100 cases. Indian J Lepr. 2012;84:217-225
21. ManandharU, Adhikari RC, Sayami G. Clinico-histopathological correlation of skin biopsies in leprosy. Journal of Pathology of Nepal. 2013;3:452-458
22. Hazarika D, Pawar MK, Dowerah E. A prospective study of clinic-histopathological correlation among leprosy patients attending a tertiary referral centre in Assam, in this post elimination era. Int J Health Sci Res. 2017;7(4):148-153.
23. Kini RG, Choudhury H. Clinicopathological correlation in diagnosis of Hansen's disease: A histopathologist's perspective. J Interdiscpl Histopathol. 2017;5(2):48-54.
24. Prerona Roy et.al. Histopathological Study of Leprosy Patients in a Tertiary Care Hospital in Navi Mumbai International Journal of Health Sciences & Research (www.ijhsr.org) 7 Vol.9; Issue: 2; February 2019