

**Original research article**

# Management of Gartland's type III supracondylar fracture humerus by k-wire fixation

<sup>1</sup>Dr. K. Sudhakar, <sup>2</sup>Dr. P. Kiran Kumar, <sup>3</sup>Dr. BRS Raviteja

<sup>1</sup>Assistant Professor Department of Orthopaedics, Government General Hospital, Vijayawada, Andhra Pradesh, India

<sup>2</sup>Associate Professor, Department of Orthopaedics, Orthopaedics, Siddartha Medical College, Vijayawada, Andhra Pradesh, India

<sup>3</sup>Assistant Professor Department of Orthopaedics, Siddartha Medical College, Vijayawada, Andhra Pradesh, India

**Corresponding Author:  
Dr. BRS Raviteja**

## Abstract

Paediatric supracondylar humerus fractures account for 60% of elbow joint fractures in children. This fracture is most common in the first five years of life and peaks at 5-8. Displaced supracondylar fracture humerus causes frequent management problems for the clinician. This fracture can cause Volkmann's ischemic contracture<sup>4</sup>, myositis ossificans, neurovascular damage, stiff elbow, and malunion if not properly handled. Closed reduction and casting, skin or skeletal traction, closed reduction and percutaneous k wire fixation, open reduction and internal fixation have all been considered for treating displaced supracondylar fracture humerus in children. Traditional treatment for displaced supracondylar fracture humerus is closed manipulation, reduction, and cast immobilization. Malunion may cause elbow joint stiffness and varus or valgus deformity due to loss of reduction and manipulation capability. Open reduction with internal fixation is used for complicated fractures, fractures requiring vascular exploration, and fractures with poor reduction. The most common treatment for displaced supracondylar fracture humerus is closed reduction and percutaneous pinning, according to research. Our observations show that closed reduction with percutaneous pinning and k-wire fixation is safe and effective for displaced supracondylar humerus fractures. Kids aged 5-10 were most involved. Most injuries result from falls while playing. Closed reduction with percutaneous pin fixation improves function and appearance in children with displaced supracondylar humerus fractures. It reduces hospital stays and treatment expenses. It decreases patient morbidity and dependence. Cubitus varus, the most common supracondylar humerus fracture consequence, is rare with this treatment. Pin-securing a swollen elbow beyond 90 degrees can avoid vascular impairment.

**Keywords:** Gartland's type III, supracondylar fracture, humerus, k-wire fixation

## Introduction

Supracondylar humerus fracture, one of the common injury in paediatric age group and accounts for 60% of the fractures around elbow joint in children<sup>[1]</sup>. This fracture is seen more during initial five years of life and touches the peak at 5-8 years of age<sup>[2]</sup>. Difficulties occur frequently in management and continue to trouble the doctor especially in case of displaced type of supracondylar fracture humerus<sup>[3]</sup>.

If this fracture is not managed in a proper manner it may result in developing complications like Volkmann's ischemic contracture<sup>[4]</sup>, myositis ossificans, neurovascular injury, stiff elbow and malunion. Many techniques have been suggested for the treatment of displaced type supracondylar fracture humerus in children such as closed reduction and casting, tractions like skin traction or skeletal traction, closed reduction and percutaneous k wire fixation, open reduction and internal fixation<sup>[5]</sup>.

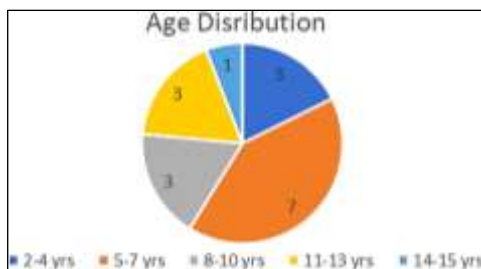
Closed manipulation, reduction and cast immobilization have been conventionally used for displaced type of supracondylar fracture humerus. But loss of reduction and need for redo of manipulation is likely to go for malunion which may lead to varus or valgus deformity of elbow joint and elbow joint stiffness<sup>[6]</sup>. Open reduction and internal fixation has been usually adopted for specific indications such as compound fracture, a fracture which need vascular exploration, or a fracture with inadequate reduction.<sup>5</sup> According to many studies closed reduction and percutaneous pinning is the most accepted treatment for displaced type of supracondylar fracture humerus.

## Aims & Objectives

The aim of this study is to evaluate the outcome of management of Gartland's type III supracondylar fracture humerus by K wire fixation.

**Observations & Results**

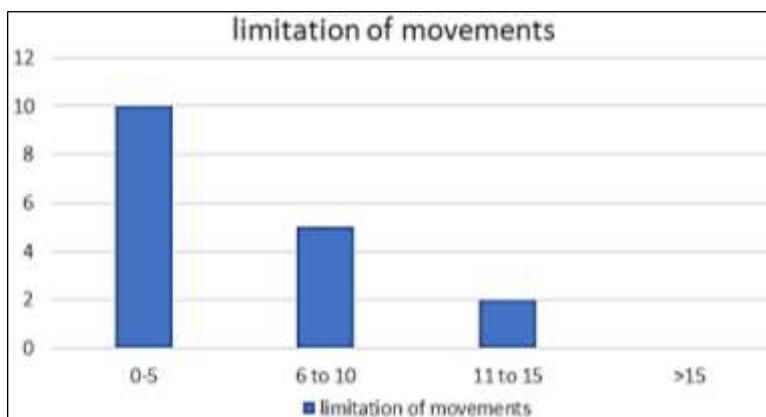
Seventeen patients with type III supracondylar fracture humerus were admitted in Government General Hospital, Siddhartha Medical College, Vijayawada between October 2019 and October 2021. All the cases were treated by closed manipulation reduction and percutaneous k-wire fixation. From the data gathered during this investigation, the following results were obtained. Closed reduction and percutaneous fixation with K wires were used to treat seventeen patients with closed displaced supracondylar fractures. At 4 weeks, 12 weeks, and 24 weeks after surgery, a follow up was performed. Out of the 17 patients, 10 (62.5%), were in the 5-10 year old age group, followed by 4 (25%) in the 11-15 year old age group.



**Fig 1:** Age distribution

Most number of cases were males i.e., 11 (65%) and 6 (35%) patients were females. The commonest cause of fracture in this study was a fall while playing, which occurred in eight patients (47 percent), followed by fall from steps or tree in six patients (35 percent), and a fall from a bicycle in three patients (17 percent). Right side involvement seen in 11patients (64%) and the left side involvement 6 (36%) patients.

During this study one case was diagnosed with superficial pin site infection and treated with proper antibiotics and one case was identified with cubitus varus. Iatrogenic ulnar nerve palsy or K-wire migration have not occurred in our study. 10 patients (58%) had a decrease in range of movement of less than 5 degrees, and no patients had a loss of range of motion higher than 15 degrees.



**Fig 2:** Limitation of movements

10 patients (58.82 percent) had a 0 to 5 degree loss of carrying angle in the involved extremity. Six patients (35.29 percent) had a loss of carrying angle of 6-10 degrees. Only one patient (5.88%) had a loss of carrying angle of 11-15 degrees, while the average carrying angle loss in our sample was 4.15 degrees. In our research, evidence of a significant loss of carrying angle, i.e. greater than 15 degrees was not observed.

**Table 1:** Flynn’s grading system

Flynn’s grading system			
Result	Rating	Cosmetic factor : Loss of carrying angle (degrees)	Functional factor : loss of motion (degrees)
Satisfactory	Excellent	0-5	0-5
	Good	6-10	6-10
	Fair	11-15	11-15
Unsatisfactory	Poor	>15	>15

Flynn's criteria have been used to evaluate the final results. In this study, 17 individuals (100%) had satisfactory outcomes. Of the 17 patients, 10 (58%) were assessed as excellent, 6 (35%) were classified

as good, and 1 (5%) was found to have fair results.

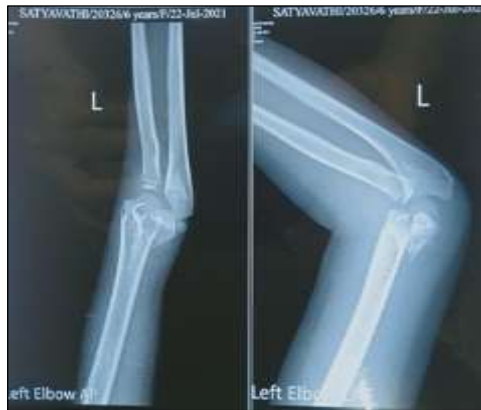

Fig 3: Left elbow images

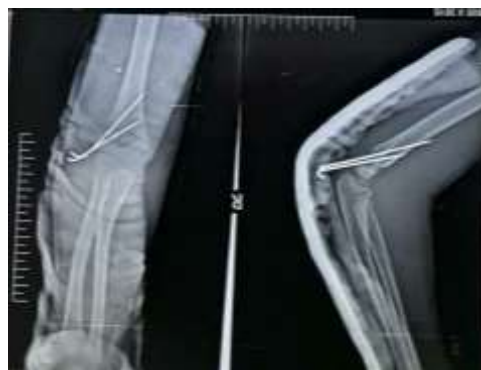
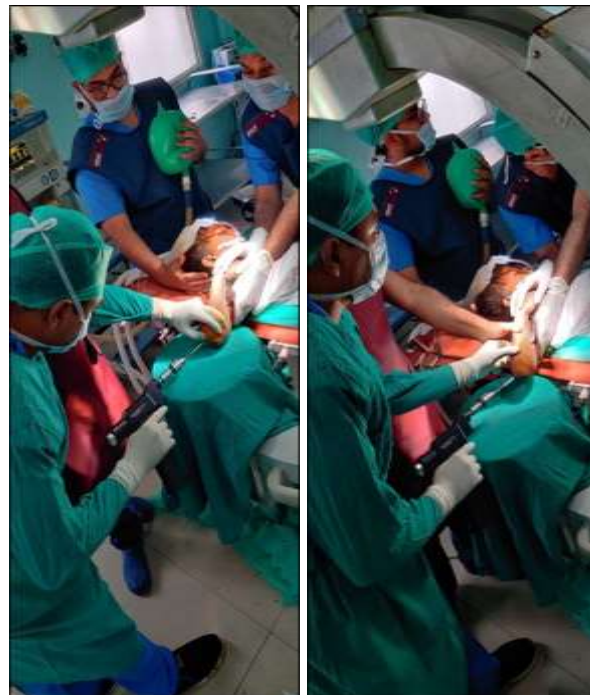
Fig 4: Elbow images

### Discussion

The aims of the treatment of supracondylar fractures are to achieve functionally and cosmetically satisfactory results and to avoid complications. Assuring a low cost and decreasing the hospitalization period are very important for both surgeons and patient's parents.



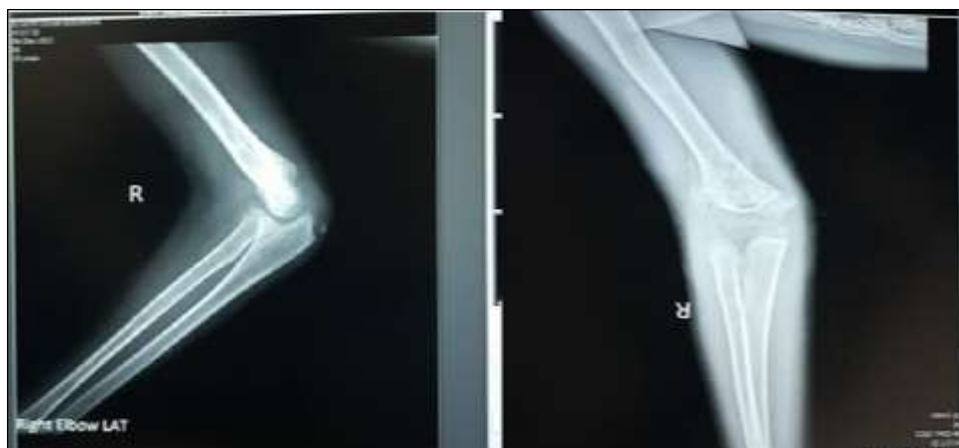

Fig 5

Traction is still an effective method of treatment but has many drawbacks. First, it is expensive. Second, when the extremity is swollen, it is very risky to attempt skin traction. Third, when skeletal traction is attempted, it poses some problems and prolongs the hospitalization period. Open reduction and internal fixation is another choice of treatment. There are number of approaches to the fracture. Most commonly used approach is posterior approach. However there are studies suggesting that this posterior approach is associated with complications like loss of movements and high chance to develop infections. Because of these complications, the choice of open reduction has been reserved for specific conditions such as open fracture, failed to achieve enough reduction in closed methods or neurovascular damage that worsens during closed manipulative methods<sup>[1-3]</sup>. Hence percutaneous pinning has become a popular method recently. The present study was conducted to assess the results of closed reduction followed by percutaneous fixation with Kirschner wires for 64 displaced extension type of supracondylar fractures of the humerus in children.

In the present study 58% of the patients were from 5-10 years age group with the average age being 7.5 years. Wilkins K.E. *et al.* in their study found the average age group was 6.7 years. Fowles JV *et al.* in a study, stated that most of the patients belong to 5-10 years of age group.

In our study, Males made up 65 percent of the patients in this study, while females made up 35 percent. Wilkins KE *et al.* found that 62.8 percent of the men and 37.2 percent of the women in his study. Fowles J V *et al.* stated that in their study of one hundred and ten patients 68% were boys and remaining 32% were girls. In our study, the fracture occurred on the right side in 10 patients (58.82%) and on the left side in 7 patients (41.17%) in this study. Wilkins KE. *et al.* reported 60.8 percent on the left side and 39.2 percent on the right side in their series<sup>[3-5]</sup>.

In our study, the main cause fracture in this study was fall while playing which was noted in 8(47%) patients, followed by fall from tree or steps which was noted in 6(35%) patients and in 3(17%) the cause of fracture is due fall from bicycle. Farnsworth *et al.* in their study mentioned that major cause of fracture was fall while playing which accounted for 70%. In this study 11(61%) patients had posteromedial type of fracture pattern and 7(39%) patients showed posterolateral type of fracture pattern. Wilkins KE *et al.* reported that posteromedial type fracture displacement is more common than lateral displacement, occurring in approximately 75% of patients in most series<sup>[6-8]</sup>.

In our study, one incidence of superficial pin tract infection was diagnosed and treated with antibiotics and one case was identified with cubitus varus. Iatrogenic ulnar nerve palsy or K-wire migration have not occurred in our study. Pirone *et al.* reviewed 230 patients treated by different methods. The highest percentage of excellent results were achieved by percutaneous Kirschner wire fixation (78%), skeletal traction (67%) and open reduction with internal fixation (67%). No ulnar nerve injuries were attributed to the medial pin and two pin track infection occurred in percutaneous pin fixation group. Flynn *et al.* reported 52 patients treated by closed reduction and percutaneous-pin fixation. 51 (98%) patients had satisfactory results by their own criteria. They reported that one patient had transient ulnar neuropathy due to medial pin insertion. Two patients had loss of reduction. There were no pin tract infections, broken pins or growth disturbances<sup>[9]</sup>.

At the last follow-up, 10 patients (58%) had a 0-5° loss of range of motion in the injured limb, with no patients having a loss of range of motion more than 15 degrees. In this study, the average loss of range of motion was 4.49°. Nacht JL *et al.* identified that average loss of range of motion was 7.8° in their study. Aronson DD. *et al.* reported the average loss of motion was 5.65°. At the end of the study, 10 patients (58.82 percent) had a 0-5 degree carrying angle loss of the affected extremity. Six patients (35.29 percent) had a carrying angle reduction of 6-10 degrees. Only one patient (5.88%) had a carrying angle loss of 11-15 degrees, while the average carrying angle loss in our sample was 4.15 degrees. In our study, there was no evidence of a significant loss of carrying angle, i.e. greater than 15 degrees. Nacht

JL. *et al.*, noted mean carrying angle loss of 5.8 degree (range 2°-15°) in 20 patients and increased carrying angle in 4 patients by an average of 6.8° at the final follow up examination <sup>[10]</sup>. All of the fractures in our study united around 4 weeks. One incidence of superficial pin tract infection was diagnosed and treated with antibiotics. Wilkins K E *et al.* Noted that mean time taken for the fracture union was 5.6 weeks <sup>[11, 12]</sup>.

### Conclusion

Closed reduction with percutaneous pinning with k-wire fixation is a safe and effective approach for fixing displaced supracondylar humerus fractures, according to our observations. Most involved age 5-10 years of age. The most prevalent mode of injury is a fall while playing.

For displaced supracondylar humerus fractures in children, closed reduction with percutaneous pin fixation provides excellent functional and cosmetic benefits. It minimizes the time of stay in the hospital, lowering treatment costs. It reduces the patient's morbidity and reliance. Cubitus varus, the most common complication in supracondylar humerus fracture, is uncommon with this treatment. An elbow with marked swelling can be extended beyond 90 degrees with the fracture secured by pins, which can avoid vascular compromise.

**Funding:** None.

**Conflict of Interest:** None.

### References

- Moraleda L, Valencia M, Barco R, González-Moran G. Natural history of unreduced Gartland type-II supracondylar fractures of the humerus in children: a two to thirteen-year follow-up study. *JBJS*. 2013 Jan;95(1):28-34.
- Skaggs DL, Sankar WN, Albrektson J, Vaishnav S, Choi PD, Kay RM. How safe is the operative treatment of Gartland type 2 supracondylar humerus fractures in children? *Journal of Pediatric Orthopaedics*. 2008 Mar;28(2):139-41.
- O'hara LJ. Displaced supracondylar fractures of the humerus in children: audit changes practice. *The Journal of Bone & Joint Surgery British Volume*. 2000 Mar;82(2):204-10.
- Padman M, Warwick AM, Fernandes JA, Flowers MJ, Davies AG, Bell MJ. Closed reduction and stabilization of supracondylar fractures of the humerus in children: the crucial factor of surgical experience. *Journal of Pediatric Orthopaedics B*. 2010 Jul;19(4):298-303.
- Kronner Jr JM, Legakis JE, Kovacevic N, Thomas RL, Reynolds RA, Jones ET. An evaluation of supracondylar humerus fractures: is there a correlation between postponing treatment and the need for open surgical intervention? *Journal of children's orthopaedics*. 2013 Mar;7(2):131-7.
- Khulbe P, Singh DM, Aman A, Ahire ED, Keservani RK. The emergence of nanocarriers in the management of diseases and disorders. *Community Acquired Infection*, 2023 Apr, 10.
- Pavone V, Vescio A, Accadbled F, Andreacchio A, Wirth T, Testa G, *et al.* Current trends in the treatment of supracondylar fractures of the humerus in children: Results of a survey of the members of European Paediatric Orthopaedic Society. *Journal of Children's Orthopaedics*. 2022 Jun;16(3):208-19.
- Young S, Fevang JM, Gullaksen G, Nilsen PT, Engesaeter LB. Deformity and functional outcome after treatment for supracondylar humerus fractures in children: a 5-to 10-year follow-up of 139 supracondylar humerus fractures treated by plaster cast, skeletal traction or crossed wire fixation. *Journal of children's orthopaedics*. 2010 Oct;4(5):445-53.
- Camus T, MacLellan B, Cook PC, Leahey JL, Hyndman JC, El-Hawary R. Extension type II pediatric supracondylar humerus fractures: a radiographic outcomes study of closed reduction and cast immobilization. *Journal of Pediatric Orthopaedics*. 2011 Jun;31(4):366-71.
- Ariyawatkul T, Eamsobhana P, Kaewpornasawan K. The necessity of fixation in Gartland type 2 supracondylar fracture of the distal humerus in children (modified Gartland type 2A and 2B). *Journal of Pediatric Orthopaedics B*. 2016 Mar;25(2):159-64.
- Loizou CL, Simillis C, Hutchinson JR. A systematic review of early versus delayed treatment for type III supracondylar humeral fractures in children. *Injury*. 2009 Mar;40(3):245-8.
- Sinikumpu JJ, Pokka T, Sirviö M, Serlo W. Gartland type II supracondylar humerus fractures, their operative treatment and lateral pinning are increasing: a population-based epidemiologic study of extension-type supracondylar humerus fractures in children. *European Journal of Pediatric Surgery*. 2017 Oct;27(05):455-61.