

Original Research Article

A Comparative Study between Ropivacaine and Ropivacaine with Dexmedetomidine in Ultrasound Guided Supraclavicular Brachial Plexus Blockade in a Tertiary Care Center

Dr. Liz Maria Joy¹, Dr. Harikumar A.²

¹Senior Resident, Department of Anaesthesiology, Government T.D. Medical College, Alappuzha, Kerala, India.

²Associate Professor, Department of Anaesthesiology, Government T.D. Medical College, Alappuzha, Kerala, India.

Corresponding Author

Dr. Harikumar A., Associate Professor, Department of Anaesthesiology, Government T.D. Medical College, Alappuzha, Kerala, India.

Received: 14-12-2023 / Revised: 19-12-2023 / Accepted: 17-01-2024

ABSTRACT

Background and objectives

Ropivacaine has reduced risk of cardiotoxicity, neurotoxicity with rapid recovery of motor function. Variety of adjuvants have been used to prolong the duration of local anaesthetic action in regional blocks. Dexmedetomidine is a commonly used adjuvant which significantly prolongs the duration of peripheral nerve blocks. we have conducted an observational study on effect of Dexmedetomidine as an adjuvant to Ropivacaine in ultrasound guided supraclavicular brachial plexus blockade in adult upper limb surgeries observed on the basis of onset and duration of analgesia.

Methods

After ethical committee approval and informed consent from patients, a prospective observational study was performed on patients scheduled for adult upper limb surgeries. This study was done among two group of patients belonging to ASA 1 and 2. Both the groups of patients were comparable with regard to age, sex, height and weight. Patients who received inj. 0.375% Ropivacaine (25ml) with 1.0 ml isotonic sodium chloride.(n=40) were observed as group 1 and those who received inj.0.375% Ropivacaine (25ml) with 100mcg Dexmedetomidine (1.0 ml) (n=40) were observed as group 2. Computer software SPSS version-22 (IBM SPSS Statistics, Somers NY, USA) was used for statistical analysis. Independent t test and chi-square test were used and $p < 0.05$ was considered as significant.

Results

Mean Time of onset of sensory blockade (mins) in Group 1 was 14.11 ± 1.42 mins, in Group 2 was 10.58 ± 1.56 mins. Mean Duration of Analgesia (min) in Group 1 was 724.78 ± 62.43 mins, in Group 2 was 984.56 ± 84.15 mins. . Incidence of bradycardia ($p = 0.006 < 0.05$) were more in patients who received dexmedetomidine.

Conclusion

Dexmedetomidine as an adjuvant to Ropivacaine in supraclavicular brachial plexus blockade prolongs the onset and duration of analgesia.

Key words: Ropivacaine, dexmedetomidine, supraclavicular brachial plexus block.

INTRODUCTION

Peripheral nerve blocks have become important in clinical practice because of their role in post-operative pain relief, shortening of patient recovery time and avoiding risks and adverse effects of General anaesthesia. Supraclavicular Brachial plexus block is popular and widely employed peripheral nerve block technique for perioperative anaesthesia and analgesia for upper limb surgeries. Regional nerve blocks are based on the concept that pain is conveyed by nerve fibers, which can be interrupted anywhere along their pathway. This approach is attractive due to its effectiveness in terms of cost and performance, margin of safety along with good postoperative analgesia. Ultrasound is commonly used for supraclavicular block in our practice. It decreases the incidence of complications and we can also reduce the total volume of local anaesthetic given and hence the side effects.

Many investigators have tried mixing local anaesthetic with various adjuvants like epinephrine, clonidine, dexmedetomidine, buprenorphine, dexamethasone, sodium bicarbonate, tramadol and midazolam.¹

AIMS & OBJECTIVES

Primary objectives:

To compare the efficacy of Ropivacaine and Ropivacaine with Dexmedetomidine in supraclavicular brachial plexus blockade for adult upper limb surgeries at Govt. T.D. M,C,H, Alappuzha in terms of ;

1. Onset of sensory block
2. Duration of analgesia

Secondary objectives:

To study hemodynamic stability during surgery after giving supraclavicular brachial plexus block and any adverse effects.

PAIN

Definition² The international association for the study of pain (IASP) defines pain as "an unpleasant sensory and emotional experience associated with actual or potential tissue damage, or described in terms of such damage". Thus pain is not only just a physical sensation but also an emotional experience. It varies from person to person and in the same person from time to time.

ROPIVACAINE It was introduced in clinical use in 1996. It is a long acting amide local anaesthetic. It was reduced for the purpose of reducing potential cardiovascular and CNS toxicity of Bupivacaine. Ropivacaine has the advantage of providing differential blockade with reduced systemic toxicity Ropivacaine belongs to pipercoloxylidides and has a propyl group on the piperidine nitrogen atom. Chemical structure is $-S(-)-1-Propyl-2',6'-pipercoloxylidide$ hydrochloride monohydrate.

DEXMEDETOMIDINE, an imidazole compound, is the pharmacologically active dextroisomer of medetomidine that display specific and selective α_2 adrenoceptor agonism³. Dexmedetomidine enhances the onset of sensory blockade along with increased duration of

analgesia during peripheral nerve blockade.^{4,5,6,7} Systemic administration of dexmedetomidine has been a focus of interest for their sedative, analgesic, perioperative sympatholytic and cardiovascular stabilizing effect with reduced anaesthetic requirement.⁸ In this study, we investigated the effects of adding Dexmedetomidine to Ropivacaine in ultrasound guided supraclavicular brachial plexus blockade.

MATERIALS AND METHODS

After obtaining from the institutional ethics committee and informed consent from the patients with ASA grade 1 and grade 2 from the age 18 to 55 of either sex satisfying selection criteria, undergoing elective upper limb extremity below mid humerus level.

Patients were randomly allocated into two groups as follows

- Those received inj. 0.375% Ropivacaine (25ml) with 1.0 ml isotonic sodium chloride were observed as Group 1
- Those received inj.0.375% Ropivacaine (25ml) with 100mcg Dexmedetomidine (1.0 ml) were observed as Group 2

EXCLUSION CRITERIA were pregnancy, pre-existing neuropathy involving the surgical limb, Systemic use of corticosteroids for ≥ 2 weeks within 6 months of surgery, Sinus bradycardia, allergy to local anaesthetics, Psychologically ill or mentally retarded patients, Significant uncontrolled diseases, Coagulopathies were excluded.

A sample size of 90 patients who fulfilled the inclusion and exclusion criteria were studied into two groups of 45 each, using computer generated randomization, and observed as group 1 and group 2.

Analgesia was assessed by Visual Analogue Scale which is marked from 0 to 100. In this scale 0 corresponds to no pain and 100 correspond to worst pain possible.

Onset of analgesia

Sensory block was assessed by pin prick with blunt 24G hypodermic needle every 3 minutes. The time of loss of pain to pin prick sensation over the desired dermatomes was taken as the onset of analgesia. Motor block will be assessed by failure to abduct the shoulder.

End point of analgesia

It is the time at which patient complains of pain of more than 50 in Visual Analogue Scale.

Duration of analgesia

Time period between the onset of analgesia to the end point of analgesia.

A routine preoperative assessment of all the anaesthetic procedure informed consent were taken. Vitals and detailed physical examination including airway assessment was done^{9,10} Preoperatively adequate fasting of 6hrs were confirmed. In operation theatre intravenous canula were placed. ECG, Non invasive blood pressure, pulseoximeter were applied. On operation table, under aseptic precaution patient were given the position for brachial plexus block via supraclavicular approach.

The patient was placed in supine position with the head turned away from the side to be blocked. The arms kept along the sides of the body. A high frequency 9-18 MHz linear array ultrasound transducer is used. After skin and transducer preparation, the probe was positioned in supraclavicular fossa just superior to the clavicle at midpoint. The probe was moved medially

and laterally and also in rocking fashion in order to locate pulsating subclavian artery. The areas lateral and superficial to subclavian artery were explored. The needle was inserted from lateral side of probe after local anaesthetic infiltration, first perpendicular to the skin to penetrate the skin and then at a shallow angle under the probe. The needle was advanced inside ultrasound beam by inplane technique till the plexus is seen with characteristic honey comb appearance. The subclavian vein is medial and superficial to the artery. Colour Doppler was also used to confirm the vascular nature of vessels. Under USG view, the pulsating subclavian artery was readily apparent, whereas the parietal pleura and first rib was seen as linear hyper echoic structure lateral and deep to it respectively. The brachial plexus was seen as a bundle of hypo echoic round nodules (grapes) just lateral and superficial to the artery. At this point, injection of 25 ml local anaesthetic which was prepared following gentle aspiration. Spreading of drug and bulging of plexus will be seen during injection. Local anaesthetic was injected so as to cause hydro dissection of the planes around plexus. All patients were monitored for side effects like nausea , vomiting, respiratory distress.

Sensory block was assessed by loss of sensation to pinprick over various dermatomes of upper limb. Motor block was assessed by failure to abduct the shoulder. Duration of analgesia, and adverse effects were noted.. The efficacy of post operative analgesia was assessed using a visual analogue scale (VAS); this score graded (0 no pain; 100 worst pain possible). The time period between the onset of analgesia to the end point of analgesia was documented as duration of analgesia. Adverse effects if any were noted

Statistical Analysis

Data were analysed using computer software, statistical package for social sciences(SPSS) version 22. Data are expressed in its frequency and percentage as well as mean, and SD. For all statistical evaluations, a two tailed probability of value < 0.05 was considered significant.

RESULTS

Table 1: Mean time of onset of sensory blockade, comparison between two groups (Group 1: Inj Ropivacaine + isotonic normal saline. Group 2: Inj Ropivacaine + dexmedetomidine)

	Groups						P Value
	Group 1		Group 2		N	SD	
	N	Mean	Mean	SD			
Time of onset of sensory blockade (mins)	45	14.11	1.42	45	10.58	1.56	< 0.001*

Mean Time of onset of sensory blockade (mins) in Group 1 was 14.11±1.42mins, in Group 2 was 10.58± 1.56mins. There was a significant difference in Time of onset of sensory blockade, onset of analgesia (mins) distribution between two groups which is statistically significant (p<0.001)

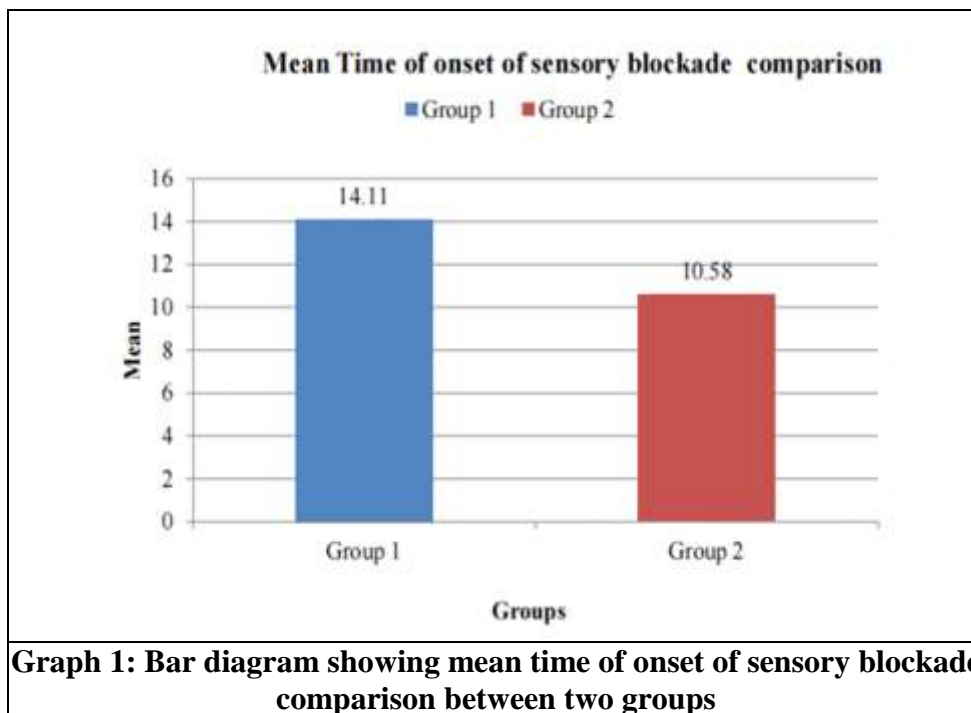
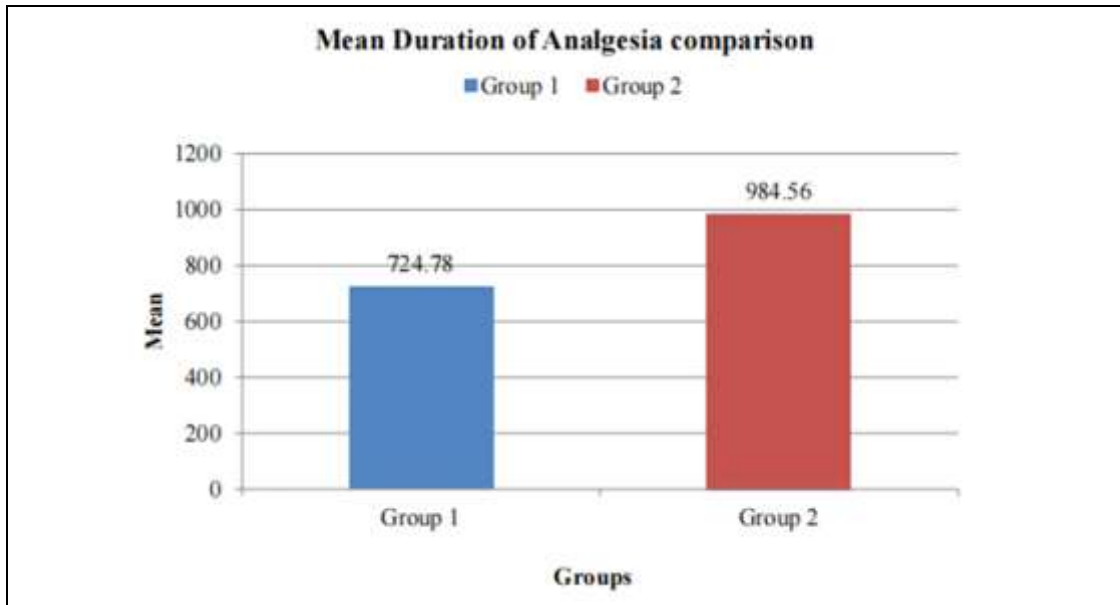


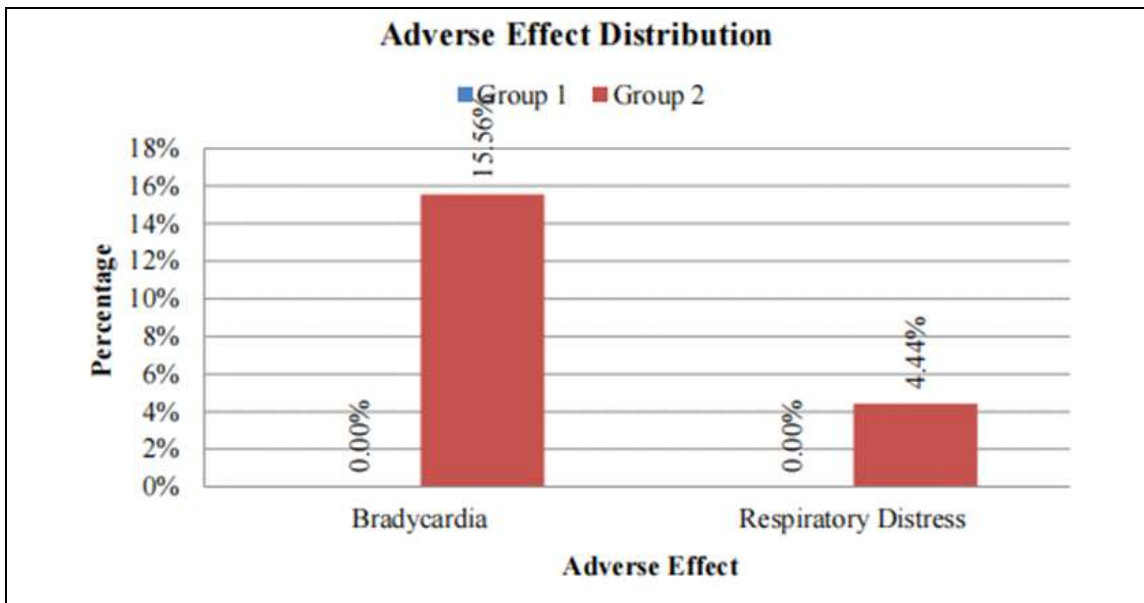
Table 2: Mean duration of analgesia comparison between two groups

	Groups						P Value
	Group 1			Group 2			
	N	Mean	SD	N	Mean	SD	
Time of onset of sensory blockade (mins)	45	724.78	62.43	45	984.56	84.15	< 0.001*

Mean duration of analgesia (min) in Group 1 was 724.78 ± 62.43 mins, in Group 2 was 984.56 ± 84.15 mins. There was a significant difference in duration of analgesia (mins) distribution between two groups which is statistically significant ($p < 0.001$)



Graph 2: Bar diagram showing mean duration of analgesia comparison between two groups



Graph 3: Bar diagram showing adverse effect distribution between two groups

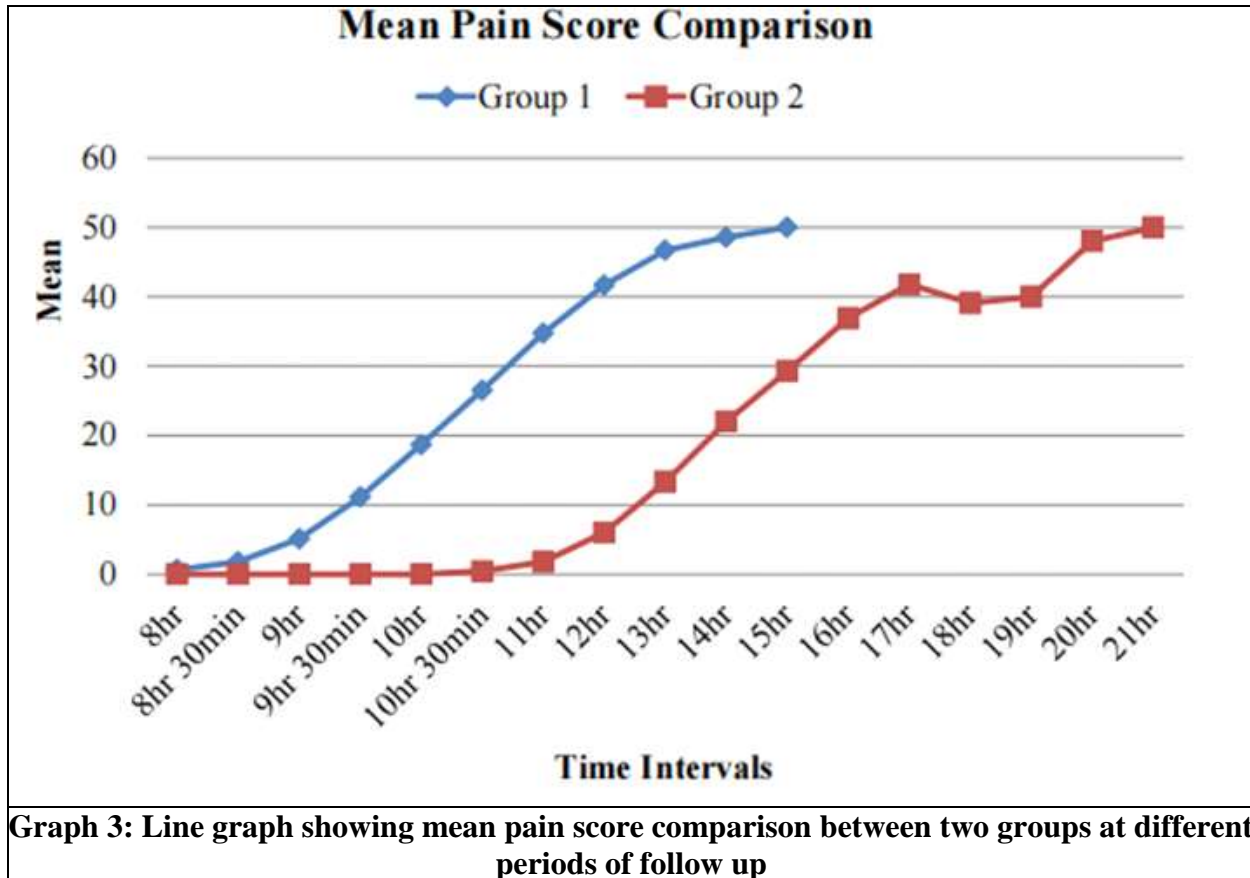
In Group 2, 15.56% had bradycardia and none in Group 1. There was a statistically significant difference in bradycardia distribution between two groups.

In Group 2, 4.44% had respiratory distress and none in Group 1. There was no significant difference in respiratory distress distribution between two groups.

Table 3: Mean pain score comparison between two groups at different periods of follow up

RR	Group						P Value
	N	Group 1 Mean	SD	N	Group 2 Mean	SD	
7hr	45	16.89	2.56	45	15.40	2.18	0.004*
7hr 30min	45	17.24	2.35	45	15.13	2.19	< 0.001*
8hr	45	17.20	2.59	45	15.36	2.13	< 0.001*
8 hr 30min	45	17.33	2.69	45	15.58	1.96	0.001*
9hr	45	17.16	2.63	45	15.18	1.93	< 0.001*
9hr 30min	45	17.13	2.59	45	15.73	1.92	0.005*
10hr	45	16.89	2.55	45	15.69	1.95	0.014*
10hr 30min	45	16.88	2.51	45	15.58	1.86	0.007*
11hr	45	16.83	2.52	45	15.87	1.85	0.048*
12hr	45	16.89	2.41	45	15.58	1.78	0.006*
13hr	45	16.92	2.24	45	15.58	1.85	0.010*
14hr	45	17.00	2.67	45	15.51	1.84	0.055
15hr	45	18.00	.	45	15.77	1.91	0.255
16hr	45	.	.	45	15.58	2.21	
17hr	45	.	.	45	15.74	2.23	
18hr	45	.	.	45	15.89	2.62	
19hr	45	.	.	45	15.60	1.95	
20hr	45	.	.	45	14.50	1.00	
21hr	45	.	.	45	13.00	.	

In the study there was a statistically significant difference in mean pain score from 8hr 30min. to 14hr. between two groups. At other intervals there was no significant difference in mean pain score between two groups.



DISCUSSION

In this study, a total of 90 patients who underwent upper limb surgeries were observed as two groups. Group A received 0.375% ropivacaine with isotonic saline and group B received 0.375% ropivacaine with 100 mcg dexmedetomidine. The mean onset of sensory block in Ropivacaine alone group was 14.11 ± 1.42 Min and was 10.58 ± 1.56 Min in Ropivacaine with dexmedetomidine group and have found that the mean onset of sensory block is faster if dexmedetomidine is added to the ropivacaine than ropivacaine alone ($p < 0.001$). This is in accordance with the study done by Jithendra Chinnappa *et al*¹¹ and Khemka V *et al*¹². But in the study done by Chandresh Kumar *et al*¹³, the onset of Ropivacaine with dexmedetomidine group is slower compared to our group B. (12.667 ± 1.213 min)

Mean duration of analgesia in ropivacaine group vs. dexmedetomidine group was 724.78 ± 62.43 mins and 984.56 ± 84.15 mins respectively ($p < 0.001$). This was almost similar to the study done by Anjan Das *et al*¹⁴ where they found out the mean duration of analgesia in dexmedetomidine group to be 846.67 ± 102.09 mins.

In this study there was significant difference in mean pain score from 8hr 30min to 14hr between two groups.

The most important finding of the current investigation was the faster onset and substantially longer duration of analgesia in patients receiving dexmedetomidine as an adjuvant when compared to the control group

But there was 15.56% incidence bradycardia which responded to single dose of atropine (0.6 mg) and 4.44% respiratory depression which did not require any treatment.

CONCLUSION

Dexmedetomidine is a good adjuvant in peripheral nerve blocks. It is a better alternative for faster onset of motor block along with enhanced quality and duration of supraclavicular block. There was increased incidence of bradycardia, respiratory depression as well as sedation in those who received dexmedetomidine. Hence post operatively these patients has to be monitored more vigilantly preferably in the high dependency area.

ACKNOWLEDGEMENT

We express our sincere gratitude to our beloved HOD Dr Linnette Morris, Dr. Muhammed Asharaf (HOD Orthopaedics), Research committee, recovery room nurses, operation room nurses technicians and all patients who have willingly co-operated for this official works.

REFERENCES

1. Chad M.Brummet, M.D. and Brian A. Williams, M.D., MBA Additives to Local Anaesthetics for Peripheral Nerve Blockade .Int Anaesthesiology Clinic 2011 Fall; 49 (4): 104-116
2. Merskey. H, Bogduk.M: Descriptions of chronic pain syndromes and definitions of pain terms. Seattle, WA, IASP 1994; Miller Anaesthesia 6th Edition 73:2763.
3. Dexmedetomidine : a novel sedative- analgesic agent. Proc (Bayl Univ Med Cent) 2001 Jan : 14 (1): 13-21
4. Marhofer D, Kettner SC, Marhofer P, Pils S, Weber M, Zeitlinger M. Dexmedetomidine as an adjuvant to ropivacaine prolongs peripheral nerve block : a volunteer study. Br j Anaesth. 2013 mar;110(3): 438-42
5. Malenfant Rancourt MP, Albert NT,Cote M, Letourneau DR, Bernard PM. Posterior tibial nerve sensory blockade duration prolonged by adding dexmedetomidine to ropivacaine. Anaesth anal 2012;115:958-62
6. Brummet CM, Norat MA,Palmisano JM, Lydic r. Perineural administration of Dexmedetomidine in combination with bupivacaine enhances sensory and motor blockade in sciatic nerve blockade without inducing neurotoxicity in rats. Anaesthesiology 2008; 109:502-11.
7. Zhang Y, Wang CS, Shi JH, Sun B, Liu SJ, Li P, Li EY. Perineural administration of dexmedetomidine in combination with ropivacaine prolongs axillary brachial plexus block. Int J Clin Exp Med. 2014 Mar 15;7(3):680-5.
8. Stahl S, Kaufman T. Ulnar nerve injury at the elbow after steroid injection for medial epicondylitis. J Hand Surg Br 1997;22:69-70
9. Abdullah S, Bowden RE. The blood supply of the brachial plexus. *Proc R Soc Med.* 1960 Mar. 53:203-5.
10. Uysal II, Seker M, Karabulut AK, et al. Brachial plexus variations in human fetuses. *Neurosurgery.* 2003 Sep. 53(3):676-84; discussion 684.
11. Efficacy of dexmedetomidine with ropivacaine in supraclavicular brachial plexus block for upper limb surgeries Jithendra Chinnappa1 , Shivakumar Shivanna2 , Journal of anaesthesiology Clinical pharmacology Year : 2017 | Volume : 33 | Issue : 1 | Page : 81-8
12. Khemka V, Jadeja PD. Comparative Study of Ropivacaine with Dexmedetomidine versus Ropivacaine Alone in Supraclavicular Brachial Plexus Block for Upper Limb Surgery. Int J Sci Stud. 2017;5(6):74-8
13. Sudani C, Rao SM, Munta K. A comparative study of ropivacaine alone versus

- ropivacaine with dexmedetomidine in supraclavicular brachial plexus block. *Anesthesiol Open J.* 2016; 1(1): 28-34. doi: 10.17140/AOJ-1-107
14. Effect of dexmedetomidine as adjuvant in ropivacaine-induced supraclavicular brachial plexus block: A prospective, double-blinded and randomized controlled study Anjan Das¹, Saikat Majumdar², Susanta Halder³, *Saudi journal of anaesthesia* doi: Year: 2014 | Volume : 8 | Issue : 5 | Page : 72-77