

COMPARATIVE STUDY OF THE EFFECT OF PTERYGOPALATINE FOSSA BLOCK DURING ENDOSCOPIC NASAL SURGERY ON INTRA OPERATIVE BLEEDING

Rukma Bhandary¹, Mahesh Santhraya G², Deepalakshmi Tanthry³, Shivaprasad Karanth⁴, Rinshin T⁵

¹Associate Professor, Department of ENT, A J Institute of Medicalscience and Research Centre, Mangalore, India.

²Professor and HOD, Department of ENT, A J Institute of Medicalscience and Research Centre, Mangalore, India.

³Associate Professor, Department of ENT, A J Institute of Medicalscience and Research Centre, Mangalore, India.

⁴Postgraduate, Department of ENT, A J Institute of Medicalscience and Research Centre, Mangalore, India.

⁵Postgraduate, Department of ENT, A J Institute of Medicalscience and Research Centre, Mangalore, India.

Received Date: 10/12/2023

Acceptance Date: 01/02/2024

Corresponding Author: Dr Shivaprasad Karanth, Postgraduate, Department of ENT, A J Institute of Medical Science and Research Centre, Mangalore, India.

Email: shivapkaranth@gmail.com

Abstract

Background: Bleeding is a common intraoperative complication in most of the surgeries and remains a challenge for the Surgeons. Despite the availability of many techniques, there is no definite method for controlling bleeding during endoscopic nasal surgeries. **Objective:** In this study, we evaluated the effectiveness of pterygopalatine fossa infiltration with lignocaine and adrenaline in controlling surgical field bleeding during endoscopic nasal surgery. **Methods:** Comparative observational study conducted in Department of ENT (Ear- Nose-Throat) of a tertiary care hospital. All patients who were diagnosed with chronic sinusitis, bilateral sinonasal polyposis, bilateral inferior turbinate hypertrophy supported by nasal endoscopy and computed tomography were considered for the study after fulfilling the inclusion and exclusion criteria. The effect of Pterygopalatine fossa infiltration was tested by injecting 2 mL of xylocaine with 1:100000 adrenaline in pterygopalatine canal on one side (test side), and saline on the control side. The surgical field was assessed and graded every 15 minutes on both sides according to Boezaart and Vander Merwe scoring system. **Result:** In our study, among the 22 patients who were infiltrated, 19 patients (86%) showed surgical field improvement on the infiltrated side, 3 patients (14%) had similar fields on both side (infiltrated and non-infiltrated side) and none of the patients had lesser bleed on the saline infiltrated side. The grading scale of surgical field was done using a scale called Boezaart and van der Merwe scale and the result was significantly better on the infiltrated side. (p value <0.001). **Conclusion:** This study finds a significant difference in surgical field bleeding, favouring the injection side. Since it is a simple technique with minimal complications, it can be routinely incorporated in all endoscopic nasal surgery.

Keywords: Pterygopalatine fossa, Xylocaine, Adrenaline, Endoscopic nasal surgery

Introduction

Bleeding is a common intraoperative complication in most of the surgeries and remains a challenge for the Surgeons. It hampers the adequate visualization of the surgical field and thus increases the rate of complications. It is particularly relevant in otorhinolaryngology for surgical bleeding to be controlled since many of the techniques used to control bleeding in other parts of the body cannot be used to control bleeding during surgery of the nasal cavities and paranasal sinuses. Therefore, control of intra operative bleeding is of prime importance as even a minute bleed can obscure the surgical field necessitating frequent suctioning and prolonging the operation time. However, intraoperative bleeding is a significant downside of endoscopic viewing. This increases the risk of consequences such as brain injury, orbital or optic nerve injury, and catastrophic bleeding from major vessels (e.g., internal carotid artery).¹ Bleeding during endoscopic nasal surgeries can be minimized by various techniques which include Obtaining appropriate hemostasis, which plays an important role in delivering an optimal surgical field and decreasing associated complications.² Methods to reduce intra-nasal bleeding include elevating the head end during surgery, administering epinephrine to the nasal wall,¹ inducing bradycardia during surgery,² packing the nose with decongestants, and inducing low blood pressure with magnesium³ or α -agonist administration before surgery.^{4,5} Endoscopic nasal surgeries can cause significant bleeding in some patients despite the use of all these techniques. In this study, we evaluated the effectiveness of pterygopalatine fossa infiltration with lignocaine and adrenaline in controlling surgical field bleeding during endoscopic nasal surgery.

Methodology

Aim: To evaluate and compare the effectiveness of pterygopalatine fossa block in controlling intra operative bleeding during endoscopic nasal surgery.

Study Design: Comparative observational study.

Study Site: The study was conducted in Department of ENT (Ear- Nose-Throat) of a tertiary care hospital.

All patients who were diagnosed with chronic sinusitis, bilateral sinonasal polyposis, bilateral inferior turbinate hypertrophy supported by nasal endoscopy and computed tomography were considered for the study after fulfilling the following inclusion and exclusion criteria.

Inclusion Criteria: Age above 18 years.

Exclusion Criteria: Patients with hypertension, hypersensitive to lignocaine, bleeding disorders, patient who are on anticoagulant therapy for example antiplatelets were all excluded from the study.

Ethical considerations: The study was initiated after obtaining approval taken from the institutional ethics committee and department of ENT. A written informed consent was taken from all the patients.

Method: The subjects who present to the ENT outpatient clinic with nasal complaints will go through a detailed ENT examination including rigid nasal endoscopy and CT scan. Patients will be selected for the study if they fulfill the inclusion and exclusion criteria. A written consent will be obtained from every patient. The effect of Pterygopalatine fossa infiltration tested by injecting 2 mL of xylocaine with 1:100000 adrenaline in pterygopalatine canal through Greater Palatine Foramen (GPF) on one side (test side), and saline on the control side. The surgeon who will be performing the surgery will be aware of the injections being administered on either side. All the surgeries will be performed by multiple surgeons who have performed the pterygopalatine infiltration. The principal investigator who will score the

surgical field grading at various time intervals remains blinded to the infiltration used on either side. The surgical field will be assessed and graded every 15 minutes on both sides according to Boezaart and Vander Merwe scoring system (table 1). Boezaart *et al.*⁶ in 1995 first proposed endoscopic surgical field grading scale to evaluate the effect of Esmolol and sodium nitroprusside during ESS and found that esmolol induced hypotension produced a superior surgical field.

Table 1: Boezaart surgical field grading

Grade	Assessment
0	No Bleeding (cadaveric conditions)
1	Sligh Bleeding- No suctioning required
2	Sligh Bleeding- occasional suctioning required
3	Sligh Bleeding- Frequent suctioning required. Bleeding threatens surgical field a few second after suction is removed
4	Moderate Bleeding- frequent suctioning required and bleeding threatens surgical field directly after suction is removed
5	Severe Bleeding- constant suctioning required. Bleeding appears faster than can be removed by suction. Surgical field severely threatened and surgery usually not possible

Statistical analysis - Statistical tests applied are as follows-

- Student un paired t-test
- Chi-Square test
- Phi – test

Analysis done using Statistical Package for Social Sciences (SPSS) version 24.0 following data entry in MS EXCEL spreadsheet.

Sample size - Based on the study conducted by AN INTERNATINAL JOURNAL CLINICAL RHINOLOGY [May-August 2017;10(2):62-65] in order to expect a difference of 1.9 in mean blood loss (according to Boezaart and van der Merwe Scale for endoscopic grading of bleeding during FESS) between the groups. Assuming 95 % confidence interval and 80% power with pooled standard deviation of 3.5 sample size estimated for the study is 22 each.

$N = [Z_{1-\alpha} + Z_{1-\beta}]^2 * 2SD^2 / (\text{mean difference})^2$.

Result

Our study included 38 patients who underwent endoscopic nasal surgery. Among the study subjects, one side acted as the case in which the standard greater palatine approach was used to give infiltration and the opposite side acted as the control where normal saline infiltration was given. Using a standard Boezaart and van der Merwe scale, the surgical field was graded every 15 minutes by the investigator(observer). The observer was unaware of the side which was infiltrated. Among the study population, majority of the patients were of middle age group with oldest being 70 years, youngest being 18 years and the mean age being 32 years. 9 were males and 13 were females among the study population (figure 1).

In this study, out of 22 patients who were given pterygopalatine fossa infiltration, improvement in surgical field was seen in 19 patients (86%) in adrenaline +xylocaine infiltrated side, almost similar surgical fields were seen on both sides in 3 patients (14%) and none of the patients had better field on the saline infiltrated side. Using a standard Boezaart and van der Merwe scale, the grading of surgical field was done and the results were significantly better on the adrenaline + xylocaine infiltrated side (p value <0.001) (table 2).

SEX DISTRIBUTION

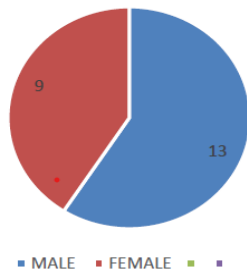


Figure 1: Sex distribution

Table 2: Comparison of bleeding between case and control group

Boezaart Grading	Number	Mean	Standard Deviation	P Value
Block side	22	8.41	2.971	P <0.001
Control side	22	11.77	2.910	

Surgical field bleeding grade done at 45 min, 60mins (table 3) and 90 minutes showed statistically significant improvement in favour of intervention whereas grading done at 15 min, 30 min, 75 min, 105 min and 120 minutes were not significant (figure 2).

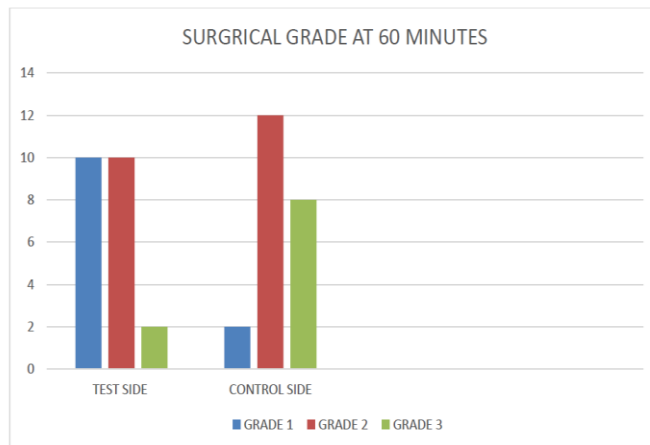


Figure 2: surgical grade at 60 minutes

Table 3: surgical grade at 60 minutes (p=0.01 -> hrs)

Surgical grade	Test side	Control side	Total
	10	2	12
Grade 1	45.5%	9.1%	27.3%
Grade 2	10	12	22
	45.5%	54.5%	50%
Grade 3	2	8	10
	9.1%	36.4%	22.7%
Total	22	22	44
	100%	100%	100%

Discussion

Endoscopic nasal surgery is most effective when the surgeon has good visibility of the operative field throughout the procedure. Deterioration in surgical field quality due to bleeding has been demonstrated to prolong the process and may increase the risk of operative complications.⁷ Understanding where the greater palatine fossa (GPF) is located is essential for improving posterior palate injection technique and attaining ideal hemostasis. According to Ajmani (8), Surgical field bleeding depends on many factors, including the severity of the disease and the patient's co-morbid conditions such as high blood pressure and blood clotting disorders. In India, 64% of the larger palatine fosse is situated on the opposite side of the 3rd molar. The surgeon's inability to adequately visualize the surgical environment also increases the risk of tissue injury with an increased risk of scarring, adhesion, and disease recurrence after surgery.⁹

Various well described and developed strategies to minimize intra-operative bleeding include – patient positioning, anesthetic techniques, topical decongestants, infiltration techniques and surgical techniques. Pterygopalatine fossa infiltration is one of the techniques. In the pterygopalatine fossa it is possible to reach both the nasopalatine nerve and the posterior nasal branches of the maxillary nerve.¹⁰ This means that both the lateral wall of the nasal cavity and the posterior part of the septum can be successfully anesthetized by local anesthetic infiltration of the pterygopalatine fossa through the greater palatine foramen.

The method of pterygopalatine fossa infiltration is used in different procedures including FESS, septorhinoplasty and dental regional anesthesia.^{11,12} This study aimed to see the effect of the pterygopalatine canal injection with local anesthetic (2% xylocaine) and 1:100000 adrenaline on bleeding during endoscopic nasal surgery. Injection in pterygopalatine canal was given based on previously mentioned technique. This study finds a significant difference in surgical field bleeding favouring the injection side. Surgical field bleeding showed significant difference at 45, 60 and 90 minutes duration. The overall surgical field bleeding showed improvement on intervention side with p value of <0.001. Similarly, Wormald *et al.*⁵ found injection of the pterygopalatine fossa resulted in an improved surgical field during endoscopic sinus surgery. Another study was done by Bhardwaj VK,¹³ Novonty GM regarding greater palatine canal injection as an alternative to posterior nasal packing and arterial ligation in epistaxis and showed results favouring the procedure. Contrary to our findings, Valdes *et al.*¹⁴ found no significant differences between injected and non-injected sides in terms of surgical field grade. Although many complications have been described in literature, we did not encounter any complication related to the infiltration technique in the study subjects. In the study by Wormald *et al.*,⁵ no complications were mentioned as such. In a study using local vasoconstrictors by Riegle *et al.*,¹⁵ patients had systemic side effects like increase in BP and HR, headache. It has also been reported that operative time affects the operative field,¹⁶ which may be due to vascular dilation with operative time and an increase in the area of damaged tissue in.¹⁷

Both anaesthetic techniques and surgical techniques have to be combined to get an optimum result during endoscopic sinus surgery. In our study, we have noted that the pterygopalatine fossa infiltration gives a better haemostatic control. We therefore recommend pterygopalatine injection as an additional maneuver along with a few of the other described techniques for an optimised surgical field during endoscopic nasal surgery.

Conclusion

Our study aimed to see the effect of the pterygopalatine fossa injection with 2ml xylocaine plus 1:100000 adrenaline on reducing bleeding during endoscopic nasal surgery and thus providing

a better surgical field. This study finds a noteworthy difference in surgical field bleeding, favouring the injection side. Surgical field bleeding showed significant difference at 45-, 60- and 90-minutes duration. The overall surgical field bleeding showed improvement on intervention side with p value of <0.001. The technique for attaining haemostasis in ESS is multifactorial; this may range from simple warm saline irrigations to use of gelatin matrix in achieving haemostasis. Infiltration of the pterygopalatine fossa is one of the many techniques that can be adopted to provide a better surgical field. Since it is a simple technique with minimal complications, it can be routinely incorporated in all endoscopic nasal surgery.

References

1. Thongrong C, Kasemsiri P, Carrau RL, Bergese SD. Control of bleeding in endoscopic skull base surgery: current concepts to improve hemostasis. *ISRN Surg*. 2013;13(2013):191543.
2. Moshaver A, Lin D, Pinto R, Witterick IJ. The hemostatic and hemodynamic effects of epinephrine during endoscopic sinus surgery: a randomized clinical trial. *Arch Otolaryngol Head Neck Surg*. 2009;135(10):1005–1009. doi: 10.1001/archoto.2009.144.
3. Averbukh SS, Brevda IS, Lubotsky DN, Semenova OS. The palatine access to the ganglion sphenopalatinum and to the second branch of the trifacial nerve. *Ann Surg*. 1935;101(3):819–826. doi: 10.1097/00000658-193503000-00001.
4. Jonas N, Viani L, Walsh M. Sphenopalatine artery ligation under local anesthesia: a report of two cases and review of the literature. *Local Reg Anesth*. 2010; 3:1–4. doi: 10.2147/LRA.S6770.
5. Wormald PJ, Athanasiadis T, Rees G, Robinson S. An evaluation of effect of pterygopalatine fossa injection with local anesthetic and adrenalin in the control of nasal bleeding during endoscopic sinus surgery. *Am J Rhinol*. 2005;19(3):288–292.
6. Boezaart AP, van der Merwe J, Coetzee A. Comparison of sodium nitroprusside- and esmolol-induced controlled hypotension for functional endoscopic sinus surgery. *Can J Anaesth*. 1995;42(5 Pt 1):373–376. doi: 10.1007/BF03015479.
7. Schubert MS. Allergic fungal sinusitis: Pathogenesis and management strategies. *Drugs* 64:363–374, 2002
8. Ajmani ML. Anatomical variation in position of the greater palatine foramen in the adult human skull. *J Anat*. 1994; 184:635–637
9. Saarnivaara L, Klemola UM, Lindgren L. Labetalol as a hypotensive agent for middle ear microsurgery. *Acta Anaesthesiol Scand*. 1987;31(3):196–201. doi: 10.1111/j.1399-6576.1987.tb02549.x.
10. Ozdek A, Bayır O, Dündar Y, Tatar EC, Saylam G, Korkmaz MH. Closure of nasal septal perforations using bilateral intranasal advancement/rotation flaps. *Kulak Burun Bogaz Ihtis Derg*. 2014;24(3):123–128. doi: 10.5606/kbbihtisas.2014.20092.
11. Lepere, A. (1993). Maxillary nerve block via the greater palatine canal: new look at an old technique. *PubMed*, 2(4), 195–197.
12. Aoun G, Zaarour I, Sokhn S, Nasseh I. Maxillary nerve block via the greaterpalatine canal: An old technique revisited. *J IntSocPrev Community Dent*. 2015;5(5):359-64.
13. Bharadwaj VK, Novotny GM. Greater palatine canal injection: an alternative to the posterior nasal packing and arterial ligation in epistaxis. *J Otolaryngol*1986; 15:94–100.
14. **Valdes, C J, et al. “Does Pterygopalatine Canal Injection with Local Anaesthetic and Adrenaline Decrease Bleeding during Functional Endoscopic Sinus Surgery?” *The Journal of Laryngology & Otology*, vol. 128, no. 9, 28 Aug. 2014, pp. 814–817, <https://doi.org/10.1017/s0022215114001790>.**

15. Riegle EV, Gunter JB, Lusk RP, Muntz HR, Weiss KL. Comparison of vasoconstrictors for functional endoscopic sinus surgery in children. *Laryngoscope*. 1992;102(7):820–823. doi: 10.1288/00005537-199207000-00012.
16. Jacobi KE, Böhm BE, Rickauer AJ, Jacobi C, Hemmerling TM. Moderate controlled hypotension with sodium nitroprusside does not improve surgical conditions or decrease blood loss in endoscopic sinus surgery. *J Clin Anesth*. 2000;12(3):202–207. doi: 10.1016/S0952-8180(00)00145-8.
17. Yoo HS, Han JH, Park SW, Kim KS. Comparison of surgical condition in endoscopic sinus surgery using remifentanil combined with propofol, sevoflurane, or desflurane. *Korean J Anesthesiol*. 2010;59(6):377–382. doi: 10.4097/kjae.2010.59.6.377.