

**A study of Constipation after surgery for anorectal malformations in a tertiary hospital
in Central India**

Authors:

1. 1st and corresponding author- Dr.Sanjiv Warkhede
Assistant professor, Department of General Surgery,Sukh Sagar Medical College
Mukunwara ,Bargi, Jabalpur.
2. Dr.Sanjay Ghate
Associate Professor, Department of General Surgery, GMC, Chandrapur
3. Dr.Pranay Gandhi
Assistant Professor, Department of Community Medicine, GMC, Chandrapur

*Corresponding Author:

Dr.Sanjiv Warkhede

ABSTRACT

Background: Perianal sepsis and anal fistula are troublesome diseases in the field of colorectal surgery due to recurrence and fecal incontinence.

Aim: To investigate the role of "one-stage complex anal fistula resection with anal sphincter reconstruction without stool diversion" on fecal incontinence and recurrence.

Methodology: This is a prospective cohort study of 350 patients with complex perianal fistulas who underwent fistulectomy and anal sphincter reconstruction (primary suture repair) without stool diversion; Patients were followed up for 1 year after the operation after complete healing of the wound. Suppression of stool and gas was assessed using the Wexner score and fistula recurrence was assessed clinically and radiologically using MRI. Out of 350 patients, only 8 had different degrees of fecal incontinence: 4 had gas incontinence, 4 had soil incontinence, and 16 had relapse after 3 months. 12 people relapsed after 6 to 9 months. Confirmatory MRI was also performed at the end of the follow-up period and two patients had hidden fistula ducts leading to the upper abscess cavity. This resulted in 32 recurrent cases. 10 patients had delayed wound healing.

Conclusion:As compared to other treatment methods for complex anal fistulas described in the literature, one-stage surgery (hemorrhoidectomy with primary sphincter repair) has a lower risk of incontinence, a lower recurrence rate, and better anal fistula formation. It gave good results in terms of wound healing.

Keywords: anal fistula, one stage surgery.

INTRODUCTION

A fistula is an abnormal junction between two epithelial surfaces, and is lined with granulation tissue. A perianal fistula is a fistula between the anal canal or rectum and the skin around the edge of the anus (anal fistula). Anal fistula is one of the conditions of perianal sepsis. Usually, it develops after an anorectal abscess that can cause various symptoms such as pain, itching and discharge.¹ Anal fistula affects 1 in 10,000 of the general population every year. ² Eighty percent of anal fistulas are secondary to cryptogenic abscesses. from infected anal glands which can then spread to other parts of the perianal region. Infection can then track to other epithelial surfaces in several directions such as the vagina forming an ano-vaginal fistula or the perianal skin forming a perianal fistula.²

Treatment of anal fistula is a major therapeutic challenge. The main challenge is to eliminate the inflammatory process to reduce the incidence of recurrence without affecting rectal continence. Normal continence is maintained by a complex interaction of the anal sphincter muscles and pelvic floor innervation. ³ Nowadays, incisional and nonincisional procedures are used in the treatment of anal fistula with recurrence rates between 0 and 65% and postoperative incontinence between 0 and 63%. With a more radical approach, the recurrence rate decreases, but the risk of incontinence increases. ⁴ Fistulotomy has been described as the treatment of choice for subcutaneous and inter-sphincteric anal fistulae with or without marsupialization with very good cure rates. However, the risk of incontinence increases with the amount of external sphincter muscle that is divided.⁴

For fistulectomy with primary sphincter reconstruction (FPSR) as a cutting procedure, promising results were observed in a small number of publications, particularly for patients with pre-existing incontinence due to previous therapies.⁵

The aim of this study was to assess feasibility of one stage fistulectomy with primary reconstruction of anal sphincter to permanently eliminate high trans-sphincteric and supra-sphincteric anal fistula to achieve healing while preserving anal canal function and continence.

MATERIALS AND METHODS

This was a prospective cohort study done in the department of General Surgery in a tertiary medical college from 2020 to 2022 on patients of high complex trans-sphincteric anal fistula. 350 patients, 224 males and 126 females, between the ages of 18 and 60 years diagnosed with high anal fistula. The following patients were included in the study:

Patients with high complex trans-sphincteric anal fistula. We mean by high complex fistula is the high trans-sphincteric perianal fistulae which we define as the fistulae which involve more than 50% of the external anal sphincter and the supra-sphincteric perianal fistulae which we define as the fistulae which extended completely above the external anal sphincter.

The following patients were excluded from the study:

1. Patients with simple anal fistula.
2. Patients with preoperative incontinence.
3. Patients with comorbidity and chronic illness affecting healing process such as, patients diagnosed with any immune system compromising disease and patients diagnosed with chronic inflammatory bowel diseases.

4. Patients diagnosed with acute anal sepsis.

The study group included 350 consecutive patients (224 men and 126 women) with a superior diagnosis of trans-sphincteric and supra-sphincteric anal fistula from 2020, aged 18 to 60 years. A proper history is taken of previous illnesses or disorders, especially immunocompromised or chronic inflammatory diseases and previous anal surgery. A general examination to assess the patient's suitability for surgery, a local digital rectal examination to assess the continuity of the anal canal, and to determine the external and internal openings are started. M.R.I. A fistulogram (see Figure 1) was used as a standard method to correctly identify the fistula tract and to select patients who met our criteria to record the relationship with the sphincter complex. All patients were also assessed preoperatively using the Wexner score for incontinence, and all patients with fecal incontinence were excluded from the study. All patients signed an informed consent before operation regarding operative steps and complications. All patients had had bowel preparation with rectal enema the night before the operation.

Patients were anaesthetized with general anesthesia, put in lithotomy position and the skin was then draped. After identification of the external fistula orifice probing of the fistula tract with identification of the fistulous tract and internal orifice by injecting of diluted methylene blue in the tract. Fistula was laid open and fistulectomy then conducted and dissected with diathermy cautery help (Fig. 2). Then Primary repair-without overlap-of the sphincter with Vicryl 2/0 with proper hemostasis using coagulation diathermy then injection of local anesthetic for post-operative pain control (look Fig. 3). All excised tissue were sent for histopathological examination (Fig. 4). All the surgeries were performed by experienced surgeon expert in colorectal surgery.

All patients were maintained on antibiotics and appropriate pain killers during the postoperative period. Perianal cleansing was performed with a sitz bath after each bowel movement. After discharge from the hospital, sitz baths continued 8 hours daily and after each bowel movement.

Follow-up was done every two weeks for the 1st 2 months and then monthly follow-up was started for 1 year. Clinical evaluation of recurrence and rectal incontinence. After 1 year, fistula recurrence and rectal continence were fully assessed by a thorough clinical examination and using the Wexner score. 6 At the end of the follow-up period MRI fistulogram was again performed for all patients. To ensure the absence of hidden recurrences that are not clinically detectable. It is worth mentioning that this study was initially conducted on 396 patients, however 46 patients did not complete their follow-up and were excluded from the study. This concludes the above 350 patients.

RESULTS

The study was conducted on a total of 350 patients with age limit (18–60) with 224 males and 126 females. Age and gender distribution are shown in Table 1.

| | | |
|-----------------|----------------------------------|-------------------|
| Characteristics | | |
| Age | Minimum 18, maximum 60 | Mean: 37.48 |
| Gender (350) | Males 224 (64%) | Females 126 (36%) |
| Recurrence | Number of recurrent cases: 32 | Percentage: 9.1% |
| Continenence | Incontinent cases: 8 | Percentage 2.28% |
| Wound healing | Delayed up to 8 weeks: 10 | Percentage: 2.85% |

Recurrent cases

The patients were followed up to 1 year. After 3 months 16 patients had recurrence. 14 of those patients recur with high trans-sphincteric fistulae and 2 patient recur with low branching trans-sphincteric fistula. After 6–9 months 8 patients develop recurrence in the form of high trans-sphincteric fistulae and 4 patients developed low fistulae. At the end of follow up period upon performing the confirmatory MRI, 4 patients showed hidden fistulous tracts ending into a high abscess cavity, those patients were complaining of vague anal pain with no visible external opening. This ends up into total of 32 recurrent cases. This is shown in Table 1.

Incontinence

8 patients (2.3%) were complicated with incontinence. 4 of those 8 patients (2 males and 2 females) experienced gas incontinence two months postoperatively (score 3 in Wexner), the patients have responded well to biofeedback and regain continence after 2 months of biofeedback. The histo-pathological examination of the fistulous tract revealed chronic nonspecific inflammation for both patients. The other 4 male patients experienced soiling (Wexner's score 4) which was investigated and treated accordingly, this is shown in Table 1.

Wound healing

10 patients (2.85%) had experienced a delay in the wound healing (more than 8 week) the rest of the patient had average time of wound healing around 3–4 week. The histo-pathological examination results for the patients who experienced the delayed healing process showed two patients with Crohn's disease, two with hidradenitis suppurativa and one with non-specific inflammation. The 2 cases of Chron's disease and the case of non-specific inflammation developed recurrence of the perianal fistula. This is shown in Table 1.

If the patients who had an un-diagnosed specific disease as Chron's disease and hidradenitis suppurativa are excluded from the analysis of the results, the recurrent cases will decrease to 28 cases as there were 4 cases from the 32 recurrent cases had Chron's disease. Also the

number of patients with delayed wound healing will fall to 2 case as out of the 10 patients who experienced delayed wound healing 4 patients were diagnosed as Chron's disease and 4 patients with were diagnosed as hidradenitis suppurativa (look Table 1).

DISCUSSION

In this manuscript, we tried to investigate the safety of fistulectomy for superior trans-sphincteric and supra-sphincteric perianal fistula, as a first-line sphincter treatment, in terms of recurrence and fecal incontinence. Our study showed a low recurrence rate (9.1%) and dissatisfaction (2.28%) after the procedure. Also, our study showed that delayed wound healing up to 8 weeks was low (2.85%).

Although anal fistula is a very common problem that has been studied extensively, some of the more complex types still represent a complex surgical problem. The goal of surgery for anal fistula is to completely and permanently eliminate all sepsis, achieve cure, and reduce the incidence of recurrence while maintaining anal function and continuity. 7 Depending on the classification of the fistula before the operation and its relationship with the sphincters, surgical treatment can vary. 8

Traditionally, the fistula is left open, allowing healing to begin completely. In this type of operation, the higher the fistula, the more severe the muscle, which can lead to insufficiency. Aggressive fistulotomy can lead to postoperative fecal morbidity, while appropriate conservative treatment can lead to recurrence of fistula.9 The closer the track is to the sphincter, the greater the continence problem. Dissection of more than 30-50% of the external sphincter can cause significant functional deficits.

In 2010, Soltani A and Kaiser AM stated that many treatment options have been described for the treatment of trans-sphincteric anal fistula, but most of them do not fully meet the criteria

for a safe optimal procedure, which should have a high healing rate and low cost, no repetition and no climate effect.¹¹

In 1985, Parkash S and colleagues described direct reconstruction of the sphincter after fistulotomy to reduce this high rate of incontinence.¹²

In a 2009 study of 33 patients, fistulectomy with anal sphincter reconstruction and initial closure of the internal orifice showed good functional results and no disruption.¹³ This study agrees with our study, which showed low recurrence and morbidity.

Also, our results agree with the latest study by Arroyo A and colleagues in 2012. However, the recurrence rate was 8.6% in their study and 9.1% in our study. They also reported an increase in complaints in patients with complications and minor complications.

Fistula surgery is either conservative in cost of recurrence or aggressive in cost of climate. We believe that this technique, if performed by a colorectal surgeon, will solve this important problem of reducing recurrence rates while maintaining sphincter continence function.

In addition, we believe that direct sphincter repair is better than overlapping, because subsequent analysis puts undue stress on repair with increased intracranial pressure and avoids excessive dissection to sphincter ischemia. Furthermore, we believe that muscle repair after aggressive fistula surgery and muscle dissection solves the problem of recurrence and dysfunction in the same setting, even in patients with preoperative anal dysfunction, with acceptable results.

Conclusions:

Compared to other treatment methods for complex trans-sphincteric anal fistula found in the literature, it has been found that one-stage surgery (fistulectomy with primary sphincter repair) offers good results with respect to acceptable risk of incontinence, relatively high

recurrence rate and good fistula healing. Wound healing. However, the limitations of this study are the need for long follow-up which can reach 2 years which may increase the recurrence rate.

FUNDING

None

ACKNOWLEDGEMENT

None

CONFLICTS OF INTEREST

The authors declare no conflicts of interest.

REFERENCES

1. S.K. Jain, R.C.M. Kaza, M. Pahwa, S. Bansal. Role of cyanoacrylate in the management of low fistula in ano: a prospective study *Int J Colorectal Dis*, 23 (2008), pp. 355-358
2. J.D. Corson, R.C.N. Williamson (Eds.), *Surgery*, Mosby, London (2001), pp. 12-14
3. A. Rojanasakul, J. Pattanaarun, C. Sahakitrungruang, K. Tantiphlachiva. Total anal sphincter saving technique for fistula-in-ano; the ligation of intersphincteric fistula tract *J Med Assoc Thai*, 90 (2007), pp. 581-586
4. A. Arroyo, J. Perez-Legaz, P. Moya, et al. Fistulotomy and sphincter reconstruction in the treatment of complex fistula-in-ano: long-term clinical and manometric results. *Ann Surg*, 255 (2012), pp. 935-939

5. F. Perez, A. Arroyo, P. Serrano, F. Candela, A. Sanchez, R. Calpena. Fistulotomy with primary sphincter reconstruction in the management of complex fistula-in-ano: prospective study of clinical and manometric results. *J Am Coll Surg*, 200 (2005), pp. 897-903
6. J.M.N. Jorge, S. Wexner. Etiology and management of fecal incontinence *Dis Colon Rectum*, 36 (1993), pp. 77-97
7. Y. Kim, Y.J. Park. Three- dimensional endoanal ultrasonographic assessment of anal fistula with and without H₂O₂ enhancement. *World J Gastroenterol*, 15 (2009), pp. 4810-4815
8. F. Soew-Choen, S. Burnett, C.I. Bartram, R.J. Nicholls. Comparison between anal endosonography and digital examination in the evaluation of anal fistulas. *Br J Surg*, 78 (1991), pp. 445-447
9. M. Davies, D. Harris, P. Lohana, et al. The surgical management of fistula-in-ano in a specialist colorectal unit. *Int J Colorectal Dis*, 23 (2008), pp. 833-83
10. M.H. Whiteford, J. Kilkenney III, N. Hyman, et al. The standards practice task force, the American Society of Colon and Rectal Surgeons, Practice parameters for the treatment of perianal abscess and fistula-in-ano (Revised). *Dis Colon Rectum*, 48 (2005), pp. 1337-1342
11. A. Soltani, A.M. Kaiser. Endorectal advancement flap for cryptoglandular or Crohn's fistula-in-ano. *Dis Colon Rectum*, 53 (2010), pp. 486-495
12. S. Parkash, V. Lakshmiratan, V. Gajendran. Fistula-in-ano (treatment by fistulectomy, primary closure and reconstitution) *Aust N Z J Surg*, 55 (1985), pp. 23-27
13. P. Jivapaisarnpong. Core out fistulectomy, anal sphincter reconstruction and primary repair of internal opening in the treatment of complex anal fistula. *J Med Assoc Thai*, 92 (2009), pp. 638-642

Figure 1: MRI fistulogram for a high trans-sphincteric fistula (red arrows): a) Sagittal, b) Coronal.

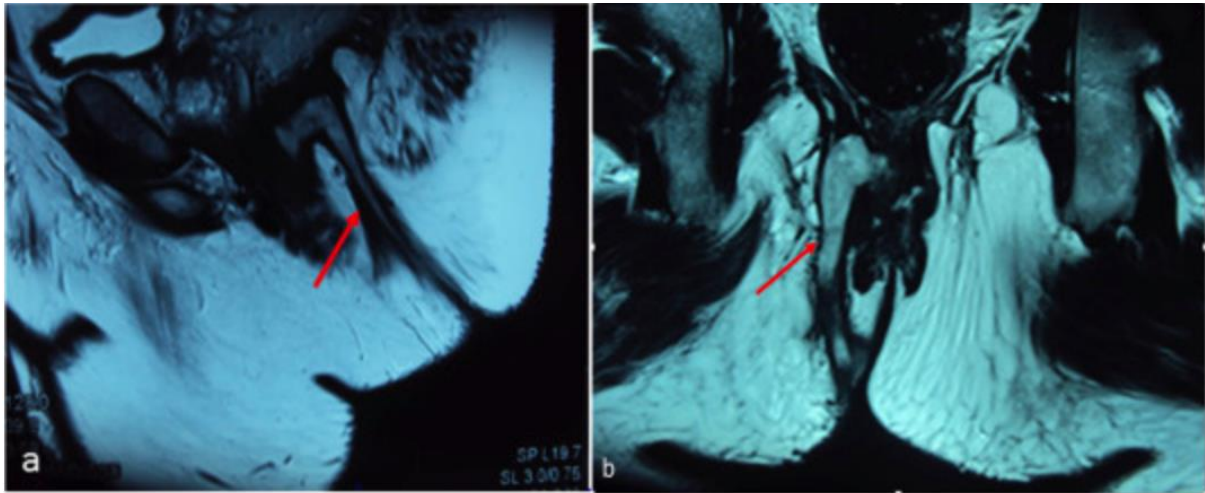


Figure 2: Fistula laid open then excised (fistulectomy).

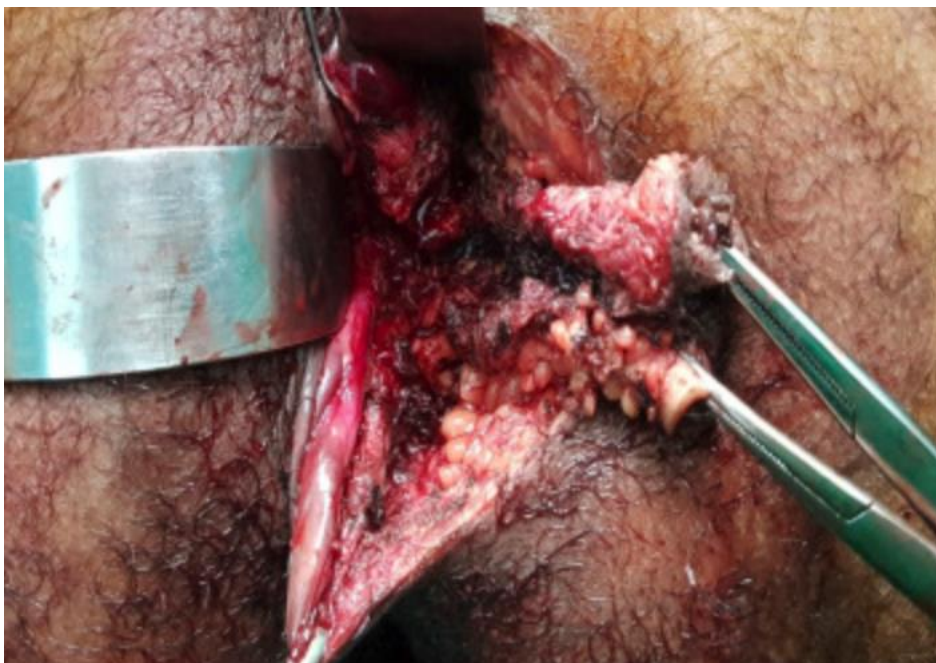

Figure 3: Muscle repair after excision of the fistula.

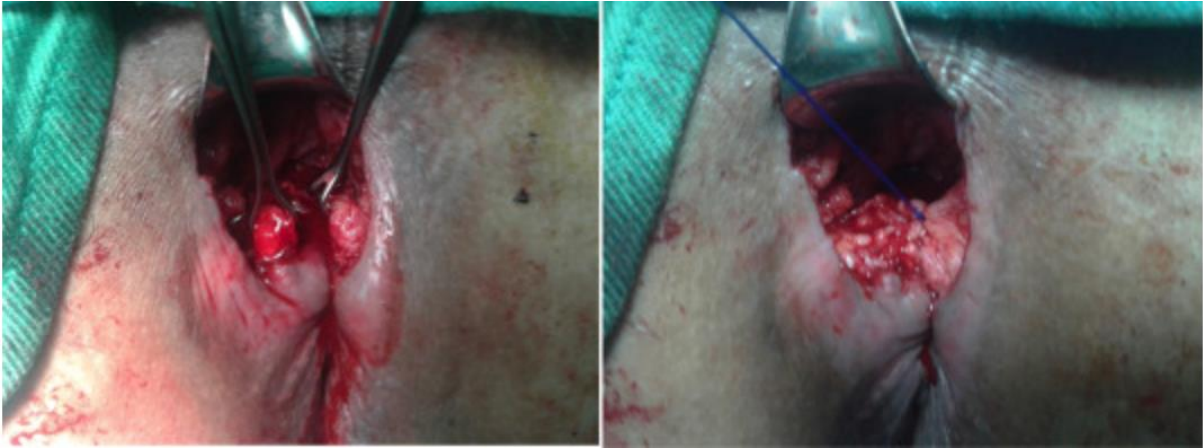

Figure 4: Fistula after excision.

