

Original Research Article

Diagnosis and Staging of Carcinoma Uterine Cervix by MRI

Dr. Sadananda Billal¹, Dr. Sanathkumar S.², Dr. Pallavi G.³

¹Assistant Professor, Department of Radiology, Shivamogga Institute of Medical Sciences, Shimogga, Karnataka, India.

²Junior Resident, Department of Radiology, Mysore Medical College and Research Institute, Mysore, Karnataka, India.

³Junior Resident, Department of Radiology, Mysore Medical College and Research Institute, Mysore, Karnataka, India.

Corresponding Author

Dr. Pallavi G., Junior Resident, Department of Radiology, Mysore Medical College and Research Institute, Mysore, Karnataka, India.

Received: 22-12-2023 / Revised: 27-12-2023 / Accepted: 25-01-2024

ABSTRACT

Background

In this study, we wanted to evaluate the efficacy of MRI in the assessment of important prognostic factors in carcinoma cervix like tumour size, involvement of parametrium, pelvic side wall, adjacent organs and the lymph nodal status and how it alters the plan of management and correlate MRI findings with clinical FIGO staging of carcinoma cervix.

Methods

This was a hospital-based cross-sectional study conducted among histopathologically proven cases of carcinoma cervix presented to the Department of Radiodiagnosis attached to Mysore Medical College and Research Institute for 18 months from January 2020 to June 2021.

Results

The most common histopathological type in both newly diagnosed cases and post-treatment cases was squamous cell carcinoma and the remaining was constituted by adenocarcinoma. In our study, there were 18 biopsy-proven new cases, 32 old cases. MRI proved the best in identifying mass better than clinical identification. The accuracy, sensitivity and positive predictive value of MRI in newly diagnosed cases in our study were 83.33%, 88.24%, and 93.75%, respectively.

Conclusion

MRI is better at delineating the invasion of adjacent organs. MRI can replace cystoscopy and sigmoidoscopy in identifying bladder and rectal wall invasion. A combination of T2W imaging and diffusion-weighted imaging would be the optimal technique for imaging both new and post-treatment cases. T2W and diffusion-weighted images are the best sequences not only in identifying recurrence, but also in excluding false positives in already treated patients.

Keywords: MRI, Carcinoma Cervix, Parametrium, Pelvic Side Wall.

INTRODUCTION

Carcinoma cervix is the most common gynaecological cancer in India and the second most common gynaecological cancer worldwide. It predominantly affects multiparous women, and it is transmitted by human papillomavirus infection. MRI can tell accurately about the urinary bladder and rectal invasion by carcinoma cervix. Therefore, invasive procedures such as cystoscopy and sigmoidoscopy can be avoided by using non-invasive diagnostic modalities like MRI. MRI is not only useful for preoperative staging, but it also helps in the identification of recurrent/residual tumours in treated patients. Radiological staging by MRI is better than clinical staging most of the time.

OBJECTIVES

- To evaluate the efficacy of MRI in the assessment of important prognostic factors in carcinoma cervix like tumour size, involvement of parametrium, involvement of pelvic side wall, involvement of adjacent organs and lymph nodal status and how it alters the plan of management.
- To correlate MRI findings with clinical FIGO staging of carcinoma cervix.

MATERIALS AND METHODS

This was a hospital-based cross-sectional study conducted among histopathologically proven cases of carcinoma cervix presenting to the Department of Radiodiagnosis attached to Mysore Medical College and Research Institute for 18 months from January 2020 to June 2021.

Inclusion Criteria

Histopathologically proven cases of carcinoma cervix referred to our department for MR imaging.

Exclusion Criteria

Patients with cardiac pacemakers, new implants, clips within the body and other contraindications of MR imaging like claustrophobia were excluded.

Method of Collection of Data

Histopathologically proven cases of carcinoma cervix that were referred to the Department of Radiodiagnosis, MMCRI were included. After obtaining permission from the institutional medical research ethics committee and taking informed consent from the patients, they were subjected to MRI pelvis using 1.5 Tesla GE optima MR360 machine.

Sample Size Estimation

The sample size was calculated using the formula

$$n = \frac{z^2pq}{d^2}$$

Where

p = Prevalence of carcinoma cervix, which was 4% in our hospital.

q = (1-p) = 96%

d = Level of precession measured as absolute error, which is 7%.

z = Standard normal variate for 95% confidence interval, which is 1.96%.

Therefore, the minimum sample size according to the above data was 30. Due to the availability of the cases data was collected from 50 patients who were biopsy-proven cases of carcinoma cervix.

Statistical Analysis

Categorical data were represented in the form of frequencies and proportions. The chi-square test was used as a test of significance for qualitative data. Continuous data were represented as mean and standard deviation. An independent t-test was used as a test of significance to identify the mean difference between two quantitative variables. A P-value (Probability that the result is true) of <0.05 was considered statistically significant after assuming all the rules of statistical tests. MSEXcel, SPSS version 22 (IBM SPSS Statistics, Somers NY, USA) was used to analyse data.

RESULTS

A total of 50 patients who were biopsy-proven cases of carcinoma cervix were included in the study. Both newly diagnosed and patients treated with chemoradiotherapy were included. FIGO stage was assigned both clinically and with MRI and the parameters were compared.

Table 1

Category	No. of Patients	Percentage
Newly diagnosed	18	36%
Recurrent	32	64%
P-value	0.048	
Category of cases		
Category	No. of patients	Percentage
Married	45	90%
Unmarried	05	10%
P value	0.001	
Distribution of cases based on marital status		
Age (years)	No. of Patients	Percentage
<40	4	8%
41-50	19	38%
51-60	16	32%
>60	11	22%
P-value	0.016	
Age distribution		
Menstrual status	Number of Patients	Percentage

Premenopausal	15	30%
Postmenopausal	29	58%
Post hysterectomy	6	12%
P value	0.001	
Menstrual status		
Duration post-RT (N=32)	No. of Patients	Percentage
<6 months	07	21.9%
6-12 months	07	21.9%
1-5 years	10	31.2%
>5 years	08	25%
P-value	0.861	
Interval between RT and imaging		
Hydroureteronephrosis	No. of patients	Percentage
Present	7	14%
Absent	43	86%
P-value	0.001	
Presence or absence of hydroureteronephrosis		
Hydrometra/Pyometra	No. of Patients	Percentage
Present	20	40%
Absent	30	60%
p-value	0.157	
Presence or absence of hydrometra/pyometra		

Two categories of patients were considered for the study-18 newly diagnosed patients (36% of the study population) and 32 treated cases (64% of the study population).

In our study, the majority of the patients i.e., 90% of the study population were married. 10% of the patients were unmarried.

The age group of patients in this study varied from 36 years to 73 years. In general, the majority of the patients belonged to the age group of 41-50 years (38% of the study population) followed by 51-60 years (32% of the population). 11 patients belonged to > 60 years of age. 4 patients belonged to less than 40 years of age.

Among the new cases diagnosed, the majority of them belonged to the age more than 60 and the age group 41-50 yrs. But, among the recurrent cases, the common age group was 41- 50 years and 51-60 years.

The most common presenting symptom was white discharge according to our study (seen in 58% of the study population) followed by lower abdominal pain (seen in 52% of patients).

In our study, the majority of the patients, 29 (58%) belonged to the post-menopausal age group, 15 patients (30%) belonged to the premenopausal age group. Six patients (12%) had undergone subtotal hysterectomy.

Radiotherapy was given to 32 patients totally and most of them (10 patients, 31.2%) were referred for MRI during 1- 5 years followed by more than 5 years.

Hydroureteronephrosis is an indirect sign of pelvic sidewall invasion and was noted in 7 patients

(14%); out of these 7 cases, 4 were new cases and 3 were recurrent cases.

In our study, hydrometra was present in 20 cases (40%). Among these, 10 cases were newly diagnosed and 10 patients were post- treatment cases. Among the 10 post-treatment cases, 9 patients had a demonstrable mass lesion on MRI.

Newly Diagnosed Cases through Histopathology (N=18)

Table 2

Clinically suspected mass	No. of patients	Percentage
Present	16	88.9%
Absent	2	11.1%
P-value	0.001	
Clinically suspected mass in new cases		
Cystoscopy	No. of patients	Percentage
Bladder invasion	1	5.5%
Normal	15	83.3%
Not done	2	11.1%
P-value	0.002	
Cystoscopy findings in new cases		
Sigmoidoscopy	Number of patients	Percentage
Growth rectum	1	5.55%
Rectal invasion	1	5.55%
Normal	14	77.8%
Not done	2	11.1%
P-value	0.001	
Sigmoidoscopy findings in new cases		
Histopathology	Number of patients	Percentage
Squamous Cell Carcinoma	17	94.4%
Adenocarcinoma	1	5.6%
P-value	0.001	
Histopathological types in new cases		

In our study, there were 18 biopsy-proven new cases. Clinically, mass was identified in 16 cases (88%) and was not suspected for 2 cases.

Out of 16 cases with clinical suspicion of mass, MRI showed the presence of a mass in 15 cases. MRI was not able to detect one clinically suspected case. Thus, MRI showed the presence of a mass in 17 cases including those 2 cases where there was no clinical suspicion of mass. The accuracy, sensitivity, and positive predictive value of MRI in newly diagnosed cases were 83.33%, 88.24%, and 93.75%, respectively. According to clinical FIGO staging, the majority of cases belonged to stage IIB. But according to MRI FIGO staging, the majority of cases belonged to stage IVA. No cases were staged as IIIC clinically. However, on MRI 2 IIIC cases were detected.

In our study, significantly, 2 cases which were diagnosed as stage IIIB clinically were found to be stage IVB on MRI with bladder, rectal invasion and distant metastasis. 1 case which was diagnosed as IIIA was found to be IVA on MRI with bladder, and rectal invasion. 1 case which was diagnosed as IIIB was found to be IVA on MRI with bladder, and rectal invasion. Two cases of clinically

staged II were found to have bladder invasion on MRI and hence staged as IV A. One case which was clinically diagnosed as IA showed bladder invasion on MRI, thus upstaged as IVA. One case which was clinically diagnosed as IVA with cystoscopy showed bladder invasion, rectal filtration in sigmoidoscopy came out to be IVA on MRI. Cystoscopy detected bladder invasion in only one case. However, on MRI, 7 cases were diagnosed. One patient had both carcinomas of the rectum and cervix.

Apart from this one more case was identified with rectal infiltration in sigmoidoscopy. However, MRI showed 3 cases of rectal infiltration. The most common histopathological type was squamous cell carcinoma which was seen in 94.4% of the newly diagnosed cases and the remaining 5.6% was constituted by adenocarcinoma.

In our study, among the 18 newly diagnosed cases (biopsy-proven), T2W, DWI and contrast-enhanced imaging showed lesions in 16, 17 and 15 cases respectively. One case did not show T2 hyperintensity or contrast enhancement. However, the lesion was detected in DWI. DWI- MRI was able to diagnose 94.4% of cases, T2 W images detected 16 cases 88.8%, and contrast images detected 15 cases, 83.3% cases. A combination of T2 W and DWI detected a lesion in 16 cases. A combination of T2 W and contrast enhancement detected a lesion in 15 cases. MRI staging correlated with clinical staging in 22.2% of new cases and there was upstaging with MRI for 55.5% of cases and downstaging for 22.2% of cases.

Recurrent Cases

Table 3

Clinically suspected mass	Number of patients	Percentage
Present	24	75%
Absent	8	25%
P-value	0.001	
Presence or absence of clinically suspected masses in recurrent cases		
Clinically Suspected Mass	MRI Findings Present	MRI Findings Absent
Present (24)	18	6
Absent (8)	2	6
P-value	0.001	
Clinically suspected mass with MRI correlation in recurrent cases		
Histopathology	Number of patients	Percentage
Squamous cell carcinoma	30	93.8%
Adenocarcinoma	2	6.2%
P- Value	0.001	
Pretreatment histopathological types in recurrent cases		
Post radiation complications	Number of cases	Percentage
Bone marrow changes	7	21.8%
Cystitis	5	15.6%
Proctitis	6	18.7%
Pelvic lipomatosis	1	3.1%
Free fluid	1	3.1%
Vesicovaginal fistula	1	3.1%

Ureteral stricture	1	3.1%
P-value	0.027	
Post radiation complications		

In our study considering the 32 post- treatment cases, clinically, mass was suspected in 24 patients (75% cases). In 8 cases, there was no clinical suspicion of mass.

MRI showed the presence of a mass lesion in 18 patients out of 24 clinically suspected mass patients. In eight patients, mass was not suspected clinically (25% cases). But, MRI showed the presence of a mass lesion in 2 cases among these 8 cases. The accuracy, sensitivity, specificity, and positive and negative predictive values of MRI in recurrent cases were 75%, 90%, 50%, 75% and 75% respectively.

Squamous cell carcinoma was the most common histological subtype in post-treatment cases also (in 30 patients). Adenocarcinoma was seen in 2 patients.

In our study, altogether 20 patients showed a lesion on MRI. The number of patients showing lesions on T2W, DWI and contrast studies was 19, 20 and 17 respectively. 3 patients showed T2 hyperintensity and diffusion restriction in the cervix. However, in the contrast study, there was no enhancement of tumours in these three cases.

In one case, imaging was done 2 months after radiotherapy to assess the residual tumour which was clinically suspected. MRI of the patient showed no obvious lesion in T2W images whereas diffusion restriction was noted with early arterial phase enhancement in dynamic contrast studies. Thus, a diagnosis of residual tumour was made for the patient.

In our study, the primary group of lymph nodes (parametrial, obturator, external and internal iliac nodes) was involved in 4 patients among the newly diagnosed. A secondary group of lymph nodes was involved in 2 patients. One patient showed involvement of both primary and secondary groups of lymph nodes.

In the post-treatment cases, the primary group of nodes was involved in 6 patients and the secondary group was in 2 patients.

One of the important prognostic indicators is uterine body involvement in patients with carcinoma cervix. Of the total 50 cases, uterine body involvement by tumour was noted in 21 patients (42%). More number of cases, 52.3% with stage IV disease was found to have uterine body involvement in our study. 4 cases with IIIC, 5 cases with stage IIB disease and only 1 case with stage IB disease, showed involvement of the lower uterine body.

In our study, among the 21 cases with uterine body involvement, 6 patients showed primary lymph node metastasis and 2 patients showed secondary lymph node metastasis.

The mean size of the tumour is another impor

-tant prognostic factor. The mean size of the tumour in patients with stages IB, IIA, and IIB was 2.02 cm, 1.6 cm, and 4.46 cm respectively. The mean size of the tumour in patients with stage IIIC, IVA, and IVB was 5.15 cm, 5.85 cm, and 4.5 cm respectively.

There was nodal involvement if the mean size of the tumour crossed 4.40 cms and it was not seen in cases where the mean size of the tumour was 3.42 cms or lesser.

From our study, it was evident that post- radiation complications were more common to develop

after 3 years of radiotherapy.

The most common post-radiotherapy changes were fatty replacement of bone marrow (seen in 7 cases out of 32 post-radiotherapy cases, 21.8%) followed by proctitis and cystitis.

In new cases, a combination of T2W and DWI detected a lesion in 16 cases. A combination of T2W and contrast enhancement detected a lesion in 15 cases.

In recurrent cases, a combination of T2W imaging and DWI diagnosed 19 cases and a combination of T2W imaging and contrast studies diagnosed 16 cases.

For all the newly diagnosed cases staged with FIGO system using clinical examination and MRI, the correlation was the best for stage II B disease and higher staging was given with MRI to clinical stages I, II and III.

The accuracy, sensitivity, specificity, and positive and negative predictive values of MRI in new cases in our study were 83.33%, 88.24%, 0%, 93.75%, and 0% respectively.

The accuracy, sensitivity, specificity, and positive and negative predictive values of MRI in recurrent cases in our study were 75%, 90%, 50%, 75% and 75% respectively.

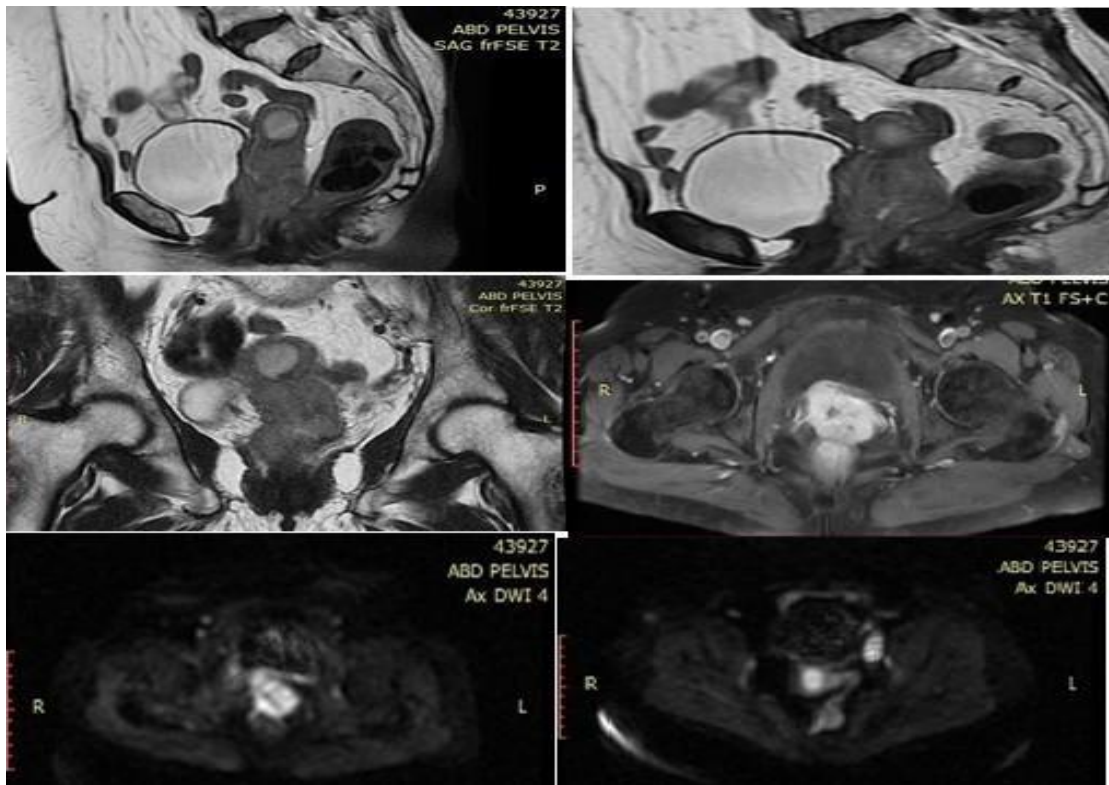


Figure 1: A 56-year-old female, mass in cervix involving lower myometrium and upper 1/3rd of vagina, hydrometra with thinning of myometrium, metastatic internal iliac lymph node and obliteration of fat plane with bladder and rectum- stage IIIc1.

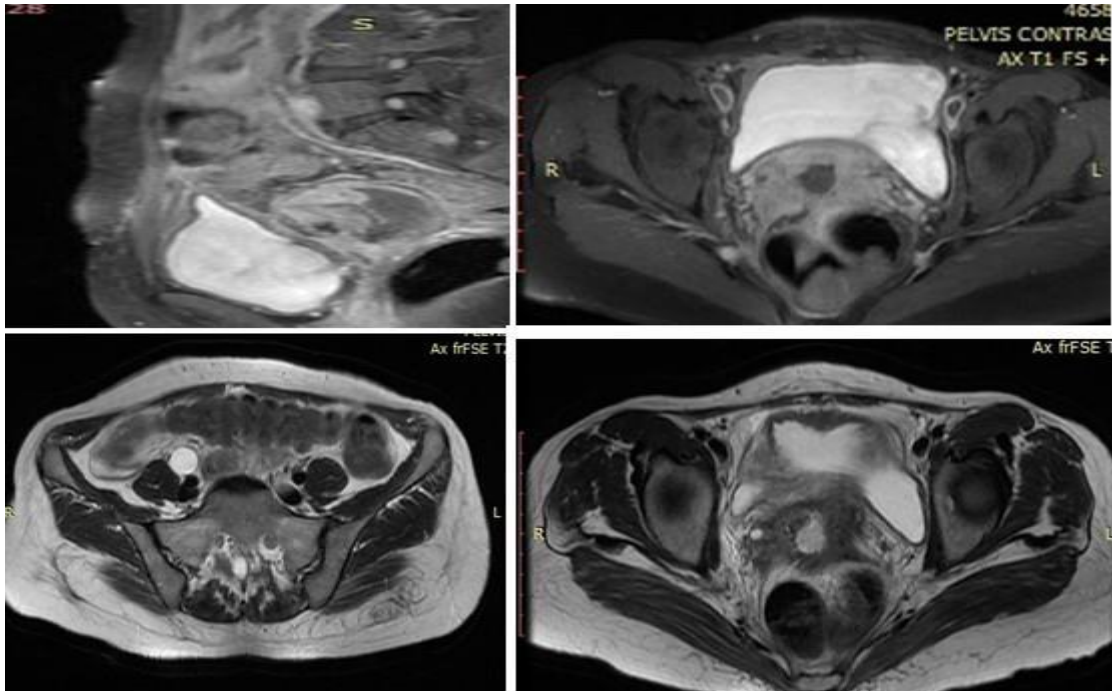


Figure 2: A 52-year-old female, k/c/o ca cervix, post hysterectomy, ill-defined solid cystic mass lesion involving vault encasing right terminal ureter causing proximal hydroureter-recurrent lesion.

DISCUSSION

Two categories of patients were considered for study – 18 newly diagnosed patients (36% of study population) and 32 treated cases (64% of study population).

The most common presenting symptom was white discharge according to our study (seen in 58% of the study population) followed by lower abdominal pain (seen in 52% of patients) [1].

Among the new cases diagnosed, majority of them belonged to age more than 60 years and between 41-50 years. But, among the recurrent cases, the common age group is 41- 50 years and 51-60 years. These patients must have been diagnosed with disease at an early age. Thus, it is seen that when the life expectancy is more, the possibility of recurrence of tumor is also more.

The most common histopathological type was squamous cell carcinoma in both newly diagnosed and recurrent cases in our study. Squamous cell carcinoma was the most common histopathological type in a study done by Emmett M, Gildea C, Nordin A, *et al* on 12,131 carcinoma cervix patients [2].

In our study, majority of the patients (58%) belonged to post-menopausal age group. Thus, the disease is more prevalent among post-menopausal women.

In our study, totally there were 18 biopsy proven new cases. Clinically, mass was suspected in 16 cases and was not suspected for 2 cases.

However, MRI showed the presence of mass in 17 cases, including those cases where there was no suspicion of mass. But MRI was not able to diagnose the lesion in 1 case which there was clinical

suspicion. In a study done by Nicolet V, Carignan L, Bourdon F *et al* shows that Stage IA disease can be staged only at histopathologic analysis as tumors are not visible at MRI [3].

It was also noted that accurate staging was lacking in cases who underwent hysterectomy for early-stage disease and for benign reasons. These patients would be benefited with MRI. The accuracy, sensitivity, positive predictive values of MRI in newly diagnosed cases are 83.33%, 88.24%, 93.75%, respectively.

MRI without contrast is reliable in assessing the parametrium and pelvic side wall invasion. T2W and DWI images give good information. Contrast material-enhanced T1-weighted imaging has not proved to be more accurate than T2-weighted imaging in this setting. This is in agreement with the study by Hawighorst H *et al* and Scheidler J *et al* [4,5].

MRI scores better in delineating the invasion of adjacent organs.

In our study, 3 cases which were diagnosed as stage III clinically were found to be stage IVA with MRI. 3 cases of clinically staged II were actually found to have bladder invasion on MRI and hence staged as IV A. Thus, MRI evaluation prevented unnecessary surgical intervention in these patients. Invasion of bladder and rectum can be ruled out with sufficient confidence with MRI. This is in accordance with the previous study done by Kim *et al* [6].

For all the newly diagnosed cases staged with FIGO system using clinical examination and MRI, correlation was the best for stage II B disease and higher staging was given with MRI to clinical stage III disease. MRI staging correlated with clinical staging in 22.2% of new cases and there was up staging with MRI for 55.5% of cases and down staging for 22.2% of cases.

This was due to the reason that all the stage III disease patients diagnosed clinically had minimal bladder wall/rectal wall invasion which was missed and the cases were misclassified. So, MRI is advocated in all advanced cases for proper staging and prognostication.

From our study, it is evident that there is no definite role for contrast study in all the cases which are newly evaluated. There is no added advantage of contrast over plain study. Among the 18 newly diagnosed cases (biopsy proven), T2W, DWI and contrast enhanced imaging showed lesions in 16, 17 and 15 cases respectively. DWI-MRI alone was able to diagnose 94.4% of cases, T2 W diagnose 88.8% and contrast images detected 83.3% cases.

In new cases, a combination of T2W and DWI detected lesion in 16 cases. A combination of T2W and contrast enhancement detected lesion in 15 cases. Thus, combination of T2W and DWI is better than T2W and contrast combination. This is in concordance with the studies done by Hawighorst *et al.*, and Schiedler J *et al.*, who found that no value is added by contrast enhanced imaging [4,5].

In our study, primary group of lymph nodes (parametrial, obturator, external and internal iliac nodes) was involved in 4 patients among the newly diagnosed. Secondary group of lymph nodes was involved in 2 patients. One patient showed involvement of both primary and secondary group of lymph nodes. This is lower than that reported by Drescher *et al* in his Study [7].

From our study involving post treatment cases, it is clearly evident that there is no added value of routine contrast imaging for all post radiotherapy cases. It has an added value in case of discrepancies between findings in T2W imaging and DWI where it serves as a problem solving tool. In our study, altogether

20 patients showed lesion on MRI. The number of patients showing lesions on T2W, DWI, and contrast studies are 19, 20 and 17 respectively. Diffusion restriction on MRI were diagnosed as recurrent lesions [8]. In recurrent cases, a combination of T2 W imaging and DWI is able to

diagnose 19 cases. 3 patients who showed T2 hyperintensity and diffusion restriction didn't show enhancement of the tumor in cervix.

A combination of T2W imaging and contrast study was able to diagnose only 16 cases. Kinkel *et al.* in his work found that in the first five months after radiotherapy, inflammatory changes may be responsible for the early enhancement that may mimic recurrence [9]. Thus, there is no added value of routine contrast imaging for all post radiotherapy cases.

In our study, MRI helped to exclude the patients with no recurrence of tumour or no residual mass in post treatment phase so that over treatment of these cases with radiotherapy could be avoided. It also aided in the diagnosis of recurrence in 2 cases which were clinically undiagnosed so that appropriate treatment could be instituted in these cases. One of the patients had pure parametrial nodal recurrence with no pelvic mass and MRI helped in the diagnosis and staging of this recurrent disease as stage IIC. The accuracy, sensitivity, specificity, positive and negative predictive values of MRI in recurrent cases in our study are 75%, 90%, 50%, 75% and 75% respectively.

In the post treatment cases, primary group of nodes was involved in 6 patients, secondary group in 2 patients. The most important prognostic indicators are size of the tumour, uterine body involvement by the tumour and nodal metastasis.

More number of cases with stage IV disease (11 patients) were found to have uterine body involvement in our study. Thus, uterine body involvement could be directly correlated with advanced stage of the disease.

Mean size of the tumour is another important prognostic factor as this could be correlated with the stage of the disease and nodal involvement [10]. It is also noted that there is nodal involvement if the mean size of the tumour crosses 4.40 cms.

In our study, hydrometra was present in 20 cases (40%). Among these, 10 cases were newly diagnosed, and 10 patients were post treatment cases. Among the 10 post treatment cases, 9 patients had demonstrable mass lesion on MRI. In one patient hydrometra was due to cervical stenosis.

From our study, it is evident that post radiation complications are more common to develop after 2-3 years of radiotherapy which also corresponds with the average time of recurrence. Since most of the patients are referred during this time to look for recurrence of tumour, more complications are also diagnosed during this time. The most common post radiotherapy changes are fatty replacement of bone marrow (seen in 7 cases out of 32 post radiotherapy cases, 21.8%) followed by proctitis and cystitis.

CONCLUSION

MRI is better at delineating the invasion of adjacent organs. MRI can replace cystoscopy and sigmoidoscopy in identifying bladder and rectal wall invasion. A combination of T2 W imaging and diffusion-weighted imaging would be the optimal technique for imaging both new and post-treatment cases. T2 and diffusion-weighted images were the best sequences not only in identifying recurrence but also in excluding false positives in already treated patients. The contrast study provides no additional information inferred from our study. The most important prognostic indicator was uterine body involvement in patients with carcinoma cervix. Uterine body involvement could be directly correlated with the advanced stage of the disease.

REFERENCES

1. Emmett M, Gildea C, Nordin A, Hirschowitz L, Poole J. Cervical cancer – does the morphological subtype affect survival rates? *J Obstet Gynaecol* 2018;38(4):548-55.
2. Emmett M, Gildea C, Nordin A, Hirschowitz L, Poole J. Cervical cancer –does the morphological subtype affect survival rates? *J Obstet Gynaecol* 2018;38(4):548-55.
3. Nicolet V, Carignan L, Bourdon F, Prosmann O. MR imaging of cervical carcinoma: a practical staging approach. *Radiographics* 2000;20(6):1539-40.
4. Hawighorst H, Schoenberg SO, Knapstein PG, Knopp MV, Schaeffer U, Essig M, *et al.* Staging of invasive cervical carcinoma and of pelvic lymph nodes by high resolution MRI with a phased-array coil in comparison with pathological findings. *J Comput Assist Tomogr* 1998;22(1):75-81.
5. Scheidler J, Heuck AF, Steinborn M, Kimmig R, Reiser MF. Parametrial invasion in cervical carcinoma: Evaluation of detection at MR imaging with fat suppression. *Radiology* 1998;206:125-9.
6. Kim SH, Han MC. Invasion of the urinary bladder by uterine cervical carcinoma: evaluation with MR imaging. *Am J Roentgenol* 1997;168(2):393-7.
7. Drescher CW, Hopkins MP, Roberts JA. Comparison of the pattern of metastatic spread of squamous cell cancer and adenocarcinoma of the uterine cervix. *Gynecol Oncol.* 1989;33(3):340-3.
8. Chen J, Zhang Y, Liang B, Yang Z. The utility of diffusion-weighted MR imaging in cervical cancer. *Eur J Radiol* 2010;74:e101-6.
9. Kinkel K, Ariche M, Tardivon AA, Spatz A, Castaigne D, Lhomme C, *et al.* Differentiation between recurrent tumor and benign conditions after treatment of gynecologic pelvic carcinoma: value of dynamic contrast-enhanced subtraction MR imaging. *Radiology* 1997;204(1):55- 63.
10. McCarthy S, Hricak H. The uterus and vagina. In: Higgins CB, Hricak H, Helms CA (eds.), *Magnetic resonance imaging of the body*. 3rd edn. New York: Lippincott- Raven; 1997:761-814.