

Original research article

Immunohistochemical Study of Thyroid Neoplasms: CD56 and Galectin-3 in thyroid neoplasm

¹Dr. Taqiya Nuzhath, ²Dr. Prema Saldanha, ³Dr. Nazran Akbar Hussain, ⁴Dr. Mridula Kamath

¹Assistant Professor, Department of Pathology, Kanachur Institute of Medical Science, Mangalore, Karnataka, India

²Professor, Department of Pathology, Yenepoya Medical College, Mangalore, Karnataka, India

³Assistant Professor, Department of pathology, Kanachur institute of medical sciences, Mangalore, Karnataka, India

⁴Associate Professor, Kanachur Institute of Medical Science, Mangalore, Karnataka, India

Corresponding Author:

Dr. Mridula Kamath

Abstract

Introduction and Aim: Papillary thyroid carcinoma is the most common malignant thyroid neoplasm. The aim of this study was to evaluate the diagnostic value of CD56 and Galectin-3 immunohistochemical staining in distinguishing between papillary thyroid carcinoma (PTC), and other thyroid follicular neoplasms.

Material and Methods: A prospective study consisting of 152 thyroidectomy cases was undertaken with 45 cases of thyroid neoplasms, which were selected for Immunohistochemistry. The sections were stained with routine Haematoxylin and Eosin. The slides were reviewed and suitable blocks were subjected for immunohistochemistry, which was performed using Rabbit monoclonal primary antibody against CD56 (123C3) and Galectin-3 (9c4) from PathnSitu laboratories. Statistical analysis was done to observe frequency and percentage of each diagnosis.

Results: Out of 45 cases of thyroid neoplasms, CD56 was done on 40 cases and Galectin-3 was done on 36 cases. The Papillary thyroid carcinoma, classic and its variants showed loss in the expression of CD56 in 90% of cases. Follicular adenoma was positive in 71.4% cases and absent in 28.6% cases, whereas both Follicular carcinoma and poorly differentiated carcinoma were 100% positive for CD56. Galectin-3 was positive in all the malignant neoplasms whereas, negative in 60% and positive in 40% of benign neoplasms. The sensitivity, specificity, positive predictive value, negative predictive value and accuracy of the marker CD56 was 80%, 90%, 72.7%, 93% and 87.5%, respectively and the expression of Galectin-3 was 100%, 86.67%, 87.5%, 100% and 91.6%, respectively.

Conclusion: It was found that CD56 was more specific and slightly less sensitive as a marker of follicular differentiation. Galectin-3 was very sensitive and fairly specific marker to differentiate benign from malignant neoplasms. Hence, the use of these markers is a useful and reliable diagnostic approach for identification of thyroid neoplasms.

Keywords: CD56, galectin-3, thyroid neoplasms

Introduction

Thyroid cancer is considered to be the most common endocrine neoplasm and the incidence of thyroid neoplasm has ranked 10th among all cancers worldwide ^[1]. In the past 15-20 years, the incidence of the disease has been rising progressively throughout the world. In 2020, there were 586,202 thyroid cancer cases worldwide ^[1]. In addition, the burdens of thyroid cancer accounted for 5.1% among all cancers in women, which is due to the improved methods of detection of the disease mainly due to increased accuracy of thyroid ultrasound and application of fine-needle aspiration, followed by the cytological examination ^[1,2].

Papillary thyroid carcinoma (PTC) is the most common histological subtype, representing about 80-90% of all thyroid malignancies ^[3]. Far, histopathological studies have described a number of variants of PTC: classic, follicular, solid, encapsulated, diffuse sclerosing, tall-cell, micro papillary, etc. ^[4]. The PTC is conventionally diagnosed based on characteristic nuclear features, whereas follicular carcinoma of thyroid is diagnosed based on the presence of invasion ^[5]. The follicular variant of PTC are tumours composed of neoplastic follicles rather than papillae, but with follicular cells showing nuclear features characteristic of PTC. Two main subtypes are known to occur: infiltrative (or non-encapsulated) and encapsulated. Encapsulated FVPTC (EFVPTC) has increased in incidence and currently makes up 10% to 20% of all thyroid cancers ^[6].

Classical PTC is easy to be distinguished by cytological features on histological sections, but the distinction of FVPTC from follicular carcinoma (FC) follicular adenoma (FA) can be challenging. In

such instances, Immunohistochemistry (IHC) using CD56 and Galectin-3 helps in distinguishing PTC from other follicular neoplasms and also benign from malignant neoplasms. The distinction of the follicular neoplasms from FVPTC is not simply a matter of tumour classification but also meaningful on clinical ground. Accurate diagnosis is very critical for management of patients and prognosis ^[7].

CD56 is a member of the immunoglobulin superfamily engaged in both homophilic and heterophilic interactions. It is expressed normally in Natural Killer cells (NK cells), activated T cells, large granular lymphocytes, brain tissue and specific endocrines like thyroid gland. CD56 has been reported to be an antigen related to the differentiation of the follicular epithelium which is expressed in normal thyroid follicular cells, Hashimoto's thyroiditis, nodular colloid goitre, nodular hyperplasia, follicular adenoma and follicular carcinoma with loss of expression in PTC ^[8].

Galectin-3 (31-kd molecular weight) is one of the members of a family of non-integrin -galactoside-binding lectins that have related amino acid sequences in the carbohydrate binding site. Galectin-3 has affinity for CEA, immunoglobulin (Ig) E, laminin, and other mucins. It is expressed by human macrophages and neutrophils, mast cells, and Langerhans cells. In the thyroid, several reports have shown that galectin-3 is overexpressed in malignant tumours. Galectin-3 shows strong diffuse cytoplasmic staining in most cases of PTC, including the classical and follicular variant. Hyperplastic nodules, nodular goitres, normal follicular epithelium and follicular adenoma usually show absence of galectin-3 ^[9].

The standard procedure of diagnosing thyroid lesions is histological examination of routine H and E-stained sections. FVPTC often poses problems in distinguishing from other follicular patterned thyroid lesions when the tumour is encapsulated and the characteristic nuclear features are present focally or in multiple microscopic foci. Immunohistochemical markers, CD56 and Gal-3 have been found effective in distinguishing PTC including follicular variants from other follicular lesions in various studies. A study by Alshenawy H A *et al.* ^[10] showed CD56 and Gal-3 were the best markers to distinguish FC from FA. CD56 was the most specific in distinguishing FVPTC from FC while, to distinguish FC from FT-UMP, the best is combination of CD56 and Gal-3 ^[11].

The studies on CD56 and Galectin-3 expression in thyroid neoplasms are very few in India. Therefore, it is essential to study CD56 and Galectin-3 expressions in thyroid neoplasm for the diagnostic accuracy and they may be useful in routine reporting.

Materials and Methods

It is a prospective study undertaken in the Department of Pathology of a Tertiary Care Hospital in Mangaluru for a period of two years. A total of 152 cases of thyroidectomy done during the study period, of which forty-five cases of thyroid neoplasms were included in the study.

The study was approved by the Institution Ethics Committee. Detailed clinical history and investigations related to the case were obtained and noted. The specimens were fixed in 10% formalin, grossed according to the standard grossing protocol ^[12] and then processed by paraffin embedding. Sections of thickness 4-5µm were cut serially and stained with Haematoxylin and Eosin. The histopathological appearance and the three-point scoring criteria for the nuclear features of papillary thyroid carcinoma was used for the diagnosis of papillary thyroid carcinoma ^[11].

IHC was performed on formalin fixed, paraffin-embedded tissue. The most appropriate tumour blocks were selected and stained for IHC using primary antibody to CD56 (123C3-Mouse Monoclonal antibody, Pathinsitu) and Galectin-3 (9c4-Mouse Monoclonal antibody, Pathinsitu) following the manufacturer's instructions. The PolyExcel HRP (Non-biotin, micro-polymer based) DAB detection system was used with adequate positive and negative controls. The membrane and cytoplasm of the tumour cells showing brown colour was considered positive for CD56 and cytoplasmic or nuclear staining was considered positive for Galectin-3. Results were interpreted by 2 observers with a consensus reached regarding any discrepancy.

Grading of CD56 and Galectin-3 Expression

The CD56 and Galectin-3 stained slides were examined and the scoring was done by two independent observers. CD-56 expression in $\geq 10\%$ of cells showing membranous positivity was considered as positive and $< 10\%$ as negative. Strong and diffuse membranous expression with or without cytoplasmic staining qualified as positive for CD56 ^[12]. Galectin-3 was considered positive when nuclear and/or cytoplasmic staining was demonstrated. No staining or weak staining: Negative; Staining $< 25\%$ of the cells, weakly positive: 1+; Staining 25- 50% of the cells, midrange positive: 2+; Staining $> 30\%$ of the cells, strong positive: 3+ ^[13].

The data was entered into excel sheet and analysed using SPSS 23 software. Frequencies and percentage of all the variables were calculated. The sensitivity, specificity, positive predictive value, negative predictive value and accuracy of CD56 and Galectin-3 in thyroid neoplasms were calculated using diagnostic test calculator.

Results

A total of 152 thyroidectomy cases were studied out of which 45 cases (38 were females and 7 males) were neoplastic lesions. The mean age of the presentation of the cases was 40 years. Majority (44.5%) were in the age group 21 to 40 years. Female to male ratio was 6.4:1. Of the 45 cases, 7 (15.5%) were benign neoplasms and 38 (84.5%) malignant neoplasms. All the 7 benign neoplasms were FA (100%) and among the 38 malignant cases, 34 (89.5%) cases were PTC classic/conventional and its variants, 3 (7.9%) cases were FC and 1 (2.6%) case was poorly differentiated carcinoma (PDC).

Forty cases were selected for IHC marker CD56-123C3-Mouse monoclonal antibody. The internal positive control was considered as MNG, which was seen adjacent to the tumour. Out of the 40 cases, 7 cases were benign neoplasms and all were FA as described in Table 1. There were 33 malignant neoplasms out of which, 30 cases were PTC classic and its variants and the other 3 cases were FC (2 cases) and PDC (1 case) as describe in Table 1 and 2. Out of 30 cases, 27 (90%) cases expressed <10% of staining pattern (Fig. 1) and 3 (10%) cases expressed >10% of staining pattern. All 2 (100%) cases of FC and 1 (100%) case of PDC expressed >10% of staining pattern (Fig. 2) as shown in Table 1. Maximum cases 39 (97.5%) expressed membrane positivity and only 1 (2.5%) case expressed both membrane and cytoplasmic staining. Out of the 40 cases, weak intensity was seen in 26 (65%) cases and strong intensity was seen in 14 (35%) cases and diffuse positivity was seen in 9 (22.5%) cases and 31 (77.5%) cases showed focal positivity.

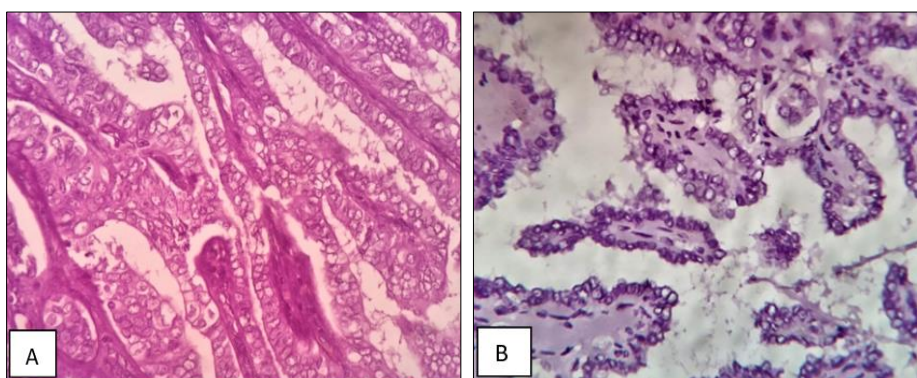


Fig 1: Photomicrograph of A- Papillary thyroid carcinoma showing papillae covered by cells having ground glass appearance (H&E 40X), B- Papillary thyroid carcinoma showing CD56 negative immunostaining (40X)

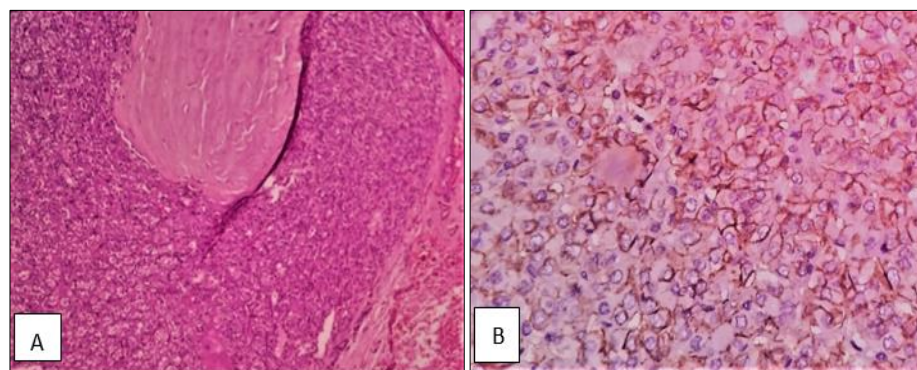


Fig 2: Photomicrograph of A- Follicular carcinoma showing capsular invasion (H&E 40X), B- Follicular carcinoma showing CD56 positive immunostaining (40X)

Table 1: CD56 expression in thyroid neoplasms

CD56	Benign		Malignant					
	FA		PTC (Classic + Variants)		FC		PDC	
	Frequency	Percentage	Frequency	Percentage	Frequency	Percentage	Frequency	Percentage
<10%	2	28.6	27	90	0	0	0	0
>10%	5	71.4	3	10	2	100	1	100
Total	7	100	30	100	2	100	1	100

Table 2: Expression of CD56 in PTC and its variants

IHC Marker	Expression	Expression
CD56	<10%	>10%
PTC classic	12	0
FVPTC	11	1
EFVPTC	1	2
Micropapillary	3	0
Total	27	3

Galectin-3 (9c4 mouse monoclonal antibody) immunohistochemistry was done on 36 cases in this study of which 26 cases of thyroid neoplasms were test and 10 cases of MNG were considered as negative controls. Out of 26 cases, 5 (19.2%) cases were benign and 21 (80.8%) cases were malignant.

Out of the 36 cases, 10 cases of MNG which was considered as negative control were all negative for Gal-3. Out of 5 cases of benign thyroid neoplasms, 3 (60%) cases were negative for Gal-3 (Fig. 3A) and 2 (40%) cases were positive for Gal-3. All 21 (100%) malignant cases expressed positive staining for Gal-3 (Fig. 3B) as given in Table 3.

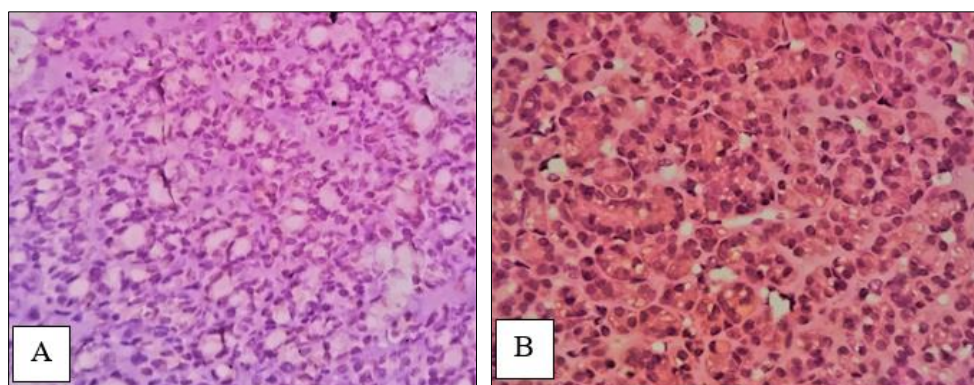


Fig 3: A- Photomicrograph of Follicular Adenoma showing negative immunostaining for Galectin-3 (40X), 3B- Photomicrograph of Follicular carcinoma showing positive immunostaining for Galectin-3 (40X)

Table 3: Expression of Galectin-3 in thyroid neoplasms

GAL-3	Benign		Malignant				Control	
	FA		PTC (Classic + Variants)		FC		MNG	
	Frequency	Percentage	Frequency	Percentage	Frequency	Percentage	Frequency	Percentage
+	2	40	19	100	2	100	0	0
-	3	60	0	0	0	0	10	100

The overall sensitivity of the marker CD56 was 80%, specificity was 90%, positive predictive value (PPV) was 72.7%, negative predictive value was 93% and accuracy was 87.5%.

The overall sensitivity, specificity, PPV, NPV and accuracy of CD56 and Galectin-3 has been described in table 4.

Table 4: Sensitivity, specificity, PPV, NPV and accuracy of IHC markers CD6 and Gal-3 in thyroid neoplasms

IHC	Sensitivity	Specificity	PPV	NPV	Accuracy
CD56	80%	90%	72.7%	93%	87.5%
GAL-3	100%	86.67%	87.5%	100%	91.6%

Discussion

In the present study, malignant neoplasms were predominant accounting for 84.5% and benign neoplasms were 15.5% which in comparison to studies done by Ijomone *et al.* [14] and Shashidhar *et al.* [15] where in the frequency of benign neoplasms was higher than malignant neoplasms.

The incidence rates of follicular adenoma (15.5%) are lesser and papillary carcinoma of thyroid is higher in this study, similar results were observed in the study done by Bharathidhasan I *et al.* [16] where follicular adenoma accounted 8.5% of benign neoplasms. There were 47.1% of PTC classic/conventional and 52.9% variants of PTC which in comparison to study done by Der EM *et al.* [17] where PTC classic/conventional was 64.7% and variants of PTC were 35.3% was low. Among the variants of PTC, FVPTC was 66.6%, EFVPTC and micro papillary carcinoma was 16.7% each, and this finding was similar to Der EM *et al.* [17] study.

In our study, all 3 malignant neoplasms (100%) cases of FC expressed >10% staining for CD56 while 26 (86.6%) cases of PTC were negative and 4 (13.4%) cases were positive for CD56 compared to studies

done by El Demellawy *et al.* [18] where 100% cases of PTC and FC were negative and positive for CD56 expression respectively. The results of various other studies are summarised in table 5. The studies done by Smriti SD *et al.* [21], Alshenawy HA [10] showed 85.7% and 86.7% positivity of CD56 in FC respectively. All the cases expressed membrane positivity and 1 case showed both membrane and cytoplasmic positivity which is similar to study done by Rasha *et al.* [23].

Table 5: Results of CD56 negative PTC with present study and various other studies

	CD 56 negative PTC
Present study	90%
El Demellary <i>et al.</i>	100%
Rahman MM <i>et al.</i>	75%
Golu <i>et al.</i>	75%
Smriti SD <i>et al.</i>	85.2%
Ceyran <i>et al.</i>	95%

Out of 40 cases, 14 cases showed strong intensity of staining while as 26 cases were showing weak intensity of staining. The diffuse positivity was seen in 9 cases and 31 cases showed focal positivity. Out of 7 cases of FA, 2 cases showed strong and diffuse staining compared to study done by Shin KM *et al.* [8] where all FA cases showed strong and diffuse positivity.

The sensitivity of CD56 was 80%, specificity was 90% while studies done by Golu *et al.* [20], Smriti DS [21] *et al.* showed 76%/ 89%, 85.16%/ 82.25%. The PPV was 72.7% and NPV was 93% in the present study which slightly varied compared to studies done by Shahbrahimi *et al.* [24], Golu *et al.* [20] which was 92.5% and 94%, 86% and 81% respectively. The accuracy of marker CD56 was 87.5% which was higher compared to study done by Zhou Y *et al.* [27] where accuracy was 53%.

Galectin-3 in 60% cases of FA was negative and in 40% cases it was positive. All the 10 MNGs were negative for Galectin-3. All the malignant cases (100%) were positive for Galectin-3 which was similar to studies done by Matesa-Anic D *et al.* and Manivannan P *et al.* [13, 29] whereas, little varied to other studies as shown in Table 6.

Table 6: Results of Galectin-3 expression with present study and similar other studies

	Benign (Gal-3 negative)	Malignant (Gal-3 positive)
Present study	60%	100%
Matesa-Anic DM <i>et al.</i>	57%	100%
Manivannan <i>et al.</i>	83.3%	100%
Park YJ <i>et al.</i>	97%	98.9%
Gaffney <i>et al.</i>	97.3%	91.6%

All 21 cases of malignant neoplasms showed cytoplasmic staining and 2 cases expressed nuclear positivity which is similar to studies done by Gaffney *et al.* and Park YJ *et al.* [25, 26]. There were 5 (100%) negative cases which were benign neoplasms and 10 negative controls. The 3 + staining was seen in 12 (40%) cases, 2+ and 1+ staining was seen in 4 (11.4%) cases each. In 3 + staining pattern, most of the cases were PTC and its variants. Both the FC cases showed 3 + staining pattern. These results are similar to previous studies where the expression of Galectin-3 was significantly higher in papillary carcinomas than in follicular carcinomas [27].

The sensitivity of the marker Galectin-3 in the present study was 100%, specificity was 86.67% which is similar to studies done by Zhou Y *et al.* [27] 95% and 75%, Sumana *et al.* [28] 86.6% and 85% respectively. The PPV of Galectin-3 in the present study was 87.5% and NPV was 100% which was also concordant with study done by Sumana *et al.* [28] (89.6% and 80.5%). The accuracy of Galectin-3 in the present study was 91.6% which was 88% in Zhou Y *et al.* [27].

Conclusion

Differential diagnosis of thyroid follicular lesions are based on histological and cytomorphological criteria. Differentiating follicular variant PTC from follicular neoplasms is sometimes difficult. CD56 plays an important role as a negative diagnostic marker for PTC in differentiating PTC from follicular carcinoma of the thyroid gland. It was found that CD56 was more specific and slightly less sensitive marker of follicular differentiation in our study.

Galectin-3 was found to be very useful not only for distinguishing the benign and malignant follicular lesions, but also in differentiating FA from FC. Galectin-3 is known to be sensitive and specific positive marker of PTC and FC. Galectin-3 was found to be very sensitive and fairly specific marker in our study. It can be concluded that CD56 and Galectin-3 used together are sensitive and specific negative and positive markers of PTC which can help in differentiating FVPTC from FC and FA from FC respectively.

Conflict of interest: None.

References

1. Shank JB, Are C, Wenos CD. Thyroid Cancer: Global Burden and Trends. *Indian J Surg. Oncol.* 2022;13(1):40-45.
2. Giusti F, Falchetti A, Franceschelli F, Marini F, Tanini A, Brandi ML, *et al.* Thyroid cancer; current molecular perspectives. *J Oncol.* 2010; 2010;1-17.
3. LiVolsi VA. Papillary thyroid carcinoma; an update. *Mod. Pathol.* 2011;24:1-9.
4. Radu TG, Ciure ME, Mogoanta SS, Busuioc CJ, Grosu F, Ţenovici M, *et al.* Papillary thyroid cancer stroma - histological and immunohistochemical study. *Rom J Morphol. Embryol.* 2016;57:801-809.
5. Devi CP, Devi KM, Venugopal M, Akarsh MP. Nuclear Features in the Diagnosis of Follicular Variant of Papillary Thyroid Carcinoma- The Diagnostic Dilemma. *Int. J Otorhinolaryngol. Head Neck Surg.* 2015;4:296-302.
6. Chem KT, Rosai J. Follicular variant of thyroid papillary carcinoma: A clinicopathologic study of six cases. *Am J Surg. Pathol.* 1977;1:123-130.
7. Fischer S, Asa SL. Application of Immunohistochemistry to Thyroid neoplasm. *Arch Pathol. Lab Med.* 2008;132:359-372.
8. Shin KM, Kim JW, Young SJ. CD56 and High Molecular Weight Cytokeratin as Diagnostic Markers of Papillary Thyroid Carcinoma. *Korean J Pathol.* 2011;45:477-484.
9. Kovacs RB, Foldes J, Winkler G. The investigation of galectin-3 in diseases of the thyroid gland. *Eur. J Endocrinol.* 2003;149:449-453.
10. Alshenawy HA. Utility of immunohistochemical markers in differential diagnosis of follicular cell-derived thyroid lesions. *Journal of Microscopy and Ultrastructure.* 2014;2:127-136.
11. Segura E, Magalhaes A. Galectin-3 immunostaining in thyroid neoplasms. *Brazilian journal of Pathology and Laboratory Medicine.* 2005;41:341-346.
12. Rosai R, Ackerman. *Surgical pathology.* 10thed. China; Mosby Elsevier. 2013;2:2630.
13. Mateša-Anić, Dubravka. Intensity and distribution of immunohistochemical expression of galectin-3 in thyroid neoplasms. *Acta clinica Croatica.* 2012;51;2:237-241.
14. Ijomone EA, Duduyemi BM, Udoye E, Nwosu SO. Histopathological review of thyroid diseases in southern Nigeria-a ten year retrospective study. *Journal of Medicine and Medical Sciences* 2014;5:127-132.
15. Shashidhar HB, Vani D, Ashwini NS, Sandhya M. Cyto-histological Correlative Study of Thyroid Neoplasms by Imprint Method. *Int J Sci Stud* 2015;3:140-144.
16. Bharathidhasan I, Goneppanavar M, Dhaka RS. Changing trends in the incidence of thyroid lesions in coastal regions of south India. *Int. J Health Sci. Res.* 2015;5:134-141.
17. Der EM, Naaeder SB, Dakubo JN, Gyasi RK. Papillary Thyroid Cancer: A Histopathological Review in Accra, Ghana *BJMMR.* 2017;20:1-9.
18. El Demellawy D, Nasr A, Alowami S. Application of CD56, P63 and CK19 immunohistochemistry in the diagnosis of papillary carcinoma of the thyroid. *Diagnostic Pathology.* 2008;3:1-12.
19. Rahman MM, Banu SG, Barua AR, Kamal M, Baqui MN, Parveen S *et al.* Follicular Variant of Papillary Thyroid Carcinoma on the Basis of Histopathological and Immunohistochemical Diagnosis. *Bangladesh Med Res Counc Bull.* 2016;42:21-7.
20. Golu I, Vlad MM, Dema A, Moleriu LC, Tudor A, Iacob M, *et al.* The absence of CD56 expression can differentiate papillary thyroid carcinoma from other thyroid lesions. *Indian J Pathol. Microbiol.* 2017;60:161-166.
21. Smriti SD, Khandeparkar SGS, Joshi AR. Study of Immunohistochemical Markers (CK-19, CD-56, Ki-67, p53) in Differentiating Benign and Malignant Solitary Thyroid Nodules with special Reference to Papillary Thyroid Carcinomas. *JCDR.* 2016;10:14-19.
22. Ceyran AB, Şenol S, Simsek BC, Sagirolu J, Aydin A. Role of CD56 and e-cadherin expression in the differential diagnosis of papillary thyroid carcinoma and suspected follicular-patterned lesions of the thyroid: the prognostic importance of e-cadherin. *Int. J Clin. Exp. Pathol.* 2015;8:3670-3680.
23. Rasha M. Abd El Atti, Lobna S. Shash. Potential diagnostic utility of CD56 and claudin-1 in papillary thyroid carcinoma and solitary follicular thyroid nodules. *J Egypt Natl Canc Inst.* 2012;24:175-84.
24. Shahebrahimi K, Madani SH, Fazaeli AR, Khazaei S, Kanani M, Keshavarz A, *et al.* Diagnostic value of CD56 and nm23 markers in papillary thyroid carcinoma. *Indian J Pathol. Microbiol.* 2013;56:2-5.
25. Gaffney RL, Carney JA, Sebo TJ, Erickson LA, Volante M, Papotti M, *et al.* Galectin-3 Expression in Hyalinizing Trabecular Tumours of the Thyroid Gland. *Am J Surg. Pathol.* 2003;27:494-498.
26. Park YJ, Kwak SH, Kim DC, Kim H, Choe G, Park DJ, *et al.* Diagnostic Value of Galectin-3, HBME-1, Cytokeratin 19, High Molecular Weight Cytokeratin, Cyclin D1 and p27kip1 in the Differential Diagnosis of Thyroid Nodules. *J Korean Med Sci.* 2007;22:621-628.

27. Zhou Y, Chen ZH, Lu B, Jiang HG. Diagnostic significance of Ki67, CK19, Galectin-3 and HBME-1 expression for papillary thyroid microcarcinoma. *Biomed Res- India*. 2017;28:4002-6.
28. Sumana BS, Shashidhar S, Shivarudrappa AS. Galectin-3 Immunohistochemical Expression in Thyroid Neoplasms. *JCDR*. 2015;9:07-11.
29. Manivannan P, Siddaraju N, Jatiya L. Role of pro-angiogenic marker Galectin-3 in follicular neoplasms of thyroid. *Indian J Biochem Biophys*. 2012;49:392-394.