

Original research article

**A STUDY OF MORPHOMETRY OF LATERAL
COLLATERAL LIGAMENTS OF ANKLE JOINT**

Dr. Narendra Patil

Assistant Professor, Department of Anatomy, Dr Patnam Mahendra Reddy Institute of
Medical Sciences, Chevella, Telangana, India

Corresponding Author:

Dr. Narendra Patil

Abstract

The talocrural joint is one of the most prominent joints that has undergone remarkable progress in evolution. These joints are responsible for bearing the full weight of the body, which is why they had to develop on such a massive scale in order to accommodate this weight. The purpose of this study is to make a genuine effort to comprehend the anatomical and morphological aspects of the ligaments and the articular surfaces of the ligaments.

Keywords: Morphometry, ligaments, ankle, joint

Introduction

Without a doubt, bipedalism is a characteristic that emerged quite early on in the history of humanity^[1-4]. Approximately four million years ago, a tibia that has been linked to *Australopithecus anamensis* was discovered, which provides evidence that this species was a biped 10. With the modification of the foot such that it functions as a stable support rather than a grasping limb, it has been possible to achieve an effective bipedal adaption. It has been determined that the shape and function of the ankle in a number of different species have been investigated, and this information has been utilised in order to derive some conclusions on the manner in which early hominins moved. The pertinent bones (tibia and talus) in great apes, humans, and extinct hominins ranging from *Australopithecus anamensis* to *Homo erectus* were researched, and it was discovered that the ankle morphology in humans was different from that of the other hominins. Based on the current human ankle, it appears that they were more suited for walking upright than for climbing trees. Every modern human being is the sole known example of an obligatory biped, which means that their body weight is transferred to the ground through their lower limbs. When they are standing erect, each of them shares fifty percent of their body weight. Bipedal walking is a challenge in terms of maintaining the body's equilibrium and providing support to the lower limbs, particularly when one of the limbs is elevated above the ground. Regarding this matter, the talocrural joint plays an important role that cannot be overlooked. The joint in the ankle is one of the joints that sustains injuries the most frequently. When the foot is in the plantar flexed posture, the ankle injuries are most likely to occur. A greater number of injuries occur to the lateral ligament in comparison to the medial ligament. The tear of the front talofibular and calcaneofibular ligaments that occurs when the foot is twisted in a lateral orientation is the cause of a sprained ankle^[5-8]. In the event that the foot is forced to be turned inward, the deltoid ligament may be ruptured. In certain instances, the deltoid ligament exerts a pulling force on the medial malleolus, which results in an avulsion fracture of the malleolus. Potts fracture is a type of foot fracture that happens when the foot is everted against its will and becomes trapped in a rabbit

hole in the ground [9-13]. At the beginning of this condition, there is a fracture of the shaft and the lateral malleolus of the fibula that is lateral in orientation. Because of the intense eversion pull that is placed on the deltoid ligament, the medial malleolus fractures in a transverse direction. The posterior border of the distal end of the tibia is also shattered by the talus, which results in a trimalleolar fracture. This occurs when the tibia is carried anteriorly. This study tries to find the morphometry of ligaments of ankle joint.

Aims and Objectives

To study the morphometry of ligaments of ankle joint.

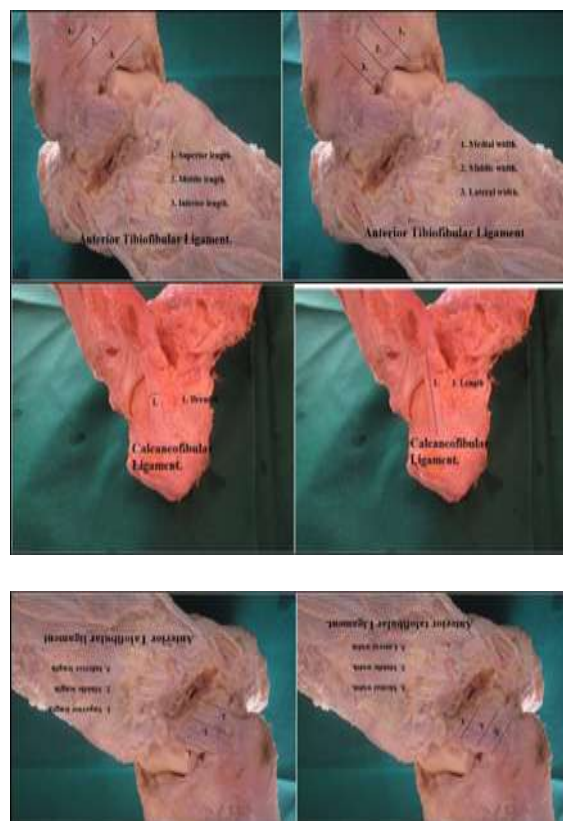
Materials and Methods

Dissections were performed on thirty human ankles that had been fixed with formalin and were accessible in the department of anatomy. The specimens consisted of eleven females and nineteen males. There was a distinction made between male and female ankles, as well as between right and left ankles. The anterior median plane and the posterior median plane were both used to make an incision, which extended from the caudal one third of the leg to the proximal one third of the foot. A reflection of the skin was observed all around the talocrural joint, all the way up to the point where the dorsal surface and the plantar surface met. Dissection was performed on all of the soft tissues, including the muscles, and the results were written down on the anterior, posterior, medial, and lateral surfaces. There is a close connection between the underlying ligaments of the talocrural joint and the soft tissue tunnel that completely encircles the tendons of the muscles. Then the morphometry of the ligaments were taken using a vernier calipers.

Results

Table 1: Morphometry of lateral collateral ligaments

		Mean
Anterior Talofibular	SUPERIOR	17.8
	MIDDLE	16.8
	INFERIOR	16.2
	MEDIAL	14.2
	MIDDLE	13.3
	LATERAL	13.6
	THICKNESS	3.04
Posterior talofibular	LENGTH	22.5
	WIDTH	8.29
	THICKNESS	4.96
Calcane ofibular	LENGTH	25.7
	WIDTH	7.83
	THICKNESS	4.99

Images of the dissection:**Discussion**

The anterior talofibular ligament is a quadrilateral ligament that is relatively strong. It is characterised by its flat shape. It is composed of two bands that are connected by a few vascular branches. The inferior oblique segment, which is located on the anterior border of the lateral malleolus, is the spot where the ligament first originated. The insertion of this structure occurs on the talar body, just anterior to the lateral malleolar articular surface, and it runs in an anterior-centered direction.

The posterior talofibular ligament is a ligament that is quite strong and is located in a location that is very close to horizontal positioning. It is the lower portion of the digital fossa that serves as the origin of the ligament, which is located on the medial surface of the lateral malleolus. It is placed on the lateral surface of the talus in a groove that runs along the posteroinferior border of the lateral malleolus all the way up to its mid segment and also to the posterior surface of the talus. It travels in a horizontal direction. The calcaneofibular ligament is a robust ligament that often takes the form of a cord or a flat oval. The lower segment adjacent to the anterior edge of the lateral malleolus is the point of genesis for this structure. After the foot has been brought into a neutral posture, it will run posteriorly, inferiorly, and medially. A tiny tubercle that is situated on the posterior portion of the lateral calcaneal surface is where it is implanted before being inserted. An ankle sprain is one of the most common lower limb injuries. It involves damage to at least one of the ligaments located around the outer side of the ankle (lateral side).

Lateral ankle sprains cause pain, swelling and limited mobility. Without treatment, recurrent sprains can occur, causing chronic instability problems within the ankle.

Sprains are graded based on their severity, ranging from a strain (mild), to a partial tear (moderate), to a complete tear (severe). When there is a complete tear, it can sometimes cause damage to the bone too-known as an avulsion fracture.

Ankle sprains are common musculoskeletal injuries that can progress to chronic lateral ligament instability, a condition characterized by recurrent inversion ankle sprains,

lateral ankle pain, and symptomatic instability. Lateral ligament instability is debilitating and can lead to even more severe disease in the form of post-traumatic arthritis. Appropriate diagnosis and management of this condition requires an understanding of the ligamentous complex that provides stability to the lateral ankle and how each structure can fail. In addition, the clinician must be able to perform a focused physical examination and use appropriate imaging to reach a diagnosis prior to initiating treatment.

Conclusion

This study hopes to fill in the gap of statistics in local population. This also forms a base for future studies.

References

1. Bernard Mengiardi, Christian WA, Firrmann P, Patrick Vienne, Juerg Hodler, Marco Zanetti. Medial Collateral Ligament Complex of the Ankle: MR Appearance in Asymptomatic Subjects. Radiological Society of North America, 2007, 242(3).
2. Boss AP, Hintermann B. Anatomical study of the medial ankle ligament complex. Foot Ankle Int. 2002;23:547-53.
3. John J Hermans, Annechien Beumer, Ton AW De Jong, Gert-Jan Kleinrensink. Anatomy of the distal tibiofibular syndesmosis in adults. J Anat. 2010;217:633-645.
4. Patil MS, Raza SMG, Md. Nayeem Ali. Anthropometric measurements of ankle mortise for evaluating mortise fracture reductions with an aim to develop contoured implants. Al Ameen J Med Sci. 2012;5(4):381-387.
5. Chen Yan-xi, Lu Xiao-ling, Bi Gang, Yu Xiao, Hao Yi-li, Zhang Kun, *et al.* Three-dimensional morphological characteristics measurement of ankle joint based on computed tomography image post-processing. Chin Med J. 2011;124(23):3912-3918.
6. Pau Golanò, Pier Paolo Mariani, Marc Rodríguez-Niedenfuhr, Pier Francesco Mariani, Domingo Ruano-Gil. Arthroscopy. Arthroscopic anatomy of the posterior ankle ligaments. Arthroscopy. 2002;18(4):353-8.
7. Chien-Chung Kuo, Guan-Ying Lee, Chia-Min Chang, Horng-Chaung Hsu, Alberto Leardini, Tung-Wu Lu. Ankle morphometry in the Chinese population. Journal of Foot and Ankle Research. 2008;1:O11. Doi:10.1186/1757-1146-1-S1-O11.
8. Gunther Windisch, Boris Odehnal, Reinhold Reimann, Friedrich Anderhuber, Hellmuth Stachel. Contact Areas of the Tibiotalar Joint. In Wiley Inter Science, 2007. DOI 10.1002/jor.20429.
9. McLean SG, Walker KB, Van den Bogert AJ. Effect of gender on lower extremity kinematics during rapid direction changes: an integrated analysis of three sports movements. J Sci. Med Sport. 2005;8(4):411-422.
10. Taser F, Shafiq Q, Ebraheim NA. Anatomy of lateral ankle ligaments and their relationship to bony landmarks. Surg Radiol Anat. 2006;28(4):391-7.
11. Milner CE, Soames RW. Anatomy of the collateral ligaments of the human ankle joint. Foot Ankle Int. 1998;19(11):757-60.
12. Earll M, Wayne J, Brodrick C, Vokshoor A, Adelaar R. Foot Ankle Int. Contribution of the deltoid ligament to ankle joint contact characteristics: a cadaver study Foot Ankle Int. 1996;17(6):317-24.
13. Federico Corazza, Rita Stagni, Vincenzo Parenti Castelli, Alberto Leardini. Articular contact at the tibiotalar joint in passive flexion. J Biomech. 2005;38(6):1205-12.