

Original Research Article

Evaluation of Outcome of Acute Acromio- Clavicular Joint Dislocation Fixed Suspensory Device

Dr. Nagesh Gowda L.V.¹, Dr. Praveen Kumar N.²

¹Senior Resident, Department of Orthopaedic, Mysore Medical College & Research Institute, Mysore, Karnataka, India.

²Third Year Junior Resident, Department of Orthopaedics, Mysore Medical College & Research Institute, Mysore, Karnataka, India.

Corresponding Author

Dr. Nagesh Gowda L.V., Senior Resident, Department of Orthopaedic, Mysore Medical College & Research Institute, Mysore, Karnataka, India.

Received: 18-11-2023 / Revised: 28-11-2023 / Accepted: 21-01-2024

ABSTRACT

Background

To assess the functional outcome of Acute Acromio-clavicular joint dislocation fixed with endo-button

Methods

about eight patients were included in our study who had sustained Acromio Clavicular joint dislocation, patients were included on the basis of specific inclusion criteria, routine investigations and xray of chest with bilateral shoulder was done they were operated by open redcution and internal fixation using endo-button by open or mini open procedure.

Results

functional outcome was assessed by Constant murley score and ACJIS score about 92 and 90 percent of patients had good to excellent outcome according to the scoring system respectively and were doing well on day to day basis

Conclusion

treatment of Acute Acromio -Clavicular joint dislocation fixing with endobutton is a very good modality of treatment and can be done in routine health care setups regularly and easily.

Keywords: ACROMIO CLAVICULAR JOINT, endo button , open reduction.

INTRODUCTION

Acromio clavicular Joint dislocation is a typical injury which affects active young adults. Such injuries are classified from type 1-6 on basis of radiographic finding using Rockwood criteria. Non operative treatment in Rockwood type 1 and 2, whereas operative treatment for type 3-6 lesion is due to their instability [1,2]. Surgical methods employed for treatment of Acromio clavicular joint dislocation through extra articular fixation are restoring coraco-clavicular ligament with metallic cables, autologous ligament or by Ligament Advanced Reinforcement System [LARS] artificial

ligament [3]. Trans articular fixation is by using hook plate, k wire and threaded pins. However severe concern still exists regarding pin migration, breakage, pin site infection/failure and recurrent instability after pin removal [4,5,6].

Current trend at reconstruction of coracoclavicular ligament is by using Allograft or suspensory devices. Autologous graft's are avoided due to donor side morbidity and complications. In our study we are using the alternative methods for fixing Acromio Clavicular Joint with synthetic suspensory devices (Endo button), which are available in the market like Dog bone button, Endo button. In our study we are evaluating the outcome of acute acromino-clavicular joint dislocation fixed with suspensory loop devices using endobutton, clinically and functionally using Acromino clavicular joint instability score (ACJIS) and Pain Visual Analog Score (VAS)[1,2,7] .

MATERIAL AND METHODS

The study will be conducted on series of 6 cases of Acute Acromino clavicular joint dislocation fixing with suspensory devices. This study is being conducted over a period from August 2023 to October 2023.

Inclusion criteria

- Patient of age group ≥ 18 years of both sex.
- Patient Diagnosed with Acute Acromio-Clavicular Joint dislocation type 3-6 of Rockwood criteria.

Exclusion criteria

- Patient with frozen shoulder.
- Patient with Acromio clavicular joint dislocation associated with fracture around the shoulder joint
- Patient with associated nerve injuries
- Excluding type 1 and 2 Acute Acromio-Clavicular joint dislocation based on Rockwood criteria
- Patient with < 18 years of age.

Surgical approach

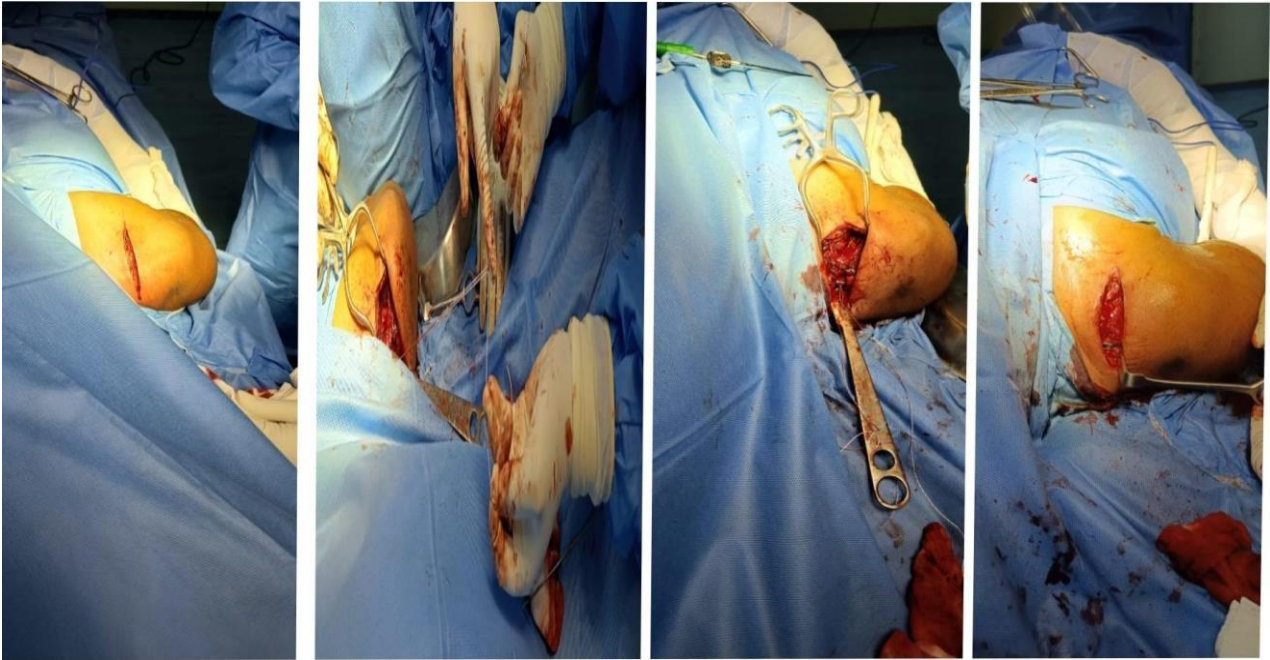
The patient is placed in beach chair position as per reference [2,4], C-Arm position should be in 15° tilt and 15° Oblique.

Open or mini open procedure using skin strap incision (longitudinal incision exposing both clavicle and corocoid process or horizontal incision over clavicle). Superficial dissection done, anterior deltoid fibres split along line of incision, clavicle and corocoid process drilled using 4 mm cannulated drill bit ,beath pin used to pass endobutton, Fixation done by using endobutton and fibre wire while maintaining reduction under C-Arm guidance

Post operative rehabilitation

Passive assisted range of motion will be started from post operative day-3 as per pain tolerance. Progressive rehabilitation will be initiated after 2 weeks. All patients is allowed to use their arm for daily activities, non-restricted movements from 6th Post operative week.

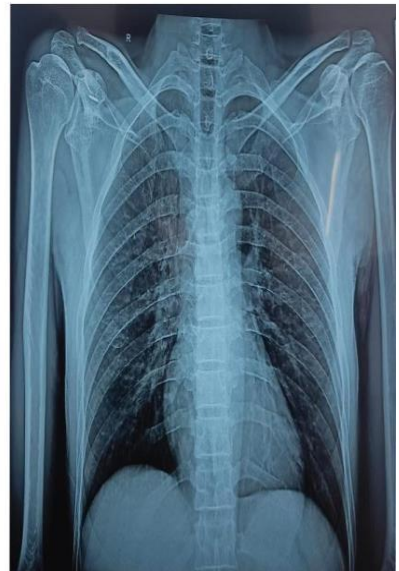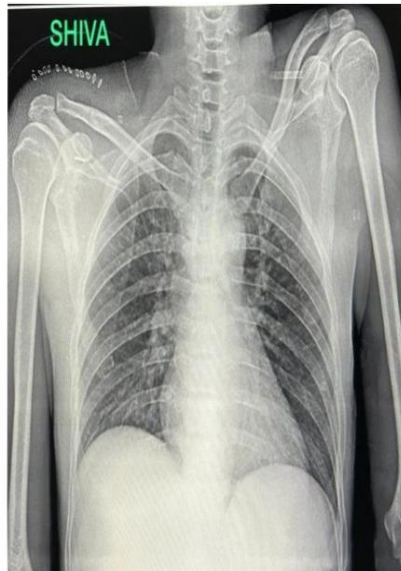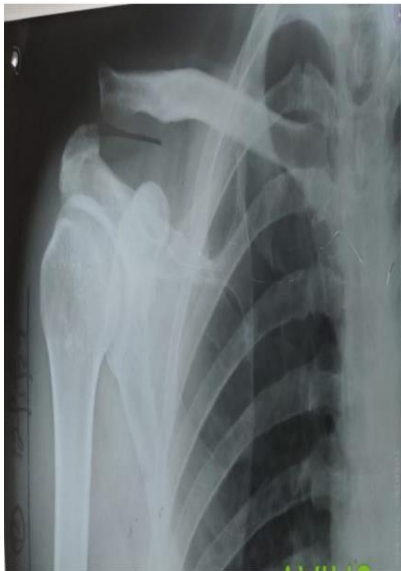Lifting weight is allowed from 3rd month post operatively.



PRE OP

POST OP

12 WEEKS



RESULTS

Patients in our study were between 20-50 year age group were male dominated and mode of injury was high velocity trauma and few patients with low velocity trauma.

In our study 3 patients suffered dislocation on left side and 5 patients suffered dislocation on right side.

All the patients were immobilized with shoulder immobilizer for 2 weeks with progressive rehabilitation.

Mean operating time was 60 minutes. Mean blood loss was 30-45 ml. Mean length of incision was 3-5cm. Average hospital stay was 6 days.

Table 1: Age distribution

Age	Number	Percentage
20-30	3	37.5
30-40	4	50
40-50	1	12.5

Majority of patients were belongs to the age Group 30 -40 (50%), followed by 20-30 (37.5%) Followed and 40-50 (12.5%).

Table 2: Distribution of side of injury

Side	Number	Percentage
Right	5	62.5
Left	3	37.5

Majority of side of injury were found right side(62.5)

Table 3: Sex distribution

Sex	Number	Percentage
Male	6	75
Female	2	25

Male patients (75%) were dominant in The study

Table 4 : Type of dislocation

Type	Number	Percentage
3	2	25
4	2	25
5	4	50
6	0	0

DISCUSSION

The most important finding of this study is that acute AC joint separations (types III-V) can be restored and maintained using a relatively simple, reproducible, and durable surgical technique with a low cost. This study aimed to evaluate the clinical and radiological outcomes.

In a countrywide anonymous survey of 210 German Trauma departments, B athis et al[8] asked about diagnostic procedures and treatment strategies for AC injuries. One hundred four questionnaires (49%) were returned and evaluated. For type I and II injuries, most clinics recommended nonoperative treatment, whereas for more severe AC injuries (Rockwood IV to VI), all clinics recommended operative intervention. On the other hand, 84% of the clinics would operate on type III AC injury-especially in athletes or overhead workers. Although 38% of the clinics believed that nonoperative treatment is equal to or better than operative treatment only.

Surgical methods employed for treatment of Acromio-clavicular joint dislocation through extra-articular fixation are restoring coraco-clavicular ligament with metallic cables, autologous ligament or by ligament advanced reinforcement system[LARS] artificial ligament. Trans articular fixation is by using hook plate, k-wire, and threaded pins.

However severe concern still exists regarding pin migration, breakage, pin site infection /failure and recurrent instability after pin removal.

Current trend at reconstruction of coracoclavicular ligament is by using allograft or suspensory devices.

Allograft are avoided for donor site morbidity and complications, therefore we are using alternate method of fixing with synthetic suspensory devices.

Gowd et al. [9] analysed the clinical outcomes and complications of several surgical techniques for ACJ reconstruction, including suture-only fixation, and found an overall failure rate of 20.8% and an overall pooled complication rate of 14.2%, with complications such as infection (6.3%), fracture of the coracoid or distal clavicle (5.7%), and hardware/button failure (4.2%). There were no differences in the loss of reduction, complication rate, or revision rate between open and arthroscopic AC joint reconstruction techniques.

In this study sample of 8 patients with adequate follow-up, the clinical and radiological outcomes were reasonable and at least equal to what other similar studies have shown. The main indications are type IV and V acromioclavicular dislocations and selected patients with type III injuries, especially those performing strenuous overhead or heavy labour activities.

CONCLUSION

Functional Outcome of acute acromio-clavicular joint dislocation fixed with suspensory devices(endo-button) is found to be good and have following benefits

- Less blood loss and shorter operative time, Early mobilization.
- Very minimal post operative stiffness and arthritis of Acromio clavicular joint
- Good acromio clavicular joint stability
- Minimal discomfort compared to other methods.

REFERENCES

1. Aliberti GM, Kraeutler MJ, Trojan JD, Mulcahey MK (2020) Horizontal Instability of the acromioclavicular joint: a systematic review. Am J Sports Med 48:504–510
2. Gowd AK, Liu JN, Cabarcas BC et al (2019) Current concepts in the operative management of acromioclavicular dislocations: a systematic review and metaanalysis of operative techniques.

3. Med, Nicandri GT, Young DC, Owen JR, Wayne JS. A cadaveric study examining acromioclavicular joint congruity after different methods of coracoclavicular loop repair. *J Shoulder Elbow Surg.*
4. Breuer R, Unterrainer A, Komjati M, Tiefenboeck TM, Trieb K, Pirkl C (2019) Minimally invasive ac joint reconstruction system (minar®) in modified triple-button technique for the treatment of acute ac joint dislocation. *J Clin Med* 8:E1683.
5. Bannister GC, Wallace WA, Stableforth PG, Hutson MA. The management of acute acromioclavicular, dislocation: a randomised prospective controlled trial. *J Bone Joint Surg Br.* 1989;71:848-850
6. Bosworth BM. Acromioclavicular separation new method of repair *Surg Gynecol Obstet.* 1941;73:866-871.
7. Minkus M, Hann C, Scheibel M, Kraus N (2017) Quantification Of dynamic posterior translation in modified bilateral Alexander Views and correlation with clinical and radiological parameters. In patients with acute acromioclavicular joint instability. *Arch Orthop Trauma Surg.*
8. Bähris H, Tingart M, Bouillon B, Tiling T. Current therapeutic strategies for acromioclavicular injuries: results of a survey at German Trauma Departments. *Unfallchirurg.* 2001;104:955-960.
9. Gowd AK, Liu JN, Cabarcas BC et al (2019) Current concepts in the operative management of acromioclavicular dislocations: a systematic review and meta-analysis of operative techniques. *AmJ Sports Med* 47:2745-2758. <https://doi.org/10.1177/0363546518795147>.