

**CASE REPORT**

**Erythroplakia: A Case Report**

**Ravi Kumar Seth<sup>1</sup>, Sherin N<sup>2</sup>, Sunita Pathak<sup>1</sup>**

<sup>1</sup> Rama Dental College Hospital & Research Centre, Rama University, Mandhana, Kanpur,  
Uttar Pradesh- India 209217

<sup>2</sup> Government Dental College Dibrugarh.

**ABSTRACT:**

Malignancies are preceded by potentially malignant disorders. Erythroplakia is one of the precursors of oral squamous cell carcinoma. Erythroplakia is one of the type of premalignant disorder that have potential to convert into carcinoma most frequently. Erythroplakia poses a major diagnostic and therapeutic challenge. We present a case of Erythroplakia in right side of buccal mucosa which is converted into carcinoma in situ along with review in light of current information from the literature. We also attempt to present the clinical relevance, and the therapeutic modalities available for the management of the disease.

**Key Words:** Malignancies, potentially malignant disorders, Leukoplakia, Erythroplakia, Carcinoma.

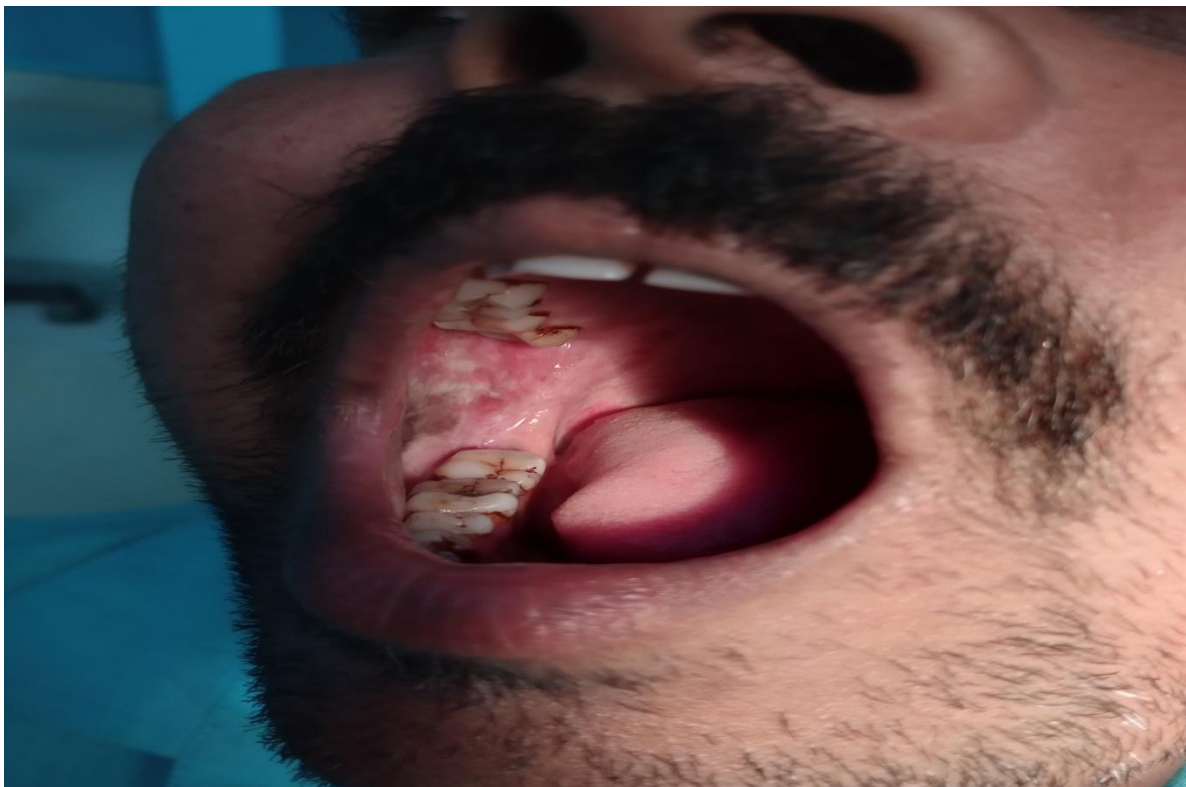**INTRODUCTION**

Public awareness of lesions that can potentially be a malignancy in oral cavity has been increasing. One lesion that can be found in the oral cavity is Erythroplakia. Leukoplakia is derived from the word “leuko” which means white, and “plakia” which refers to the word plaques or patches. Thus, leukoplakia can be defined as a white plaque that cannot be scraped off. Its etiology, however, is still questionable after eliminating all risk factors that do not have a tendency toward malignancy<sup>1</sup>. Approximately, 3% of the worldwide population has suffered from leukoplakia, 5-25% of which are pre-malignant lesions. After verified through histopathological examination, all lesions of leukoplakia can be considered as a potentially malignant lesion.<sup>2</sup> The World Health Organization (WHO) currently employs the term Speckled Leukoplakia (SL) to describe the presence of both white and red patches on the oral mucosa.<sup>3</sup> SL is a rare, highly aggressive, clinicopathological entity, with high-risk of malignant transformation and a precursor lesion of squamous cell carcinoma.<sup>4</sup> In India very few cases of speckled leukoplakia have been reported in this case report we have discussed a case of speckled leukoplakia in right side of buccal mucosa extending up to the alveolar region.

**CASE REPORT:**

A 58 year old male patient reported to the outpatient department of Rama Dental College, Kanpur with a red and white patch on right side of buccal mucosa. The patch was first noticed 1year ago which showed gradual enlargement causing discomfort and burning sensation. He had been smoking since the age of approximately 29 years, but he has stopped the habit since 5 years ago. He also had a habit of chewing unprocessed tobacco since 10

years with a frequency of 2 to 3 times per day. Along with these the patient also consumed alcohol occasionally. Intraoral Examination of right buccal mucosa revealed firm, non tender, non scrapable, red and white patches measuring 2 x 2 cm. Surface appears rough and slightly elevated which clinically resembled speckled Erythroplakia in appearance. The lesion was intermixed with red patchy areas. Chair side investigation, toluidine blue staining was carried out to select the area of biopsy to be made. The selected area was then biopsied (incision). Histopathologic examination with H and E stained sections showed squamous epithelium overlying connective tissue stroma. The epithelium shows Dysplastic features such as broad rete ridges, acanthosis, hyperchromatism, basilar hyperplasia, cellular and nuclear pleomorphism, and abnormal mitosis, Individual cell keratinization and intraepithelial keratin pearls formation. The dysplastic epithelial changes has extended top to bottom. Connective tissue stroma is highly cellular with dense infiltration of chronic inflammatory cells, dilated and proliferated capillaries. The overall clinical and histopathological findings were considered diagnostic for speckled leukoplakia transforming into carcinoma in situ.



**Figure 1: Showing speckled leukoplakia in right side of buccal mucosa.**

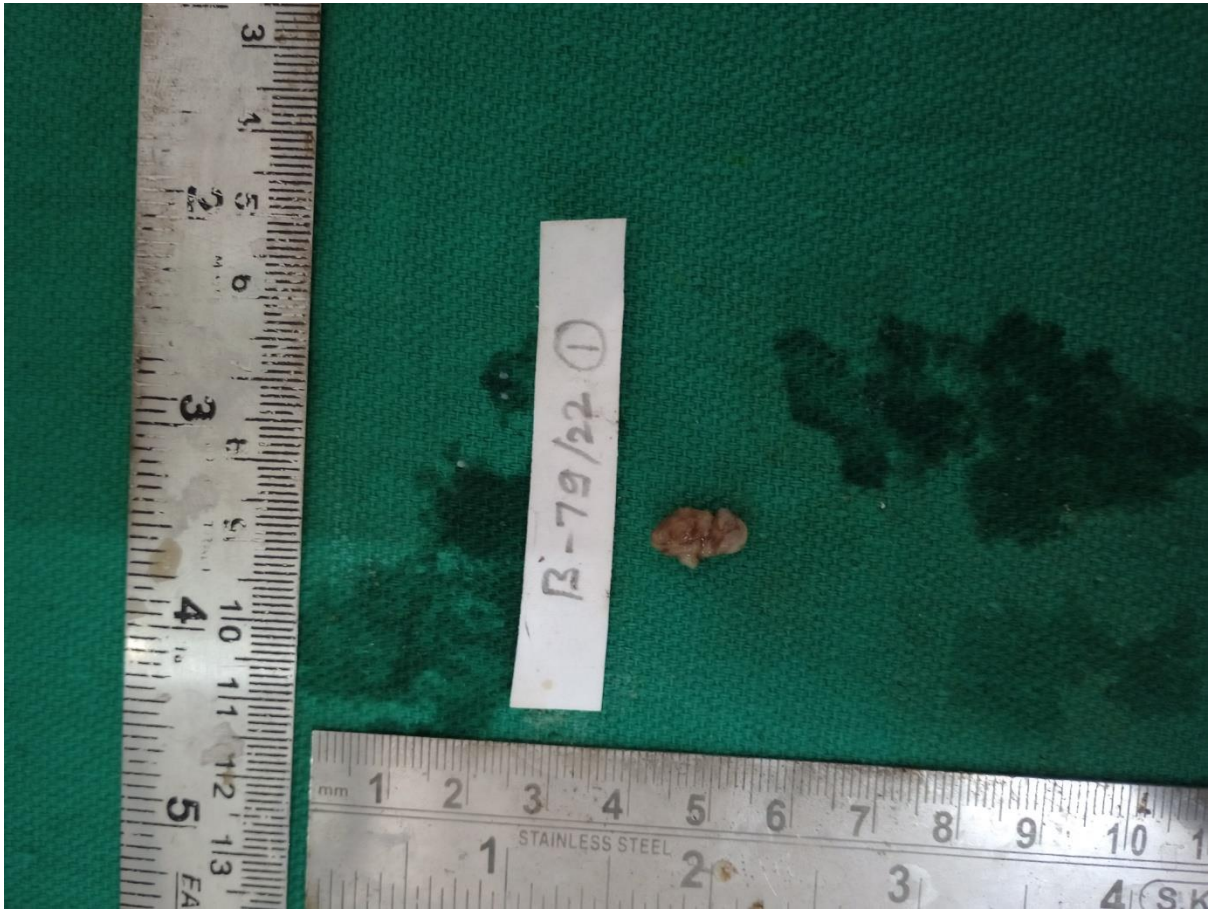

Figure 2: Grossing image showing tissue of incisional biopsy.

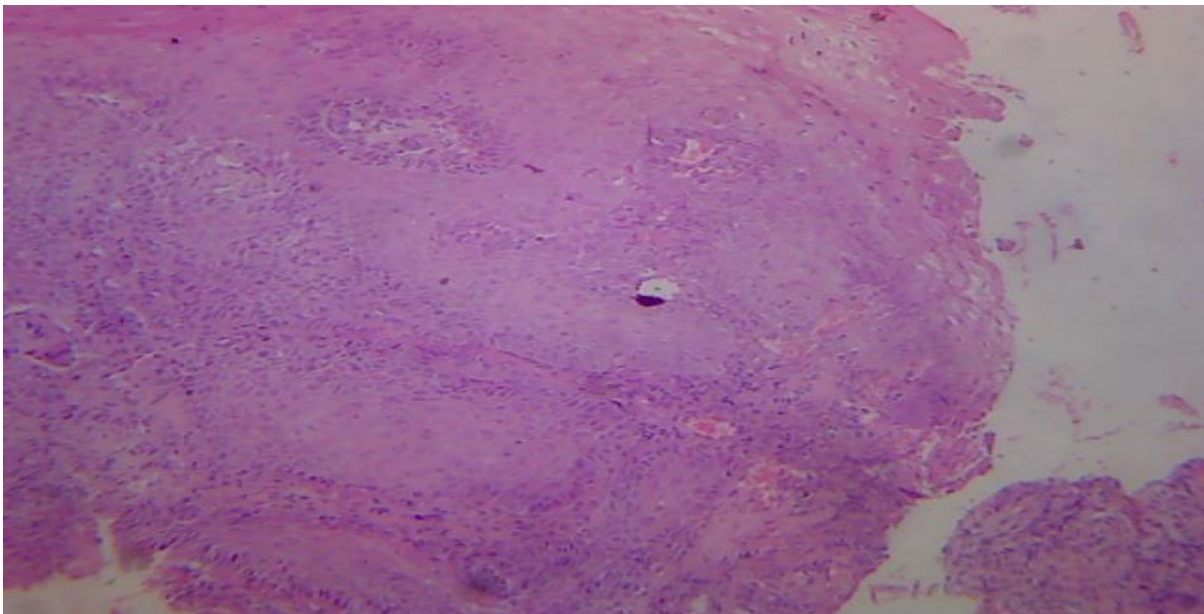


Figure 3: Histopathology showing Erythroplakia [H & E X10]

**DISCUSSION:**

WHO defines leukoplakia as a whitish patch or plaque that cannot be characterized, clinically or pathologically, as any other disease and which is not associated with any other physical or chemical causative agent except the use of tobacco.<sup>5</sup> The literature, however, strongly indicates the role of alcohol, viruses and systemic conditions. The World Health Organization (WHO) employs the term Speckled Leukoplakia (SL) to describe the presence of both white and red patches on the oral mucosa.<sup>6</sup> The two main clinical types of leukoplakia are homogeneous and non homogeneous leukoplakia. Speckled leukoplakia falls under the category of non-homogenous leukoplakia.

Etiological factors involved are alcohol use and smoking, diets lacking antioxidants (such as vitamins C, E, and beta-carotenes), occupational exposure to carcinogens, viral infections, and genetic and hereditary factors. Smoking of tobacco was found to be the strongest independent risk factor. Other forms of tobacco, hyperacidity, lipstick, and ill-fitting dentures were found to be a causative factor, which shows that socioeconomic status and lifestyle are involved in causing premalignant lesions.<sup>7</sup> Various designations have been used to describe the presence of both white and red patches. Lesions appearing completely red are named as Erythroplakia. SL is indicated when red and white patches are present over the mucosa.<sup>4</sup>

Speckled leukoplakia carries a higher risk of developing into malignancy than the other types. So early diagnosis by biopsy has to be done to avoid the dangerous malignant transformation.<sup>8</sup> Approximately 80 percent of SL progress to oral carcinoma over a period of time in spite of a variety of interventions. This feature contrasts with homogenous leukoplakia in which approximately 5-10 percent will transform into a carcinoma.<sup>4</sup> SL is resistant to most of the available treatment modalities, including surgery [4]. Therefore, total excision with free surgical margins is critical combined with a lifelong follow-up.<sup>3</sup> Malignant potential of leukoplakia is higher in women (6%) than in men (3.9%). Leukoplakia associated with habit of chewing tobacco shows higher rate of malignant transformation as compared to others.<sup>7</sup> In buccal mucosa and commissure region 1.8 percent malignant transformation can occur. In lip and tongue region 16 to 38.8 percent malignant transformation has been reported. The annual malignant transformation rate has been determined to be 0.1% to 17%.<sup>9</sup>

**MANAGEMENT:**

The degree of epithelial dysplasia plays a pivotal role while deciding the nature of treatment to the patient. Martorell- Calatayud.<sup>10</sup> defined two risk groups and the subsequent treatment options:

Group 1: Those with low risk of malignisation:

Those leukoplakias lacking dysplasia, and those that show mild dysplasia located in low risk areas or those with a thickness of less than 200 mm or that present clinically as homogenous leukoplakia. A range of therapeutic approaches can be taken in this group:

Regular patient follow-up. The interval between follow-up visits should not exceed 12 months in order to detect any change, suggestive of malignant transformation.

Treatment of lesions with topical or oral retinoids {eg: 13-Cis-Retinoic Acid (1.5 to 2 mg/kg body weight for 3 months)}<sup>10</sup>

Treatments using nonsurgical ablative techniques, such as cryotherapy and carbon dioxide laser ablation. Of these options, the use of laser light has shown better results in terms of controlling the lesions, and so it is considered the treatment of choice in this low risk group.

Group 2: Those with high-risk of malignant transformation, which comprises:

Those leukoplakias with mild dysplasia located in high-risk areas measuring more than 200 mm, or those associated with a nonhomogenous clinical form; Leukoplakias with moderate or severe dysplasia;

Verrucous leukoplakias. In this group, aggressive surgical treatment, consisting of excision of the entire thickness of the mucosa at the site of the leukoplakia is recommended. This is similar to the present case.

Among the many therapeutic options available, however, eliminating risk factors (smoking, alcohol) and etiological factors (sharp broken teeth, faulty metal restorations and metal bridges) are preventive measure applicable to all patients with these lesions.<sup>8</sup>

Regular check-up of these patients is essential, probably every 3, 6 and then 12 months, both in treated and untreated patients.

## CONCLUSION:

Erythroplakia is a potentially malignant disorder. Patient suffering from any potentially malignant disorder should be treated aggressively.

Since malignant transformation rate of Erythroplakia is very high early diagnosis plays a very important role in treatment as well as prognosis of Erythroplakia.

## REFERENCES:

1. Kardam P, Rehani S, Mehendiratta M, Sahay K, Mathias Y, Sharma R. Journey of leukoplakia so far - an insight on shortcomings of definitions and classifications. *J Dent Oral Disord Ther.* 2015; 3(2):1-6.
2. Lingen MW. Head and neck. In: Kumar V, Abbas AK, Aster, JC. editors. *Robbins and cotran-pathologic basis of disease.* 9th ed. Philadelphia: Elsevier; 2015. p. 731.
3. Barnes L, Eveson JW, Reichart P, Sidransky D (Eds): *World Health Organization Classification of Tumours. Pathology and Genetics of Head and Neck Tumours.* IARC Press. Lyon 2005.
4. Scully C. Oral Leukoplakia. [eMedicine web site]. October 2008. Accessed October 30, 2009.
5. Pindborg J.J., Reichart P., Smith C.J. and Van der Waal I. *World Health Organization: histological typing of cancer and precancer of the oral mucosa.* Berlin: Springer-Verlag; 1997.
6. Eversole LR. Dysplasia of the Upper Aerodigestive Tract Squamous Epithelium. *Head and Neck Pathol.* 2009; 3:63–8.
7. Reibel J. Prognosis of oral premalignant lesions: significance of clinical, histopathological, and molecular biological characteristics. *Critical Reviews in Oral Biology and Medicine* 2003; 14(1):47–62.
8. Scuba J.J. Oral leukoplakia. *Critical Rev Oral Biol Med* 1995;(2):147-160.
9. Lodi G. and Porter S. Management of potentially malignant disorders: evidence and critique. *Journal of Oral Pathology and Medicine* 2008; 37(2), 63–69.
10. Martorell-Calatayud, a R. Botella- Estrada, a J.V. Bagán-Sebastián, b O. Sanmartín-Jiménez, a and Guillén- Barona C. Oral Leukoplakia: Clinical, Histopathologic, and Molecular Features and Therapeutic Approach. *Acta Dermosifiliogr.* 2009; 100:669-84.
11. Scuba J.J. Oral leukoplakia. *Critical Rev Oral Biol Med* 1995;(2):147-160.