

UTERINE CARCINOSARCOMA: A RARE CASE STUDY

Daneshwari Kottalamath¹, Nilesh Solanke²

¹Junior Resident, Department Obstetric and Gynaecology, Government Medical College Miraj, India.

²Junior Resident, Department Obstetric and Gynaecology, Government Medical College Miraj, India.

Received Date: 21/04/2024

Acceptance Date: 22/05/2024

Corresponding Author: Dr Nilesh Solanke, Department Obstetric and Gynaecology, Government Medical College Miraj, India.

Email: balutkar@yahoo.com

Abstract

Background: Uterine carcinosarcoma (UCS) represents a rare and aggressive form of uterine cancer, traditionally classified within sarcomas but now recognized due to its monoclonal origins as a de-differentiated carcinoma. This case study focuses on a rare presentation of UCS, emphasizing the importance of comprehensive diagnostic and therapeutic strategies.

Case Presentation: We describe the case of a 59-year-old post-menopausal woman who presented with foul-smelling vaginal discharge, bleeding, fever, and significant weight loss. Physical examination revealed a large abdominal mass, suggestive of advanced uterine cancer. Imaging and surgical findings supported a diagnosis of UCS. The patient underwent a successful staging laparotomy, including hysterectomy and omentectomy. Histopathology confirmed a Stage 3A endometrial carcinosarcoma with extensive myometrial invasion and lymph node involvement. Post-operative management included multiple cycles of radiation therapy, which significantly improved her quality of life. **Conclusion:** This case highlights the importance of suspicion and prompt intervention in patients presenting with symptoms indicative of UCS. Early and aggressive management can lead to improved patient outcomes, emphasizing the need for awareness and expertise in handling such rare cases.

Keywords: Uterine Carcinosarcoma, Cancer Diagnosis, Surgical Treatment, Radiation Therapy, Case Study

Introduction

Uterine carcinosarcoma (UCS) is a highly aggressive tumor with incidence of 5% of uterine malignancies [1, 2]. As a type of malignant mixed Müllerian tumors and related to poorly differentiated endometrial carcinomas, UCS is characterized by biphasic morphology with carcinomatous and sarcomatous differentiation [3, 4]. UCS was traditionally classified in the sarcoma category because of the sarcomatous component. However, molecular and genetic research has demonstrated that UCS is distinct from sarcoma, and the carcinomatous component induces the observed tumor aggressiveness and metastasis. Recent data have suggested that the origin of UCS is monoclonal, and UCS should be best categorized as a de-differentiated uterine carcinoma rather than as a sarcoma [5,6]. In this study we present a rare case study with uterine carcinosarcoma with distinctive pre operative radiological and post operative histopathological characteristics.

Case Study

A post-menopausal lady, Para 2, aged about 59 years, presented us with complaints of foul smelling vaginal discharge, bleeding per vaginum and fever. Also with history of significant weight loss in past 6 months. Patient is cachexic and febrile. On abdominal examination A mass of ~ 18-20 weeks felt in the lower abdomen, which was firm in consistency, freely mobile from side to side, felt to be arising from the uterus with mild tenderness. On Per speculum The cervix was pulled up with foul smelling discharge. She underwent CT abdomen and pelvis (fig 2) which revealed a large solid mass with necrotic contents and air foci within with possible differential diagnoses of –Endometrial Ca, Endometrial carcinosarcoma, Leiomyosarcoma. Fitness for surgery was taken. Examination under anaesthesia done cervix was completely taken up hence endometrial biopsy could not be taken and decision of Staging Laparotomy done. Intraoperative finding Uterus of ~ 18-20 weeks size seen with mass over fundal region with foul smelling necrotic central mass. Peritoneal fluid was aspirated using 5 cc syringe and sent for cytology. Peritoneal fluid is negative for malignant cells. Hysterectomy was performed with removal of parametrium. Omentectomy was done. Few suspicious lymph nodes were removed. The specimen was sent for HPE. Histopathology report (fig 3) revealed carcinosarcoma of Endometrium (pT3a) with tumor size of 13 cms. With myometrial invasion of >50% and involvement of uterine serosa and lower uterine segment. The left external iliac lymph nodes showed reactive hyperplasia. Post operatively the patient was followed up and had received 7 cycles of radiation therapy, leading good quality of life.

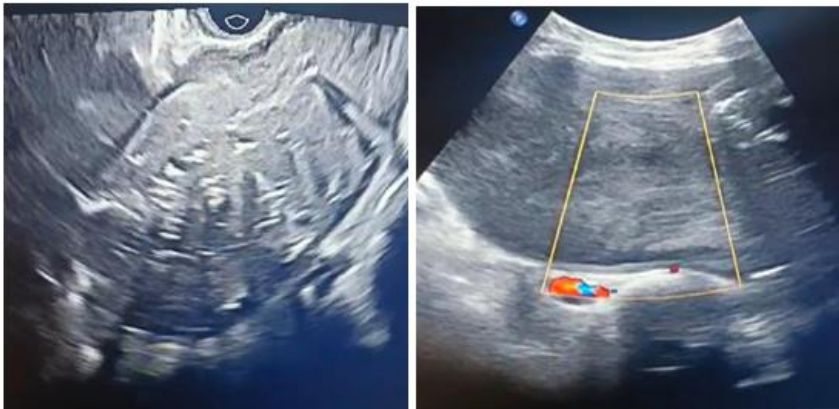

Figure 1: Heterogenous predominantly solid mass lesion involving pelvis in midline

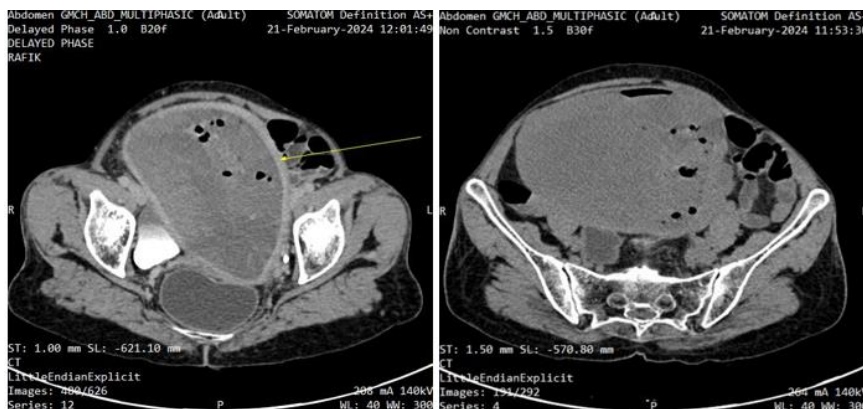


Figure 2: Large well defined hypodense to isodense solid mass with multiple hyperenhancing area s/o necrotic component and multiple air foci within the uterus

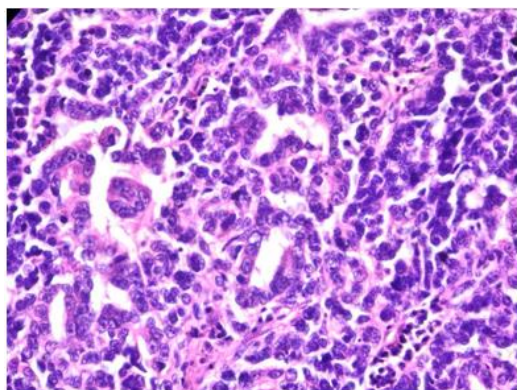


Figure 3: Carcinomatous component showing tubular arrangements of malignant cells

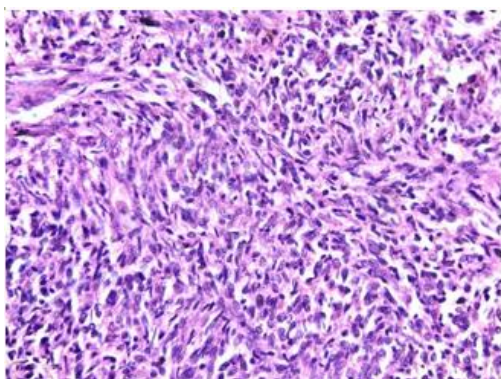


Figure 4: Sarcomatous component showing malignant mesenchymal cells arranged in interlacing fascicles and bundles.

FINAL DIAGNOSIS

Endometrial Carcinosarcoma stage 3 A.

Referred to Radiation Oncology for CT/RT.

Discussion

Uterine carcinosarcoma (UCS) is an aggressive malignancy. With an incidence of 2/100,000 females and a 5 years Survival at stage IV of 0%, it is an uncommon type of cancer with a very poor prognosis. Histologically, UCS is a biphasic neoplasm consisting of a mixture of malignant epithelial and mesenchymal components but there is now enough clinical-pathological evidence to consider UCS as metaplastic carcinoma in which the mesenchymal part retains epithelial features.[7]. The carcinomatous component of uterine CS is usually of the endometrioid type, but it may also be serous, clear cell, or squamous. The sarcomatous component may be derived from homologous tissue, such as endometrial stromal sarcoma, fibrosarcoma, or leiomyosarcoma, or it may be derived from heterologous tissue, such as rhabdomyosarcoma, chondrosarcoma, osteosarcoma, or liposarcoma[8]. The management of non-metastatic disease is based on a multimodal approach with optimal surgery followed by (concomitant or sequential) chemotherapy and radiotherapy, even for early stages. Palliative chemotherapy is recommended in the metastatic or recurrent setting, with carboplatin/paclitaxel doublet being the first-line regimen[9]. The most important prognostic factor is the stage of disease at the time of treatment. Survival is very poor when tumor extends beyond the uterus .[10] The patients with uterine carcinosarcomas should be closely followed up regardless of the disease state, because there is a high risk of local recurrence (60%) and distant metastasis[11]. The 5-year survival is 60%, 75% for uterine-confined

disease, 40-60% for early-stage disease (I and II), and 15-30% for late-stage disease, with overall median survival of less than 2 years [12]. Combination chemotherapeutic agents have been used in uterine carcinosarcoma with combination therapy appearing to be superior to single-agent treatment in terms of improvement in progression-free and overall survival[13].

FIGO CLASSIFICATION [14]

STAGE	STAGE GROUPING	FIGO STAGE	DESCRIPTION
I	T1 N0 M0	I	The cancer is growing in the uterus, but has not started growing outside the uterus. It has not spread to nearby lymph nodes (N0) or to distant sites (M0).
IA	T1a N0 M0	IA	The cancer is only in the uterus and is no larger than 5 cm across (about 2 inches) (T1a). It has not spread to nearby lymph nodes (N0) or to distant sites (M0).
IB	T1b N0 M0	IB	The cancer is only in the uterus and is larger than 5 cm across (about 2 inches). (T1b). It has not spread to nearby lymph nodes (N0) or to distant sites (M0).
II	T2 N0 M0	II	The cancer is growing outside the uterus but is not growing outside of the pelvis (T2). It has not spread to nearby lymph nodes (N0) or to distant sites (M0)
IIIA	T3a N0 M0	IIIA	The cancer is growing into tissues of the abdomen in one place only (T3a). It has not spread to nearby lymph nodes (N0) or to distant sites (M0)
IIIB	T3b N0 M0	IIIB	The cancer is growing into tissues of the abdomen in 2 or more places (T3b). It has not spread to nearby lymph nodes (N0) or to distant sites (M0)
IIIC	T1-T3 N1 M0	IIIC	The cancer is growing in the body of the uterus and it might have spread into tissues of the abdomen, but is not growing into the bladder or rectum (T1 to T3). The cancer has spread to nearby lymph nodes (N1), but not to distant sites (M0).
IVA	T4 Any N M0	IVA	The cancer has spread to the rectum or urinary bladder (T4). It might or might not have spread to nearby lymph nodes (Any N) but has not spread to distant sites (M0).
IVB	Any T Any N M1	IVB	The cancer has spread to distant sites such as the lungs, bones, or liver (M1). The cancer in the uterus can be any size and may or may not have grown into tissues in the pelvis and/or abdomen (including the bladder or rectum) (any T) and it might or might not

			have spread to nearby lymph nodes (Any N)
--	--	--	---

Conclusion

This case study highlights the clinical challenges and complexities associated with diagnosing and treating uterine carcinosarcoma (UCS), a rare and aggressive form of uterine cancer. Our report underscores the importance of a thorough diagnostic process, utilizing both radiological and histopathological evaluations to confirm the presence and extent of the disease. The management of UCS requires a multimodal approach; in this case, the combination of surgery followed by radiation therapy proved beneficial, leading to a significant improvement in the patient's quality of life.

The findings from this case reinforce the classification of UCS as a de-differentiated carcinoma rather than a traditional sarcoma, which has important implications for treatment strategies. Despite the aggressive nature of UCS and generally poor prognosis, early detection and comprehensive treatment can result in favorable outcomes. Continued research and clinical reporting are vital for enhancing our understanding of UCS and improving the therapeutic approaches for this formidable disease.

References

1. Silverberg SG, Major FJ, Blessing JA, Fetter B, Askin FB, Liao S-Y, *et al.* Carcinosarcoma (malignant mixed mesodermal tumor) of the uterus. *Int J Gynecol Pathol* (1990). 9(1):1–19. doi:10.1097/00004347-199001000-00001
2. Kernochan LE, Garcia RL. Carcinosarcomas (malignant mixed müllerian tumor) of the uterus: advances in elucidation of biologic and clinical characteristics. *J Natl Compr Canc Netw* (2009). 7(5):550–7. doi:10.6004/ jncn.2009.0037
3. Murali R, Davidson B, Fadare O, Carlson JA, Crum CP, Gilks CB, *et al.* Highgrade endometrial carcinomas. *Int J Gynecol Pathol* (2019). 38(Suppl. 1): S40–S63. doi:10.1097/pgp.0000000000000491
4. Pang A, Carhini M, Moreira AL, Maki RG. Carcinosarcomas and related cancers: tumors caught in the act of epithelial-mesenchymal transition. *Jco* (2018). 36(2):210–6. doi:10.1200/jco.2017.74.9523
5. Fujii H, Yoshida M, Gong ZX, Matsumoto T, Hamano Y, Fukunaga M, *et al.* Frequent genetic heterogeneity in the clonal evolution of gynecological carcinosarcoma and its influence on phenotypic diversity. *Cancer Res* 2000;60:114-20.
6. Schipf A, Mayr D, Kirchner T, Diebold J. Molecular genetic aberrations of ovarian and uterine carcinosarcomas: a CGH and FISH study. *Virchows Arch* 2008;452:259-68
7. Artioli G, Wabersich J, Ludwig K, Gardiman MP, Borgato L, Garbin F. Rare uterine cancer: carcinosarcomas. Review from histology to treatment. *Crit Rev Oncol Hematol*. 2015 Apr;94(1):98-104. doi: 10.1016/j.critrevonc.2014.10.013. Epub 2014 Nov 7. PMID: 25468677.
8. Jin Z., Ogata S., Tamura G., Katayama Y., Fukase M., Yajima M. and Motoyama T. (2003). Carcinosarcomas (malignant müllerian mixed tumors) of the uterus and ovary: A genetic study with special reference to histogenesis. *Int. J. Gynecol. Pathol.* 22, 368-373
9. Bogani G, Ray-Coquard I, Concin N, Ngoi NYL, Morice P, Caruso G, Enomoto T, Takehara K, Denys H, Lorusso D, Coleman R, Vaughan MM, Takano M, Provencher DM, Sagae S, Wimberger P, Póka R, Segev Y, Kim SI, Kim JW, Candido Dos Reis FJ,s Ramirez PT, Mariani A, Leitao M, Makker V, Abu-Rustum NR, Vergote I, Zannoni G, Tan D, McCormack M, Paolini B, Bini M, Raspagliesi F, Benedetti Panici P, Di Donato V, Muzii L, Colombo N, Pignata S, Scambia G, Monk BJ. Endometrial carcinosarcoma.

- Int J Gynecol Cancer. 2023 Feb 6;33(2):147-174. doi: 10.1136/ijgc-2022-004073. PMID: 36585027.
10. Dave KS, Chauhan A, Bhansali R, Arora R, Purohit S. Uterine carcinosarcomas: 8-year single center experience of 25 cases. *Indian J Med Paediatr Oncol* 2011;32:149-53
 11. L. A. Cantrell, S. V. Blank, and L. R. Duska, "Uterine carcinosarcoma: a review of the literature," *Gynecologic Oncology*, vol. 137, no. 3, pp. 581–588, 2015.
 12. N. Bansal, T. J. Herzog, V. E. Seshan *et al.*, "Uterine carcinosarcomas and grade 3 endometrioid cancers: evidence for distinct tumor behavior," *Obstetrics & Gynecology*, vol. 112, no. 1, pp. 64–70, 2008.
 13. Galaal K, van der Heijden E, Godfrey K, Naik R, Kucukmetin A, Bryant A, Das N, Lopes AD. Adjuvant radiotherapy and/or chemotherapy after surgery for uterine carcinosarcoma. *Cochrane Database Syst Rev.* 2013 Feb 28;2013(2):CD006812. doi: 10.1002/14651858.CD006812.pub3. PMID: 23450572; PMCID: PMC6457622.
 14. National Cancer Institute. Uterine Sarcoma Treatment (PDQ®)–Patient Version. April 8, 2022. Accessed at <https://www.cancer.gov/types/uterine/patient/uterine-sarcomatreatment-pdq> on June 7, 2022.