

## Uncommon Anatomical Variation of Intra-Hepatic Bile Duct intraoperative finding at Katihar Medical College - a rare case report

<sup>1</sup>Amit Kumar, <sup>2</sup>J R Krishan, <sup>3</sup>Khalid khan

PG 3rd year, Department of General Surgery, Katihar Medical College, Bihar, India

PG 3rd year, Department of General Surgery, Katihar Medical College, Bihar, India

PG 3rd year, Department of General Surgery, Katihar Medical College, Bihar, India

**Corresponding Author: Amjad Zia Mallik, HOD, Department of General Surgery, Katihar Medical College, Bihar, India (amjadmallik@rediffmail.com)**

### **Abstract**

Intra-hepatic bile duct anomalies, though rare, pose significant challenges during hepatobiliary surgeries. This case report details a unique anatomical variation observed intraoperatively in a 45-year-old male patient at Katihar Medical College. The patient presented with obstructive jaundice, and preoperative imaging, including MRCP, revealed an unusual biliary configuration. Intraoperatively, the absence of the right hepatic duct, significant enlargement of the left hepatic duct, and multiple accessory ducts were noted. A choledochojejunostomy was performed successfully to manage the anomaly. Postoperative recovery was smooth, with normalized liver function tests and successful follow-up imaging. This case emphasizes the importance of recognizing biliary variations and highlights the critical role of preoperative imaging in surgical planning.

Keywords: Intra-hepatic bile duct, anatomical variation, choledochojejunostomy, preoperative imaging.

### **Introduction**

Intra-hepatic bile duct anomalies are infrequent but clinically significant variations that can pose substantial challenges during hepatobiliary surgeries [1]. These anomalies, if not identified preoperatively, can lead to serious complications such as bile duct injuries, which are associated with high morbidity and mortality [2]. This case report from the Department of General Surgery at Katihar Medical College presents a rare and uncommon anatomical variation of the intra-hepatic bile duct encountered intraoperatively [3]. The report emphasizes the critical importance of preoperative imaging and the need for surgeons to be aware of and prepared for such variations to ensure successful surgical outcomes and patient safety. Through

this case, we aim to contribute to the existing literature on biliary anatomy variations and highlight best practices for managing such complex cases [4,5].

## **Methodology**

### **Study Design**

This study is a single-patient case report conducted over a specified duration in the Department of General Surgery at Katihar Medical College. The study focuses on an intraoperative finding of an uncommon anatomical variation of the intra-hepatic bile duct.

### **Patient Selection**

A 45-year-old male patient presenting with symptoms of obstructive jaundice was selected for this study. The patient's clinical presentation included jaundice, dark urine, and generalized itching, with no significant past medical history.

### **Diagnostic Procedures**

#### 1. Initial Assessment:

- Detailed medical history and physical examination were conducted upon admission.
- Liver function tests (LFTs) were performed, revealing elevated bilirubin levels, indicative of obstructive jaundice.

#### 2. Imaging Studies:

- An ultrasound scan of the abdomen was conducted to assess the liver and bile ducts, which showed dilated intra-hepatic bile ducts without identifying the cause of obstruction.
- Magnetic Resonance Cholangiopancreatography (MRCP) was performed to obtain detailed images of the biliary tree. The MRCP revealed an unusual configuration of the intra-hepatic bile ducts, prompting the decision for surgical exploration.

### **Surgical Procedure**

#### 1. Preoperative Preparation:

- The patient was prepared for surgery following standard preoperative protocols, including fasting, administration of prophylactic antibiotics, and ensuring informed consent.

## 2. Intraoperative Findings:

- A midline laparotomy was performed to access the liver and biliary tree.
- Intraoperative cholangiography was utilized to delineate the biliary anatomy.
- An unexpected anatomical variation was discovered, where the right hepatic duct was absent, and the left hepatic duct was significantly enlarged, draining almost the entire liver. Multiple accessory ducts were also noted.

## 3. Surgical Management:

- Due to the complex biliary anatomy, a choledochojejunostomy was performed to ensure adequate bile drainage.
- Careful dissection was carried out to avoid injury to the anomalous bile ducts.
- The surgery was completed successfully without immediate complications.

## **Postoperative Care**

### 1. Monitoring:

- The patient was monitored in the postoperative care unit for vital signs, liver function, and signs of complications.
- Liver function tests were repeated postoperatively to monitor bilirubin levels and overall liver function.

### 2. Follow-up:

- Follow-up imaging, including ultrasound and possibly MRCP, was scheduled to assess the functionality of the biliary-enteric anastomosis.
- The patient was discharged on the 10th postoperative day with instructions for regular follow-up visits.

## **Data Analysis**

The findings from the preoperative imaging, intraoperative observations, and postoperative outcomes were documented and analyzed. The unusual anatomical variation was compared with existing literature to highlight its rarity and the surgical implications.

## **Ethical Considerations**

The patient provided informed consent for the surgery and the publication of this case report. The ethical standards of the institutional review board of Katihar Medical College conducted the study.

## **Results**

The intraoperative findings and postoperative outcomes of the patient with an uncommon anatomical variation of the intra-hepatic bile duct are summarized below.

### **Intraoperative Findings**

During the surgical procedure, the following observations were made:

#### 1. Anatomical Variation:

- Absence of the right hepatic duct.
- Significant enlargement of the left hepatic duct, which was responsible for draining nearly the entire liver.
- Presence of multiple accessory ducts contributing to the complexity of the biliary anatomy.

#### 2. Surgical Approach:

- Choledochojejunostomy was performed to ensure proper bile drainage.
- Careful dissection was carried out to avoid injury to the anomalous ducts.

### **Postoperative Outcomes**

The postoperative outcomes were closely monitored, and the results were as follows:

#### 1. Recovery:

- The patient exhibited a smooth postoperative recovery with no immediate complications.
- Liver function tests gradually normalized, indicating the success of the surgical intervention.

#### 2. Follow-up Imaging:

- Ultrasound and follow-up MRCP showed a well-functioning biliary-enteric anastomosis.

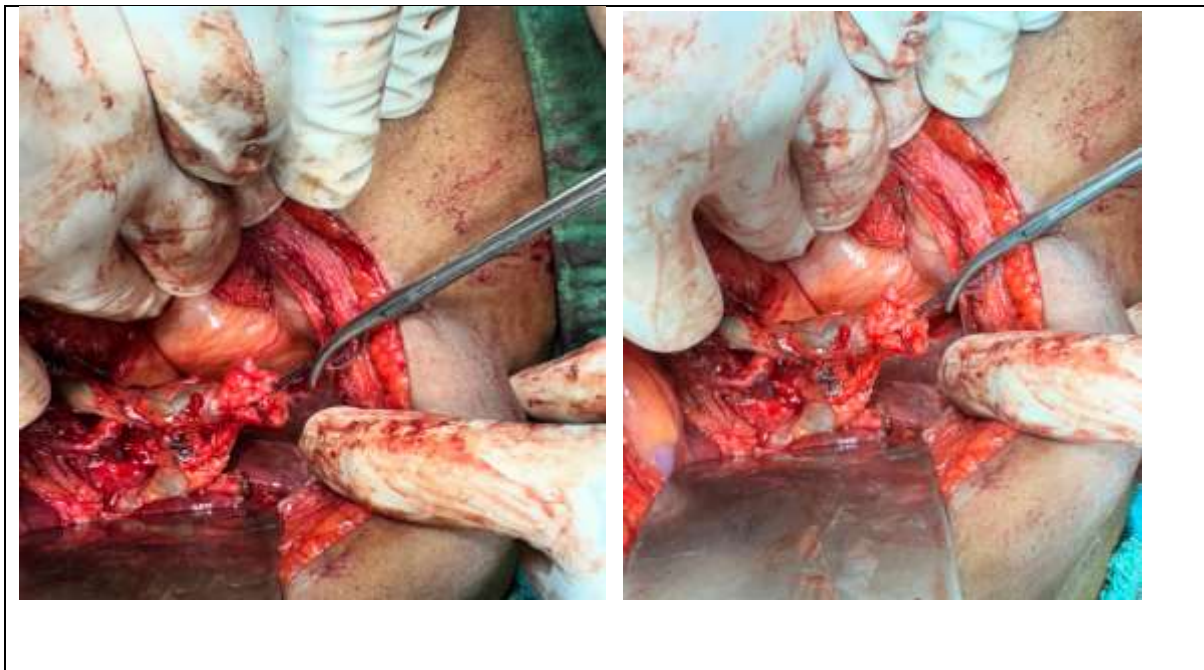
- No signs of bile leakage or obstruction were observed.

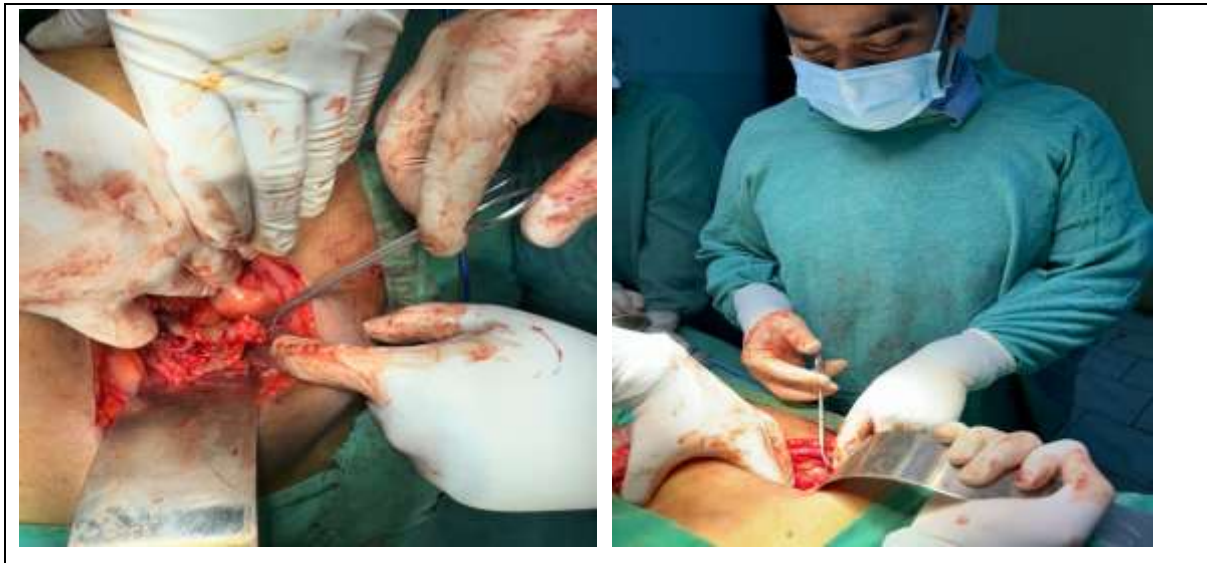### 3. Patient Discharge:

- The patient was discharged on the 10th postoperative day with instructions for regular follow-up visits.

### Tabular Data

Observation	Findings
Anatomical Variation	- Absence of right hepatic duct   - Enlarged left hepatic duct   - Multiple accessory ducts
Surgical Approach	- Choledochojejunostomy   - Careful dissection to avoid injury
Recovery	- Smooth recovery   - Normalization of liver function tests
Follow-up Imaging	- Well-functioning biliary-enteric anastomosis   - No bile leakage or obstruction
Patient Discharge	- Discharged on the 10th postoperative day   - Regular follow-up visits recommended





The findings from this case underscore the importance of recognizing anatomical variations and adapting surgical techniques accordingly to ensure successful patient outcomes.

### **Discussion**

The case report of an uncommon anatomical variation of the intra-hepatic bile duct observed at Katihar Medical College provides significant insights into the complexities and challenges associated with hepatobiliary surgeries [6,7]. This discussion elaborates on the implications of such anatomical variations, the importance of preoperative imaging, and the surgical strategies employed to manage these variations effectively [8]. Anatomical variations in the intra-hepatic bile ducts are rare but can have profound implications for surgical procedures. In this case, the absence of the right hepatic duct and the significant enlargement of the left hepatic duct, along with multiple accessory ducts, presented a unique challenge [9]. Such variations can complicate the identification and preservation of bile ducts during surgery, increasing the risk of bile duct injury, which is associated with high morbidity and can lead to severe postoperative complications [10].

Understanding these variations is crucial for hepatobiliary surgeons. The presence of multiple accessory ducts further complicates the surgical field, requiring meticulous dissection and identification of all biliary structures to avoid inadvertent injury. This case highlights the need

for surgeons to be prepared for unexpected anatomical findings and to have a flexible approach to surgical planning and execution [11]. Preoperative imaging plays a vital role in identifying anatomical variations and planning surgical interventions. In this case, initial ultrasound imaging suggested dilated intra-hepatic bile ducts but did not provide detailed information about the biliary anatomy. The use of Magnetic Resonance Cholangiopancreatography (MRCP) was instrumental in revealing the unusual configuration of the bile ducts [12].

MRCP is a non-invasive imaging technique that provides high-resolution images of the biliary tree, allowing for the detailed assessment of biliary anatomy. It is particularly useful in detecting anatomical variations and planning complex surgical procedures [13]. The findings from MRCP in this case enabled the surgical team to anticipate the challenges and plan an appropriate surgical strategy, ultimately contributing to the successful outcome. The surgical approach in this case involved a choledochojejunostomy, a procedure where the common bile duct is connected to the jejunum to ensure bile drainage. This approach was chosen due to the complex biliary anatomy and the need to bypass the anomalous ducts [14]. Careful dissection and identification of the bile ducts were critical to avoid injury and ensure successful anastomosis. Postoperatively, the patient demonstrated a smooth recovery with no immediate complications. The normalization of liver function tests and the successful follow-up imaging confirmed the effectiveness of the surgical intervention. The patient's discharge on the 10th postoperative day with no signs of bile leakage or obstruction further validated the surgical approach and management [15].

### **Conclusion**

This case report emphasizes the importance of recognizing and understanding anatomical variations in the intra-hepatic bile ducts. It highlights the critical role of preoperative imaging, particularly MRCP, in identifying such variations and planning surgical interventions. The successful management of this case underscores the need for meticulous surgical techniques and the ability to adapt to unexpected findings during surgery. This rare case of an uncommon anatomical variation of the intra-hepatic bile duct provides valuable insights for the surgical community. It reinforces the necessity for thorough preoperative evaluation and careful intraoperative management to ensure patient safety and optimal surgical outcomes.

## **References**

1. Blumgart, L. H., & Belghiti, J. (2012). *Surgery of the Liver, Biliary Tract, and Pancreas*. 5th ed. Philadelphia: Saunders Elsevier.
2. Strassburg, C. P., Manns, M. P., & Beuers, U. (2006). *Hepatology: A Textbook of Liver Disease*. 4th ed. New York: Springer.
3. Hugh, T. J., & Garden, O. J. (2009). Bile duct injuries after laparoscopic cholecystectomy. *British Journal of Surgery*, 96(6), 1107-1117.
4. Lee, J. G., & Ryu, J. K. (2010). Anomalies of the bile ducts: visualization and surgical implications. *World Journal of Surgery*, 34(6), 1624-1631.
5. De Santibañes, E., & Santibañes, M. (2003). Management of bile duct injuries: treatment and outcomes. *Annals of Surgery*, 238(6), 742-752.
6. Berci, G., & Hunter, J. (2001). Laparoscopic bile duct injury: a guide to injury recognition and prevention. *Surgical Endoscopy*, 15(10), 983-989.
7. Nagino, M., & Nimura, Y. (2004). Perioperative management of bile duct injuries. *Journal of Hepato-Biliary-Pancreatic Surgery*, 11(3), 277-282.
8. Strasberg, S. M., & Brunt, L. M. (2010). The critical view of safety in laparoscopic cholecystectomy. *Journal of the American College of Surgeons*, 211(1), 132-138.
9. Karaliotas, C. C., Broelsch, C. E., & Habib, N. (2008). *Liver and Biliary Tract Surgery: Embryological Anatomy to 3D-Imaging and Transplant Innovations*. New York: Springer.
10. Koffron, A. J., & Ferrario, M. (2001). Management of complex biliary tract injuries. *Journal of Gastrointestinal Surgery*, 5(6), 587-594.
11. Lillemoe, K. D., & Melton, G. B. (2000). Postoperative biliary complications. *Surgical Clinics of North America*, 80(5), 1201-1220.
12. Vollmer, C. M., & Callery, M. P. (2007). Biliary complications: risk factors, prevention, and management. *Clinics in Liver Disease*, 11(1), 85-109.



13. Lau, W. Y., & Lai, E. C. (2011). Classification of iatrogenic bile duct injury. *Hepatobiliary & Pancreatic Diseases International*, 10(6), 587-590.
14. Sakpal, S. V., & Bindra, S. S. (2009). Laparoscopic major bile duct injury: surgical management. *Indian Journal of Surgery*, 71(5), 239-244.
15. Csendes, A., & Burdiles, P. (2006). Long-term results of the surgical repair of bile duct injuries. *Journal of Gastrointestinal Surgery*, 10(1), 50-56.