

Role Of Ultrasound In Evaluating And Characterizing The Adnexal Masses By Using O-Rads Classification System -A Prospective Observational Study**Dr. Saurabh Atram¹, Dr. Alka Agrawal², Dr. Rekha Khanna³, Dr. Sakina Chandan wala⁴, Dr. Farhana Hasan⁵**¹Professor, Department of Radiodiagnosis MGMMC MYH Indore (M.P.)²Professor, Department of Radiodiagnosis MGMMC MYH Indore (M.P.)³Junior Resident, Department of Radiodiagnosis MGMMC MYH Indore (M.P.)⁴Junior Resident, Department of Radiodiagnosis MGMMC MYH Indore (M.P.)⁵Junior Resident, Department of Radiodiagnosis MGMMC MYH Indore (M.P.)***Corresponding Author****Dr. Rekha Khanna****ABSTRACT**

Background-Adnexal masses are solid or cystic mass originating in the ovaries, fallopian tubes, or surrounding tissues that is often detected incidentally during pelvic imaging. Adnexal mass, which may range from simple cyst to benign or malignant ovarian mass, is one of the most common pathological conditions noted in gynaecologic practice and it can occur in women of all ages¹. This study evaluates the adnexal masses for risk of malignancy and diagnostic significance of (Ovarian adnexal reporting and data system) ORADS ultrasound risk scoring system. **Methods:** This prospective observational study was conducted in the Department of Radio-diagnosis of Mahatma Gandhi Memorial Medical College & M.Y Hospital, Indore, Madhya Pradesh, India after receiving approval by the Institutional Scientific and Ethical Committee. The duration of study was from September 2022 to September 2023. A total of 240 patients who were referred to the Department of Radio-diagnosis for ultrasonography on clinical suspicious of adnexal lesion and were included in the study. **Results-** Among the 240 cases examined, ORADS 2 was the most prevalent, comprising 96 cases (40%), followed by ORADS 3 with 55 cases (23%). ORADS 1 accounted for 33 cases (15%), ORADS 4 for 35 cases (14%), and ORADS 5 for 21 cases (9%). Out of 240 cases on the basis of histopathological findings /follow up scan all ORADS 1 lesion were benign in contrast ORADS 2 lesions were (1 out of 86) 0.8% malignant, ORADS 3 lesion were (4 out of 55) 8% malignant, ORADS 4 lesion were (16 out of 35) 45% malignant and ORADS 5 lesion were (19 out of 21) 89% malignant. Statistically significance correlation was observed with ORADS grading 4 and 5 and risk of malignancy with p values <.0001 and the Area under the curve is 93.2% with a sensitivity of 95.66% and specificity of 75.21% which is statistically significant.

Conclusion- ORADS improve the sensitivity and specificity of ultrasound in distinguishing between benign and malignant adnexal masses.

Keywords: Ovarian adnexal reporting and data system, Adnexal masses, Colour score, Histopathological examination

BACKGROUND

Adnexal masses are solid or cystic mass originating in the ovaries, fallopian tubes, or surrounding tissues that is often detected incidentally during pelvic imaging. Adnexal mass, which may range from simple cyst to benign or malignant ovarian mass, is one of the most common pathological conditions noted in gynaecologic practice and it can occur in women of all ages. The overall incidence of malignant neoplasms noted in adnexal masses is around 1-8%. In India prevalence of adnexal lesion is 16%.⁽¹⁾ Ovarian cancer is the third most common gynaecological malignancy after cervical and uterine malignancy in the world and has the highest mortality rate among gynaecological cancers. According to Global Cancer Observatory 2018, the age-standardized incidence rate of ovarian cancer for India is 3.8-5.5 cases per 100,000 females per year.⁽²⁾ Therefore, accurate differentiation between benign and malignant adnexal masses is crucial for effective management.

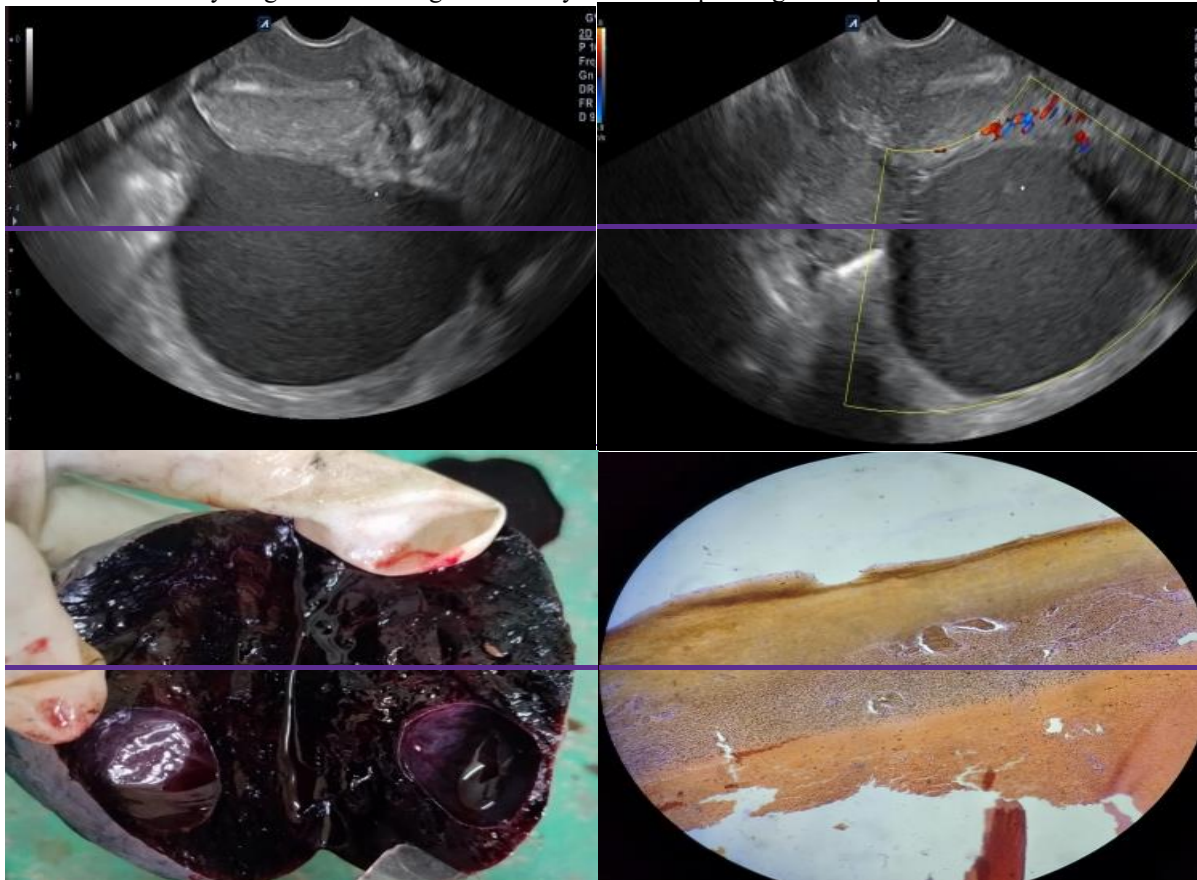
The basic goal of imaging in a patient with adnexal lesion is to identify a malignant mass which requires further evaluation and active management. Ultrasonography is the first-line imaging technique for assessing these masses because it is a simple and non-invasive diagnostic method, low cost, widely available, portable and lack of risk associated with ionization radiation, direct visualization of lesions in real-time and colour doppler findings can improve the morphology assessment on ovarian cancer risk. Its accessibility makes it a preferred initial imaging modality for evaluating adnexal masses. Other imaging modalities, such as CT scans and MRIs, can be used to diagnose adnexal masses.

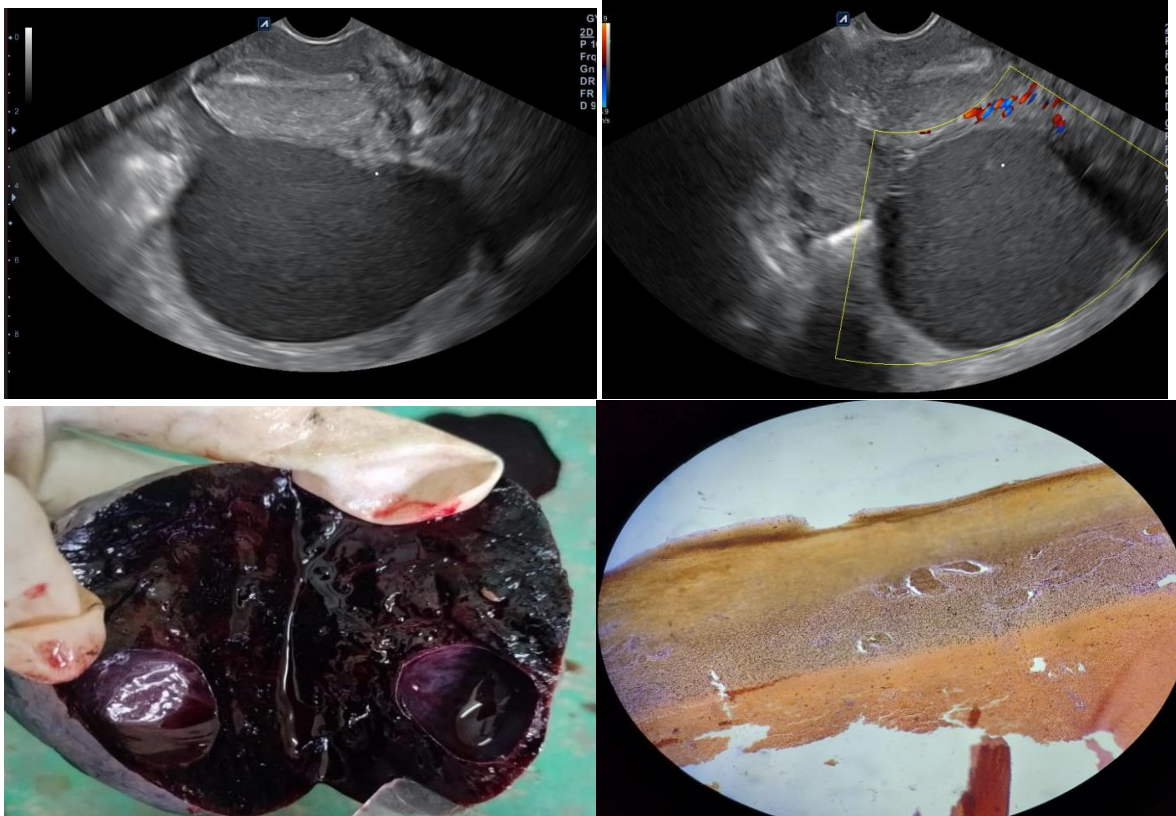
In 2018, the American college of radiology (ACR), jointly with International ovarian tumour analysis (IOTA), reported a white paper about the so-called Ovarian adnexal reporting and data system (ORADS) for classifying adnexal masses.⁽³⁾ Among the various classification system used in ultrasound assessment, the ORADS stands out as a comprehensive framework for standardizing the interpretation and reporting of adnexal masses. It categorizes masses into 5 categories. Size, shape, septations, papillary projection, solid nodules and vascularity are the key features evaluated under ORADS. The aims of using ORADS is to have a uniform unambiguous sonographic evaluation of ovarian or adnexal lesions, it helps in accurately assigning each lesion to a risk of malignancy, which determines the appropriate management. Malignant tumours require extensive surgical removal, whereas benign tumours usually can be managed with less invasive treatments. Thus, our study aims to explore the importance of ultrasound to evaluate adnexal masses for the risk of malignancy.

METHODS

Our study was a hospital based, time bound and prospective study, conducted in the Department of Radiodiagnosis of Mahatma Gandhi Memorial Medical College & M.Y Hospital, Indore, Madhya Pradesh, India after receiving approval by the Institutional Scientific and Ethical Committee. The duration of study was from September 2022 to September 2023. A total of 240 patients who were referred to the Department of Radiodiagnosis for ultrasonography on clinical suspicion of adnexal lesion and were included in the study. **Inclusion criteria:** All patients who are referred for on clinical suspicion of adnexal lesions. Patient above 18 years. **Exclusion criteria:** Patient who had previously undergone oophorectomy, Pregnancy, Trauma, Patients with normal pelvic USG findings will be excluded. **Equipment and Technique:** Ultrasound examination was done by using a curvilinear trans-abdominal (2-5 MHz) and trans-vaginal probe (5-7.5 MHz) **Study Protocol:** 240 Patients were included in the study after detailed history and examination as per the inclusion and exclusion criteria. Informed consent taken after a complete description of study and handing over patient information document. A detailed history of the patient, physical examination findings and radio logical investigations were recorded and tabulated.

CASE 1: A young female aged 30 years complaining of pain in lower abdomen.

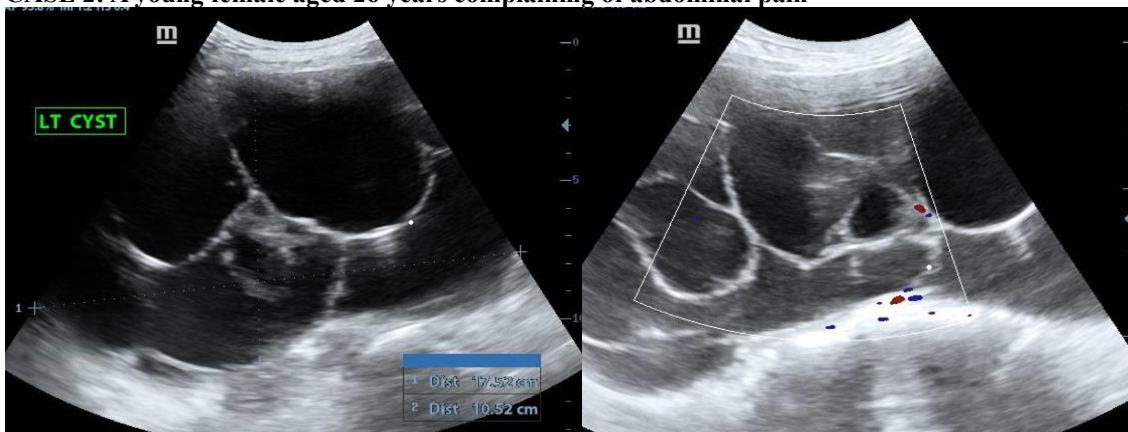


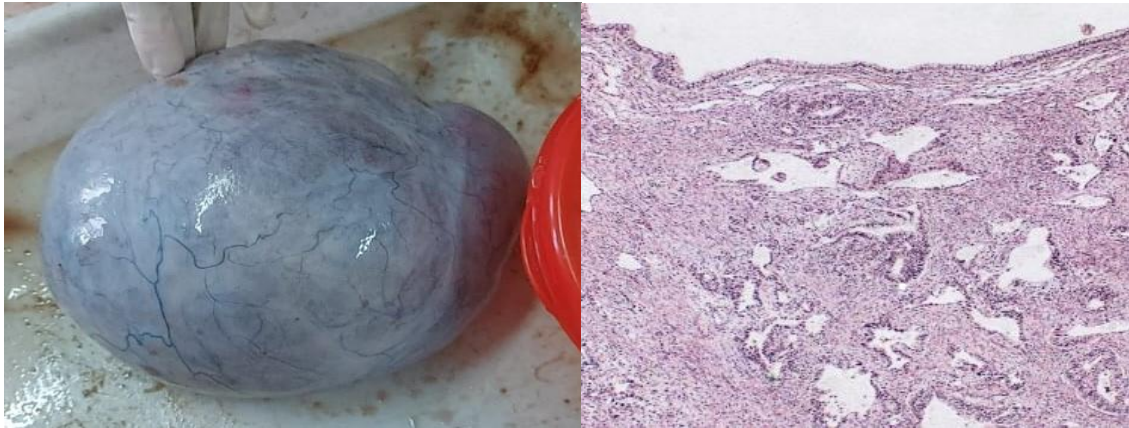


a) Transvaginal ultrasound exam revealed a unilocular cystic lesion < 10 cm with smooth inner wall containing low level, homogenous “ground glass” like internal echoes.

b) Colour doppler exam. Showed no vascularity (Colour score 1), ORADS 2 (Benign featuring cystic lesion). Histopathological examination revealed: **ENDOMETRIOMA (CHOCOLATE CYST)**

CASE 2: A young female aged 26 years complaining of abdominal pain





- a) Abdominal U/S exam. revealed a 17*10 cm sized multilocular cystic lesion with smooth inner wall with thick septa and internal homogenous contents
 b) Colour Doppler exam. Showed mild vascularity (CS2), O-RADS 4
 Histopathological examination revealed: **Mucinous cystadenoma ovary**

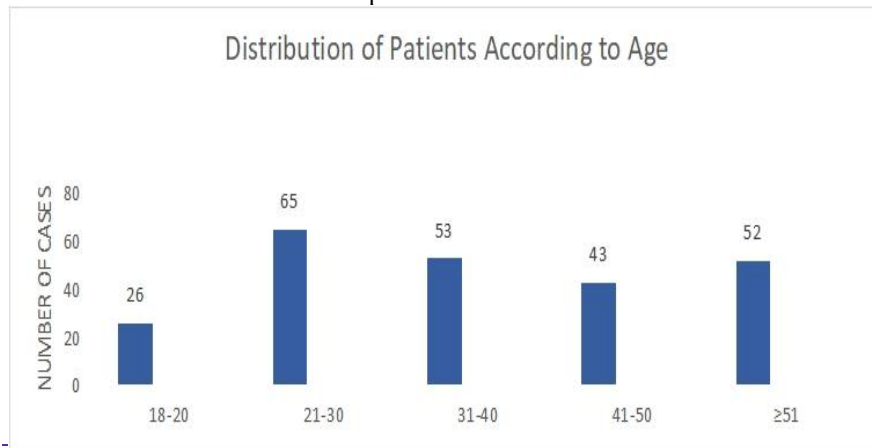
RESULTS

In this study, 240 patients were included with ages ranging from 18 to 73 years. The maximum number of patients was in the group between 21 to 30 years (27%), followed by 31 to 40 years (23%). Minimum number of patients was in group between 18 to 20 years (11%). Mean age of patients was 38.84 years [SD = 14.088].

Table 1: Distribution of Patients According to Age

Age group (Years)	Number of cases(N)	Percentages (%)
18-20	26	11
21-30	65	27
31-40	53	23
41-50	43	18
≥51	52	21
Total	240	100

Graph no.1



The majority of the patients presented with abdominal pain (166 patients, 69%), followed by abdominal swelling (60 patients, 25%), 15% patients presented with dysmenorrhea, 8% patients with changes in bowel habits, 6% patients with abnormal bleeding and 4% patients suffered with infertility.

On the basis of grey scale and colour doppler Sono-morphological characteristics adnexal lesions were categorized into various grades of ORADS. Among the 240 cases examined, ORADS 2 was the most prevalent, comprising 96 cases (40%), followed by ORADS 3 with 55 cases (23%). ORADS 1 accounted for 33 cases (15%), ORADS 4 for 35 cases (14%), and ORADS 5 for 21 cases (9%). Out of 240 cases on the basis of histopathological findings /follow up scan all ORADS 1 lesion were benign in contrast ORADS 2 lesions were (1 out of 86) 0.8% malignant, ORADS 3 lesion were (4 out of 55) 8% malignant, ORADS 4 lesion were (16 out of 35) 45% malignant and

ORADS 5 lesion were (19 out of 21) 89% malignant. Statistically significance correlation was observed with ORADS grading 4 and 5 and risk of malignancy with p values <.0001 and the Area under the curve is 93.2% with a sensitivity of 95.66% and specificity of 75.21% which is statistically significant.

Table 2: Distribution of patients on the basis of clinical manifestations

Clinical symptoms	Number of cases (N)	Percentages (%)
Abdominal swelling	60	25
Abdominal pain	166	69
Abnormal bleeding	14	6
Dysmenorrhea	36	15
Changes in bowel habits	19	8
Infertility	10	4

Graph no.2

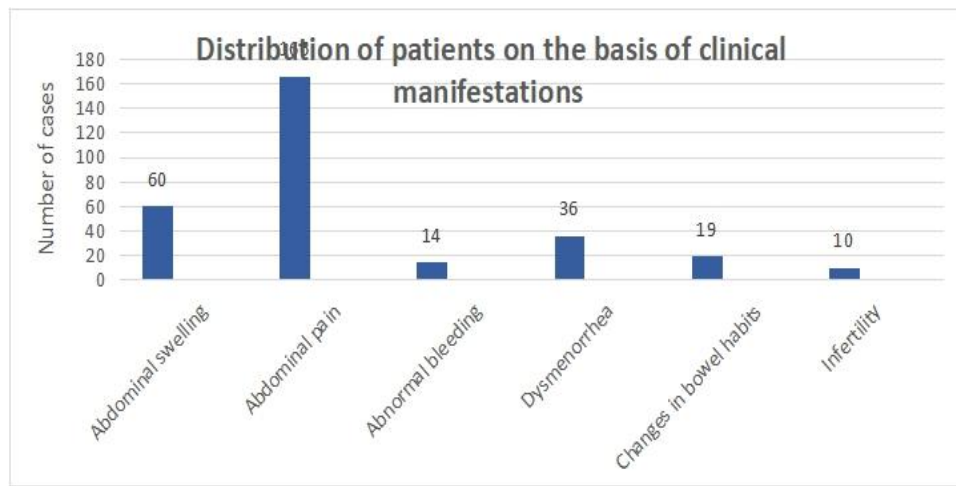


Table 3: Distribution of patients according to ORADS grading on the basis of grey scale and colour doppler characteristics

Grades	Numbers of cases	Percentages
ORADS 1	33	15
ORADS 2	96	40
ORADS 3	55	23
ORADS 4	35	14
ORADS 5	21	9
TOTAL	240	100

Graph 3

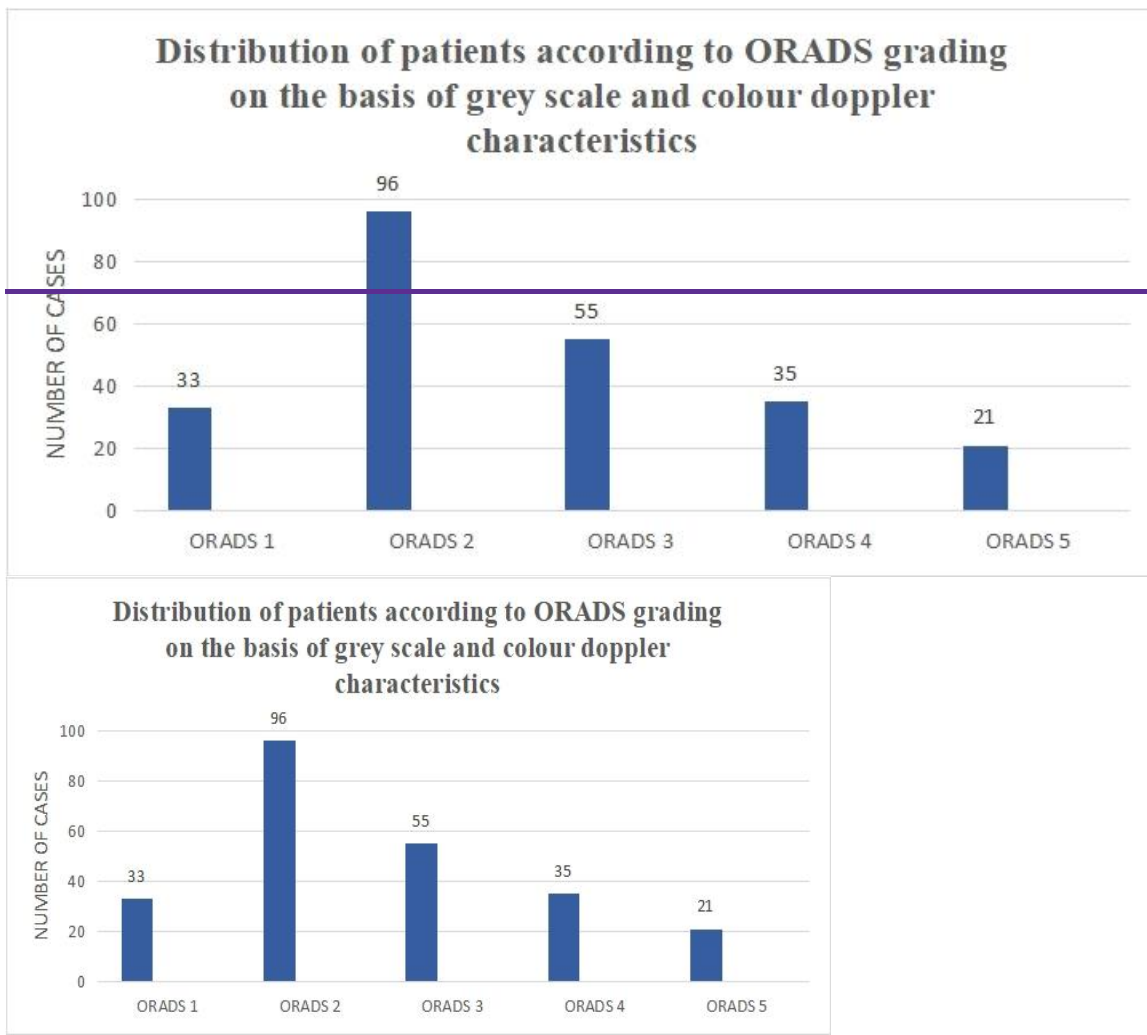
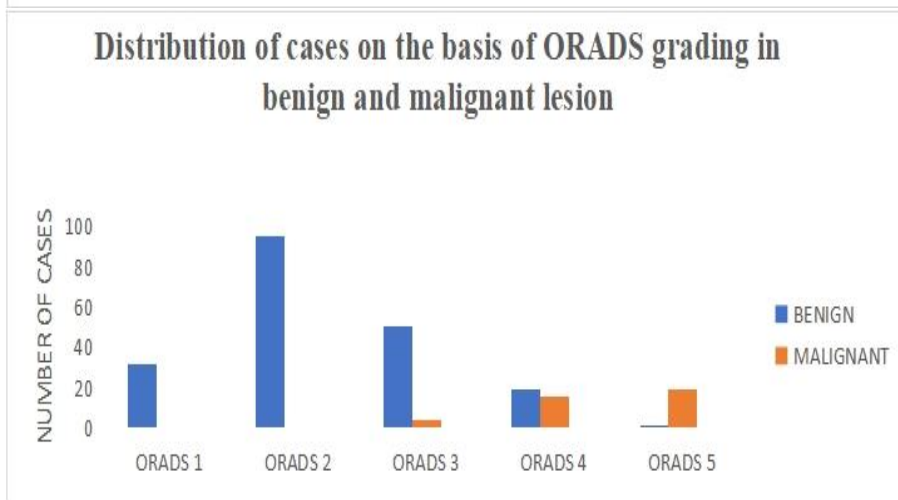
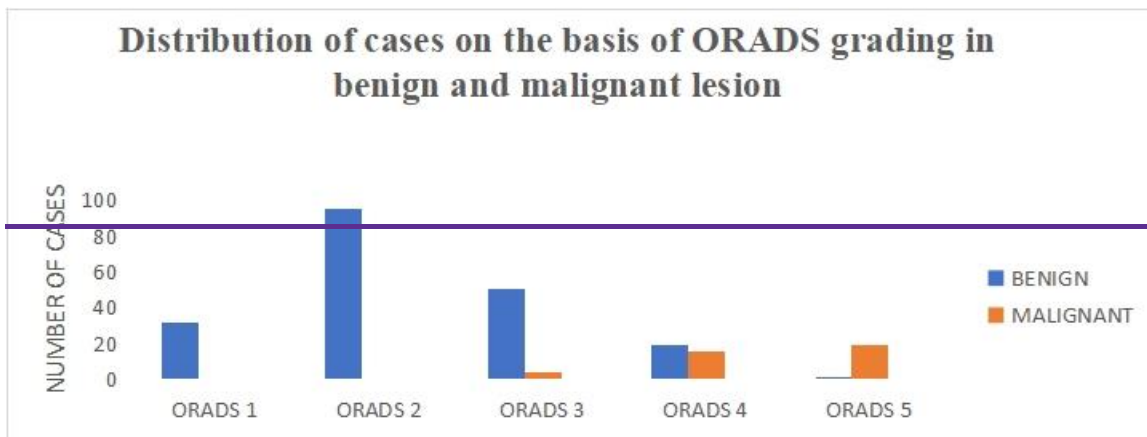


Table 4: Distribution patients according to ORADS on the basis of histopathology findings/follow up

ORADS	BENIGN		MALIGNANT		P value
	Number of cases	Percentage	Number of cases	Percentage	
ORADS 1	33	100	0	0	0.99
ORADS 2	95	99	1	0.8	0.92
ORADS 3	51	92	4	8	< 0.1
ORADS 4	19	55	16	45	<.0001
ORADS 5	2	14	19	89	<.0001

Graph 4



DISCUSSION

In our study, we included 240 patients with ages ranging from 18 to 73 years. The maximum number of patients was in the group between 21 to 30 years (27%), followed by 31 to 40 years (23%). Mean age of patients was 38.84 years [SD = 14.088]. The majority of patients presented with abdominal pain (166 patients, 69%), followed by abdominal swelling (60 patients, 25%) as the main complaints. The most prevalent findings included 108 cases (45%) of unilocular lesions without any solid components, unilocular with solid component were 24(10%), multilocular with no solid component were 38(16%), multilocular with solid component 48(20%) and least common was solid 22(9%). among 218 cystic and solid cystic lesions, 132 lesions (60%) showed no septa, 66 lesions (30%) had thin septa, and 20 lesions (9%) had thick septa, defined as septal thickness ≥ 3 mm. inner margins or walls were regular in 135 cases (62%) and irregular in 83 cases (38%). papillary projections were observed in 52 lesions (24%), with 48% of these being malignant. Among the 218 solid cystic cases, solid components were present in 56 cases (26%), and 85% of the malignant lesions had solid components with p value<000.1. Papillary projections and solid components are due to atypical epithelial cell growth that forms complex structures.

On the basis of grey scale and colour doppler Sono-morphological characteristics adnexal lesions were categorized into various grades of ORADS. Among the 240 cases examined, ORADS 2 was the most prevalent, comprising 96 cases (40%), followed by ORADS 3 with 55 cases (23%). ORADS 1 accounted for 33 cases (15%), ORADS 4 for 35 cases (14%), and ORADS 5 for 21 cases (9%).

On histopathological findings/follow up correlation all ORADS 1 lesion turned out to be benign, in contrast ORADS 2 lesions were (1 out of 86) 0.8% malignant, ORADS 3 lesion were (4 out of 55) 8% malignant, ORADS 4 lesion were (16 out of 35) 45% malignant and ORADS 5 lesion were (19 out of 21) 89% malignant. with the p value <.0001 and it was observed that as the ORADS grade from 1 to 5 increases the proportion of lesions tend to be malignant, that was statistically significant.

LIMITATIONS: Acknowledging the limitations of this study, such as limited field of view and reduced sensitivity in certain populations such as obese patients, ultrasound may be less effective due to poor acoustic windows.

CONCLUSION: The implementation of the Ovarian adnexal reporting and data system (ORADS) classification system enhances the diagnostic accuracy and consistency in assessing adnexal masses. The optimal ORADS ultrasound cutoff score for malignant neoplasm was an ORADS score of 4 or higher, and gynaecology oncology referral in these patients would be advantageous for patient outcomes. Adnexal lesions scored as ORADS 2 or 3 had a very low chance of cancer, supporting conservative management for these lesions.

ABBREVIATIONS: ORADS: Ovarian Adnexal Reporting And Data System, CS: Colour score, ACR: American college of radiology, IOTA: International ovarian tumour analysis, HPE: Histopathological examination

REFERENCES:

1. Timmermans S, Tavory I. Theory construction in qualitative research: From grounded theory to abductive analysis. *Sociological theory*. 2012 Sep;30(3):167-86.
2. Vara J, Pagliuca M, Springer S, Gonzalez de Canales J, Brotons I, Yalcich J, Ajossa S, Pascual MA, Guerriero S, Alcazar JL. O-RADS classification for ultrasound assessment of adnexal masses: agreement between IOTA lexicon and ADNEX model for assigning risk group. *Diagnostics*. 2023 Feb 10;13(4):673.
3. Hack K, Glanc P. The abnormal ovary: evolving concepts in diagnosis and management. *Obstetrics and Gynaecology Clinics*. 2019 Dec 1;46(4):607-24.
4. Phillips CH, Guo Y, Strachowski LM, Jha P, Reinhold C, Andreotti RF. The ovarian/adnexal reporting and data system for ultrasound: from standardized terminology to optimal risk assessment and management. *Canadian Association of Radiologists Journal*. 2023 Feb;74(1):44-57.
5. Abbas AM, Zahran KM, Nasr A, Kamel HS. A new scoring model for characterization of adnexal masses based on two-dimensional Gray-scale and colour Doppler sonographic features. *Facts, views & vision in Obs Gyn* 2014;6(2):68.
6. Valentin L, Ameye L, Savelli L, Fruscio R, Leone FP, Czekierdowski A, Lissoni AA, Fischerova D, Guerriero S, Van Holsbeke C, Van Huffel S. Unilocular adnexal cysts with papillary projections but no other solid components: is there a diagnostic method that can classify them reliably as 105benign or malignant before surgery? *Ultrasound in Obstetrics & Gynaecology*. 2013 May;41(5):570-81.
7. Alcázar JL, Pascual MA, Graupera B, Aubá M, Errasti T, Olartecoechea B, Ruiz-Zambrana A, Hereter L, Ajossa S, Guerriero S. External validation of IOTA simple descriptors and simple rules for classifying adnexal masses. *Ultrasound in Obstetrics & Gynaecology*. 2016 Sep;48(3):397-402.
8. [Hermans AJ, Kluivers KB, Janssen LM, Siebers AG, Wijnen MH, BultenParazzini F, Frattaruolo MP, Chiaffarino F, Dridi D, Roncella E, Vercellini P](#). The limited oncogenic potential of unilocular adnexal cysts: A systematic review and meta-analysis. *European Journal of Obstetrics & Gynaecology and Reproductive Biology*. 2018 Jun 1;225:101-9.
9. [Sadowski EA, Paroder V, Patel-Lippmann K, Robbins JB, Barroilhet L, Maddox E, McMahon T, Sampene E, Wasnik AP, Blaty AD, Maturen KE](#). Indeterminate adnexal cysts at US: prevalence and characteristics of ovarian cancer. *Radiology*. 2018 Jun;287(3):1041-9.
10. [Smith-Bindman R, Puder L, Johnson E, Miglioretti DL](#). Risk of malignant ovarian cancer based on ultrasonography findings in a large unselected population. *JAMA Internal Medicine*. 2019 Jan 1;179(1):71-7