

## CASE REPORT

### SMALL BOWEL CAVERNOUS HEMANGIOMA COMPLICATED WITH OOGIB: REPORT OF A RARE CASE FROM EASTERN PART OF INDIA

**Dr Arunkumar U<sup>1\*</sup>, Dr Aniket Halder<sup>2</sup>, Dr Hamsa K<sup>3</sup>**

<sup>1\*</sup>Senior Resident, Department Gastroenterology, SDLD, IPGMER & SSKMH, Kolkata.

<sup>2</sup>Associate Professor, Department of GI Pathology, SDLD, IPGMER & SSKMH, Kolkata

<sup>3</sup>MDRD radiologist, Assistant professor, Dept of Radiology, AJ Institute of Medical Sciences, Mangalore.

**Corresponding author: Arun Kumar**

Senior Resident, Department Gastroenterology, SDLD, IPGMER & SSKMH, Kolkata.

**Email - arunkumar1070@gmail.com**

#### **Abstract:**

**Background:** Cavernous hemangioma of the small intestine is rare in adults. Obscure Overt Gastrointestinal bleeding (OOGIB) caused by small bowel hemangioma is extremely rare. According to the size of the affected vessels, hemangiomas are histologically classified into cavernous, capillary, and mixed-type tumors, with the cavernous type being the most common and racemose being very rare in the clinic. Owing to the rarity of gastrointestinal hemangiomas and the lack of specific manifestations and diagnostic methods, the source of GI bleeding could not be initially identified despite the use of numerous diagnostic modalities.

**Case Summary:** We report the case of a 40-year-old female presenting with painless melena and postprandial bloating. Laboratory investigations revealed recurrent and prominent anemia. DBE (Double-balloon endoscopy) revealed subepithelial lesion in the distal jejunum. Segmental resection of the lesion in the jejunum was performed, and cavernous hemangioma was diagnosed based on histopathological analysis. Segmental resection of the ileal lesion was performed surgically, and the final pathological results revealed a diagnosis of cavernous hemangioma.

At present the patient is symptom free and doing fine.

**Conclusion:** The current report will increase our understanding of the diagnosis and treatment of gastrointestinal hemangiomas and provide a review of the related literature.

**Keywords:** Hemangiomas, OOGIB, Cavernous.

## INTRODUCTION

Hemangiomas are benign vascular lesions of endothelial cells that comprise < 0.05% of all gastrointestinal neoplasms. Hemangiomas are histologically classified as capillary, cavernous or mixed hemangiomas. Cavernous Hemangioma is a rare disease in adults that is usually located in the jejunum [1]. Acute intestinal bleeding leading to anemia is the most common presentation in most patients [2]. Herein, we report an adult patient with small bowel cavernous hemangioma presenting with anemia and lower GI bleeding and discuss it in light of other previously reported cases. Study conducted in the month of July 2023 - Department of Gastroenterology, SDLD, IPGMER & SSKMH, Kolkata-700020.

## CASE REPORT

**Chief complaints:** A 40-year-old woman presented to the outpatient department with five–six episodes of melena accompanied by postprandial bloating. She had history of repeated blood transfusions (4 units PRBC) for anemia for one year. no history of fever, nausea, hematemesis, hematochezia, weight loss, or intestinal obstruction.

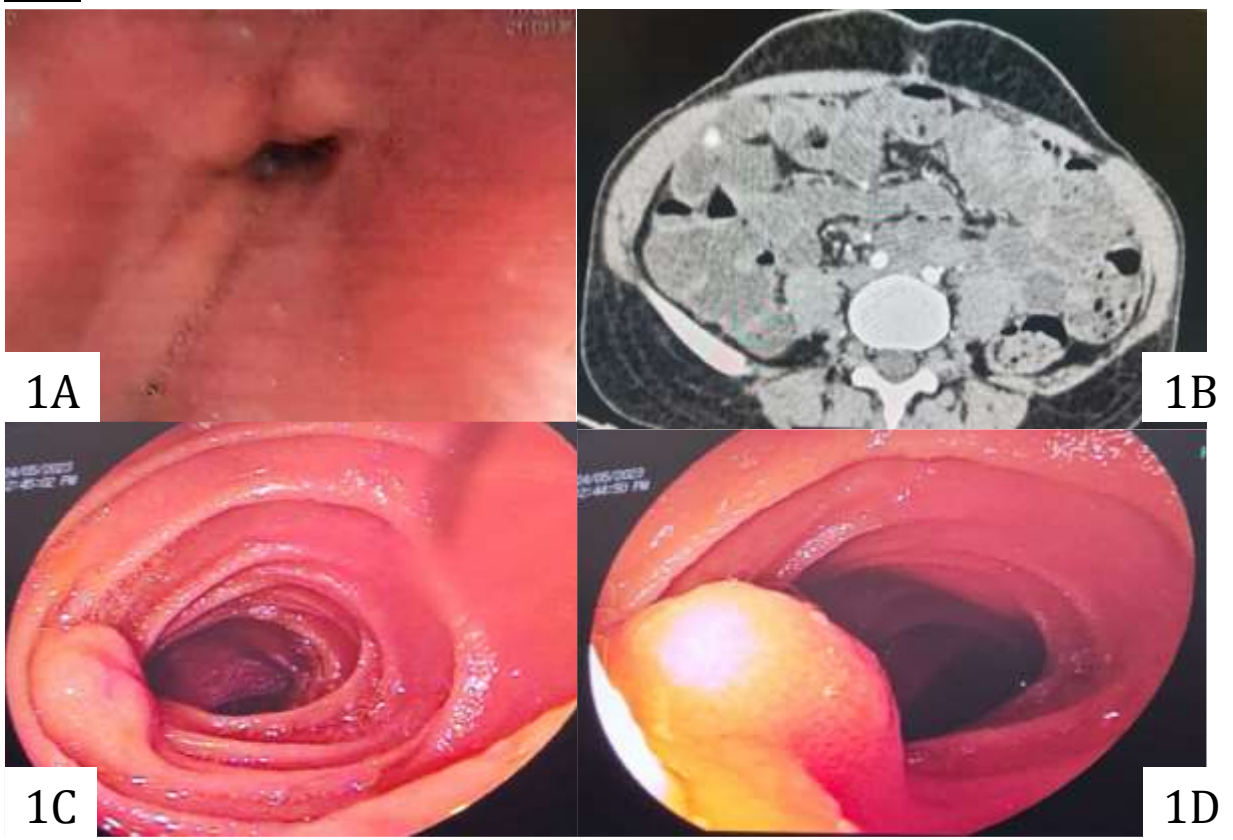
Physical Examination revealed a pulse rate of 110bpm, a Blood Pressure of 100/60 mmHg, and a Respiratory Rate was 18cpm. Pallor was present. Her abdomen was soft and non-tender, with no evidence of an abdominal mass.

**Laboratory investigations:** Study revealed Hb level of 5.4 gm/dl.

Upper GI endoscopy was normal (Fig 1A). Colonoscopy was normal.

**Imaging Examinations:** CT angiography was performed, which was normal. CT Enterography revealed a small hyperdense lesion in the proximal ileum measuring approximately 0.8 mm in size that was enhanced in the arterial phase (Fig 1B).

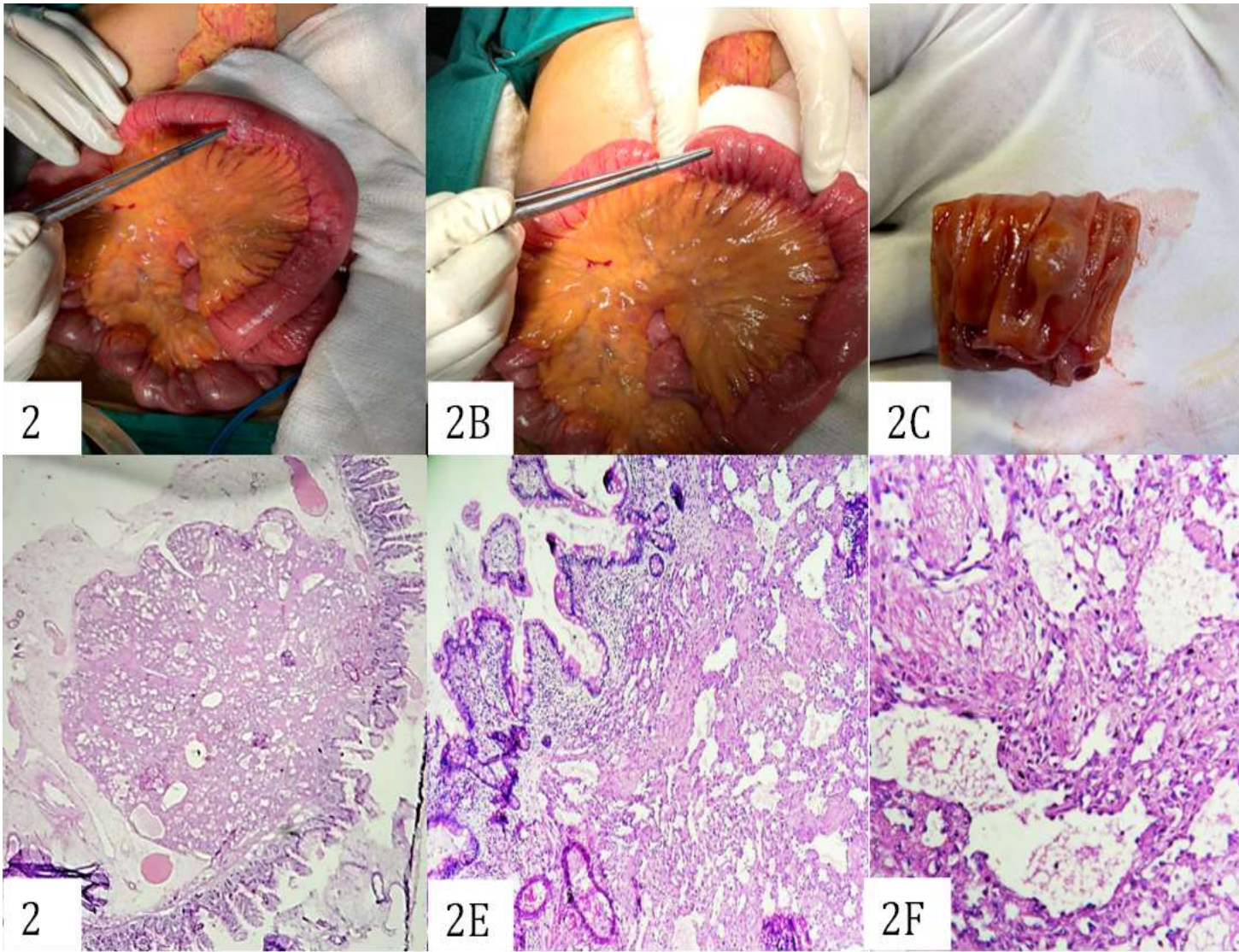
Subsequently, underwent wireless capsule endoscopy, which revealed multiple aphthous ulcers and a few erosions in the proximal ileum. The patient was further evaluated using double-balloon endoscopy (DBE) per rectal route, which showed a subepithelial lesion of size about 1x1cm with central umbilication without any active bleeding, approximately 180 cm proximal to the ileocecal (IC) valve. The rest of the visualized ileal mucosa and the intervening mucosa were normal (Fig-1C, D).



**Treatment:** The patient was scheduled for surgery, and a subepithelial mass of size 0.8 x 0.6 cm was seen 150 cm from the IC junction. Resection of the distal jejunal segment, 3 cm proximal and distal to the mass was done [Fig-2 A-C] along with primary anastomosis. The specimens were subjected to histological analysis.

**Histologic Examination:** A circumscribed mass was seen in the submucosa, composed of dilated vascular spaces lined by flattened endothelial cells within an eosinophilic matrix. Areas of congestion and hemorrhage were noted as focal chronic inflammation. Because there were more dilated vascular spaces than capillaries, a diagnosis of Cavernous Hemangioma of the distal jejunum was made. [Fig-2 D-F].

**Outcome and Follow Up:** Patient was followed up for 6 months and she is doing well without any further episodes of melena or a fall in hemoglobin.



## DISCUSSION

GI bleeding of uncertain cause after non-diagnostic esophagogastroduodenoscopy (EGD), colonoscopy, and barium small bowel follow-through is called Obscure Overt Gastrointestinal bleeding [3]. Small intestinal bleeding accounts for 5%-10% of all gastrointestinal bleeding [4]. Hence, persistent or recurrent bleedings not detected by routine endoscopy, including upper gastrointestinal endoscopy and colonoscopy [5,6]. Small intestinal hemangiomas are rare vascular malformations that can cause hemorrhage in the small intestine. They can occur in various segments of the small intestine but are more frequent in the jejunum and rarely in the ileum [6-8]. Pathologically, hemangiomas are classified into capillary, cavernous, and mixed types, with the capillary type being the most common [7,8]. Here, we present a case of a cavernous hemangioma in the upper ileum that caused recurrent gastrointestinal bleeding. Furthermore, small intestinal hemangiomas can originate from the mucosal, submucosal, muscularis propria, or even the serosal layer [9, 10]. Non-specific symptoms of the digestive system (33.3%) included abdominal pain, nausea, vomiting, bloating, abdominal mass, and loss of appetite. Our patient had melena as the main symptom, accompanied by anemia-related dizziness and fatigue. In our case, the patient presented with active bleeding, which was suspected to be caused by vascular malformations. Thus, we selected DBE for diagnosis. Subsequently, the patient underwent surgery for the removal of the lesion.

## CONCLUSION

Cavernous hemangioma of the small intestine is rare. Capsule Endoscopy (CE) and DBE can contribute to the identification of lesions, mostly submucosal masses, polypoids, or irregular nodules. A detailed treatment plan should be prepared for each patient to effectively manage the patients with variable risks. Although rare, intestinal hemangiomas should be included in the list of differential diagnoses of intestinal diseases with anemia and GI bleeding. Finally, more case reports or observational studies are needed to aid in diagnosis and treatment.

**Funding Statement:** This study was supported by the Department of Gastroenterology SDLD, IPGMER, SSKMH and Kolkata. This work was carried out under the research program IPGMER of West Bengal University of Health Sciences, Kolkata. Arun Kumar was supported by the Department of Gastroenterology, IPGMER Kolkata. This study received no specific grant from any funding agency.

**Conflict of Interest Declaration:** The authors declare that they have no affiliations with or involvement in any organization or entity with any financial interest in the subject matter or materials discussed in this manuscript.

## REFERENCES

1. Boyle L, Lack E (1993) Solitary cavernous hemangioma of small intestine. Case report and literature review. Arch Pathol Lab Med 117:939–41
2. Chen C-H, Jones J, McGowan P (2009) Profound iron deficiency anemia caused by a small-intestinal cavernous hemangioma. GastrointestEndosc 69:1392–3
3. Rao AB, Pence J, Mirkin DL. Diffuse infantile hemangiomatosis of the ileum presenting with multiple perforations: a case report and review of the literature. J Pediatr Surg 2010; 45: 1890-1892 [PMID: 20850639 DOI: 10.1016/j.jpedsurg.2010.05.019]
4. Editorial Board of Chinese Journal of Digestion. Consensus on diagnosis and treatment of small bowel bleeding (2018, Nanjing). Zhonghua Xiaohua Zazhi 2018; 38: 577-582 [DOI: 10.3760/cma.j.issn.0254-1432.2018.09.001]
5. Fan GW, Chen TH, Lin WP, Su MY, Sung CM, Hsu CM, Chi CT. Angiodysplasia and bleeding in the small intestine treated by balloon-assisted enteroscopy. J Dig Dis 2013; 14: 113-116 [PMID: 23216888 DOI: 10.1111/1751-2980.12021]
6. Ruiz AR Jr, Ginsberg AL. Giant mesenteric hemangioma with small intestinal involvement: an unusual cause of recurrent gastrointestinal bleed and review of gastrointestinal hemangiomas. Dig Dis Sci 1999; 44: 2545-2551 [PMID: 10630511 DOI: 10.1023/a:1026659710815]
7. Garvin PJ, Herrmann V, Kaminski DL, Willman VL. Benign and malignant tumors of the small intestine. Curr Probl Cancer 1979; 3: 1-46 [PMID: 391492 DOI: 10.1016/s0147-0272(79)80037-9]

8. Handra-Luca A, Montgomery E. Vascular malformations and hemangiolymphangiomas of the gastrointestinal tract: morphological features and clinical impact. *Int J Clin Exp Pathol* 2011; 4: 430-443 [PMID: 21738815]

9. Fu JX, Zou YN, Han ZH, Yu H, Wang XJ. Small bowel racemose hemangioma complicated with obstruction and chronic anemia: A case report and review of literature. *World J Gastroenterol* 2020; 26: 1674-1682 [PMID: 32327915 DOI: 10.3748/wjg.v26.i14.1674]

10. Dayang Anita Abdul Aziz et al ,Bleeding small bowel cavernous haemangioma following blunt trauma to the abdomen presenting as subacute intestinal obstruction in a child; *BMJ Case Rep*. 2011; 2011: bcr0820114672.

Published online 2011 Oct 7: doi: 10.1136/bcr.08.2011.4672