

## Granulomas in Female genital tract – A tertiary care rural setting experience.

Vivek Tubagere Gururaja<sup>1</sup>, Archana Shivamurthy<sup>2</sup>, Narayana Murthy G R<sup>1</sup>, Y.C. Spoorthy Rekha<sup>2</sup>, Ramkumar K.R<sup>3</sup>, Akkamahadevi C Hiremath<sup>4</sup>, Brunda Muniswamy<sup>4</sup>.

<sup>1</sup>Associate professor, Dept of pathology, Sri Madhusudhan Sai institute of medical sciences and research. (SMSIMSR)

<sup>2</sup>Assistant professor, Dept of pathology, SMSIMSR

<sup>3</sup>Professor, Dept of pathology, SMSIMSR

<sup>4</sup>Assistant professor, Dept of Obstetrics and Gynecology, SMSIMSR.

Corresponding author: Dr Narayana Murthy G R, Associate professor, Department of pathology, SMSIMSR.

### Abstract

Granulomas are chronic inflammatory conditions composed of activated macrophages along with T lymphocytes which can be accompanied by necrosis and multinucleate giant cells in some cases. Granulomatous conditions in the female genital tract are quite uncommon. The varying clinical presentations of disease causes a clinical dilemma which in turn cause a delay in diagnosis of the lesion. Tuberculosis, which is one of the most common cause the granulomatous lesions which commonly lead to infertility. A strong clinical suspicion is necessary for early diagnosis and treatment of the disorder.

**Keywords:** Granuloma, genital tract, tuberculosis.

**Abbreviations used:** FGT- Female Genital Tract, FGTTB- Female Genital Tract Tuberculosis, ADA- Adenosine Deaminase, CBNAAT- Cartridge Based Nucleic Acid Amplification testing, AFB- Acid Fast Bacilli.

### Introduction

Granulomas are chronic inflammatory lesions composed of activated macrophages along with T lymphocytes which can be accompanied by necrosis and multinucleate giant cells in a few cases. Granulomas are a result of persistence of the offending agents and activation of cell mediated hypersensitivity.<sup>1</sup>

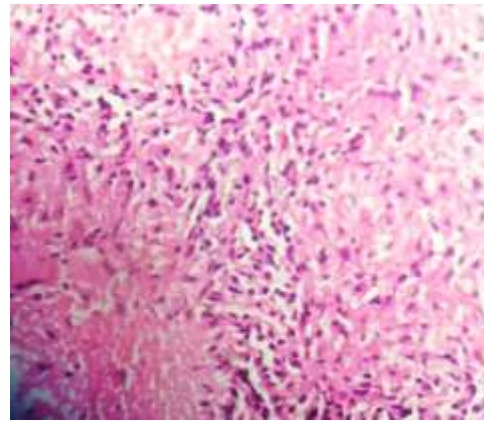
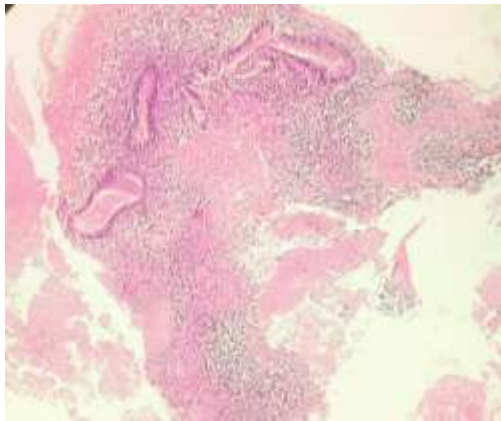
Granulomatous conditions in the female genital tract are quite uncommon. The causes can be infectious and non-infectious. The infectious causes are tuberculosis (TB), atypical mycobacteria, actinomycosis, fungal infections, cytomegalovirus, and parasitic infections. The non-infectious causes are surgical procedures/instrumentation, foreign bodies, systemic disorders such as sarcoidosis, giant cell arteritis and other systemic vasculitis, Crohn's disease, medications, lymphoma, and other neoplastic conditions.<sup>2,3</sup> In some cases, it is cryptogenic.<sup>2,3</sup> Granulomas in the ovary and fallopian tube are more frequently encountered. Very rarely malakoplakia of the fallopian tube causes granulomatous inflammation.<sup>4</sup> The Uterine granulomas are uncommon and are often incidental findings in histopathological examination.<sup>2</sup> Granulomatous lesions of the cervix is rare.<sup>5</sup>

Often maximum cases tend occur between 21–40 year age group.<sup>6</sup> Tuberculous salpingo-oophoritis is a significant cause of infertility in many patients. In India, the incidence of genital tuberculosis ranges from 1% to 19% in various regions, and can be as high as 26% among women seeking treatment for infertility.<sup>4,5</sup>

Here we report a series of 5 cases that presented with granulomas in the female genital tract over the last 2 years from 2024 -2025. A total of 4195 specimen was received from the OBG department, which make 0.11% of granulomas encountered in that period.

### Case 1

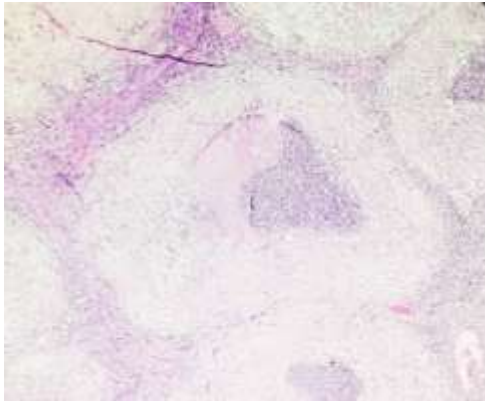
A 28-year-old nulligravida, who was Mantoux positive underwent endometrial biopsy. She was also a known case of hypothyroidism. The endometrial biopsy showed proliferative endometrial glands surrounded by stroma with few granulomas composed of epithelioid histiocytes, lymphocytes and multinucleate Langhan's giant cells. Focal areas of necrosis were also noted. CBNAAT (Cartridge based nuclei acid amplification test) was negative.



Case1: Pic1: Endometrial biopsy showing endometrial glands along with necrotising granuloma (H&E x20). Pic 2: Granulomas in the same case (H&E x40)

### Case 2:

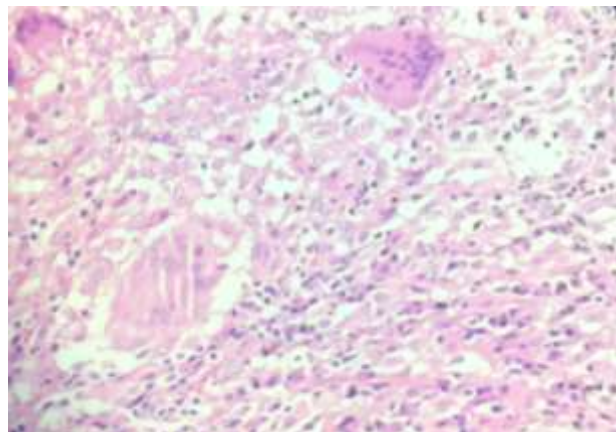
A 64-year-old female patient presented with pain abdomen in the left iliac fossa radiating to the back. She had history of vaginal hysterectomy. Radiology showed a left hydrosalpinx, for which bilateral salpingoophorectomy was done. The left fallopian tube showed dilated lumen along with granulation tissue. Paratubal tissue showed granulomas composed of central necrosis surrounded by epithelioid histiocytes, lymphocytes and a few multinucleate giant cells.



Case 2: Granulomatous lesion in the paratubal tissue (H&E x20)

### Case 3

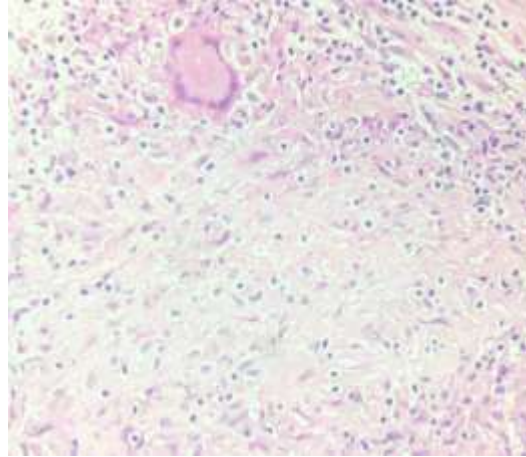
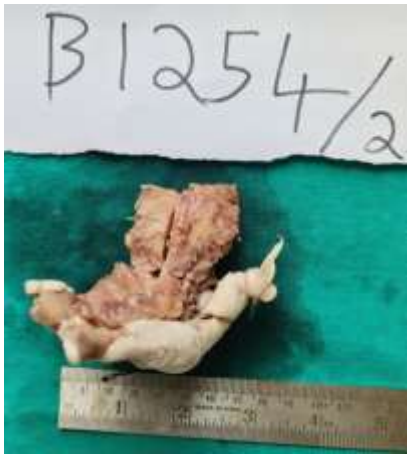A 38-year-old hypothyroid female with P2L2 with AUB(L) with ovarian cyst underwent total abdominal hysterectomy with left salpingo-oophorectomy and right salpingectomy. Section from the ovary reveal numerous epithelioid cell granulomas with central caseous necrosis along with multinucleated Langhan's giant cells. AFB done on the sections was positive for acid fast bacilli. The patient was further referred for anti-tubercular therapy.



Case 3: Pic 1: Grossly, the ovary shows grey white areas of necrosis. Pic 2: The histopathology of ovarian tissue showing granuloma (H&E x40)

### Case 4:

A 77-year-old female presented with vaginal prolapse for which she underwent hysterectomy. Sections from the surface of the uterus and myometrium showed numerous epithelioid cell granulomas with central caseous necrosis and Langhan's giant cells.



Case 4 : Pic 1: The gross photograph shows small white nodules over the uterus and myometrium. Pic 2: Uterine tissue showing granuloma with multinucleate giant cell. (H&E x40)

**Case 5:** A 46 year old patient presented with white discharge per vagina, pain abdomen and mass per vagina. She was diagnosed to have uterine prolapse. Routine endometrial biopsy performed prior to hysterectomy showed granulomas with necrosis, epithelioid histiocytes and multinucleate giant cells.

Table 1: The table shows the releavent clinical details, site and histopathology findings for each case in the present study.

## Discussion

Female genital tract granulomas can be localized or diffuse. While diffuse granulomas can be caused by infections, systemic disorders, or occasionally idiopathic causes, focused granulomas are more frequently the result of prior surgical intervention or instrumentation.<sup>2</sup>

CASES	Age in years	Clinical details / diagnosis	Site	Histopathology findings	AFB stain / Mantoux test
Case no 1	28	Nulligravida	Endometrium	Granulomatous inflammation	AFB: Negative, Mantoux test-positive
Case no 2	64	Left hydrosalpinx	Left fallopian tube	Granulomatous inflammation	AFB-Negative
Case no 3	38	Abnormal uterine bleeding with left ovarian cyst	Left ovary	Granulomatous inflammation	AFB-Positive
Case no 4	77	Prolapse	Uterus-Endomyometrium	Granulomatous inflammation	AFB-Negative
Case no 5	46	Prolapse	Endometrium	Granulomatous inflammation	AFB-Negative

Causes for granulomatous diseases of the cervix include TB, amoebiasis, sarcoidosis, leprosy, crohn's disease, actinomycosis, granuloma inguinale, schistosomiasis, foreign body reaction, Brucellosis, tularaemia, filarial, syphilis and silicosis.<sup>6,7</sup> Cervical tuberculosis accounts for 0.1-0.65% of all case of tuberculosis which correlates with the present study.<sup>6,8</sup> The cytopathologic examination of the cervix may reveal multinucleated Langhans type giant cells, histiocytes, epithelioid cells arranged in clusters, lymphocytes and fibroblasts simulating the appearance of the granuloma. There may be associated epithelial atypia from which dyskaryotic cells are shed.<sup>7,8</sup> Rarely, exclusion of tuberculosis or its distinction from a healing non-tuberculous chronic cervical lesion is quite difficult. Histopathological confirmation is needed in such cases.<sup>9</sup>

Uterine granulomas are rare. They are either focal, usually related to previous surgery, and do not require further action, or diffuse, representing isolated idiopathic reaction, but they warrant careful assessment to exclude infection or systemic granulomatous disease.<sup>10</sup>

Most of the times the gross features of tuberculous endometrium are near normal, most likely as a result of the monthly shedding. In cases of severe involvement, lesions that are ulcerative, granular, or fungating may be present, or intrauterine adhesions may completely obliterate the endometrial cavity. The macroscopic appearance can occasionally resemble cancer.<sup>2,8</sup> Although TB of the endometrium is similar to TB in other tissues, the classical features of caseation and late features such as fibrosis and calcification are rarely seen during

reproductive age.<sup>5,9</sup> The noncaseating granuloma, which is made up of lymphocytes, Langhans giant cells, and epithelioid cells, is the typical lesion in tuberculous endometritis. While present throughout the endometrium, these granulomata are more prevalent in the layers that are closer to the surface and fundus. On rare occasions, they pierce into the gland lumina, producing an acute inflammatory response and the formation of microabscesses. Granulomatous endometrial glands may not show secretory activity or they may get compressed, giving them a pseudo-adenomatous appearance. The cycle days 24-26 or the first 12 hours within the start of menstruation are typically the ideal times to detect the granulomatous lesions.<sup>5,7</sup>

Table 2: Comparison of the present study with incidence of granulomatous lesion other studies

	Present study	Aswini BR et al <sup>1</sup>	Saloni and Ekta ram <sup>6</sup>
Granulomatous endometritis	2	2	2
Myometrium with granulomatous inflammation	1	-	1
Granulomatous salphingitis	1	2	2
Tuberculous salpingo-oophoritis	1	2	-
Granulomatous cervicitis	-	1	-
Tuberculous vulval ulcer	-	1	-
Total	5	8	5

Granulomatous salphingo oophoritis, in surgical pathology practice, in developing countries may be seen in many conditions, most common being TB.<sup>7</sup> TB is one of the major causes of granulomatous inflammation of the female genital tract. TB of the fallopian tubes is the most common form of female genital tuberculosis (FGTB), occurring in about 90%–100% of cases.<sup>6</sup> It is a major cause of infertility, particularly in India, where it affects 3%–16% of infertile women. Clinically there is often bilateral tube damage associated with pelvic pain and infertility.<sup>6,7</sup>

Tuberculosis of the endometrium, an important cause of female infertility, occurs in about 50% to 80% of FGTB cases.<sup>5,6</sup> It presents in young women of reproductive age group and occurs as a complication of pelvic spread from the fallopian tubes. Common clinical features include infertility, abnormal uterine bleeding, and pelvic pain. FGTB affects 6–25% of women worldwide, with endometrium involvement being the second most common site after the fallopian tubes.<sup>3,7</sup>

Ovarian tuberculosis, a form of FGTB, occurs in approximately 20-30% of FGTB cases, with a few studies reporting higher estimates of up to 46%. It is primarily caused by hematogenous spread, leading to oophoritis, tubercle formation, and adhesions. It is a major underreported cause of infertility.<sup>5</sup>

Tuberculosis (TB) of the myometrium is rare, with an incidence of approximately 2.5% among cases of FGTB. It typically occurs as a result of direct extension from an infected endometrium, which is itself usually secondary to tubal or pulmonary TB. While fallopian tubes are involved in 90-100% of FGTB cases, the endometrium in 50-60%, the ovaries in 20-30% of cases, the myometrium is rarely affected.<sup>7,8</sup>

Tuberculosis of the cervix is a very rare entity, accounting for only 0.1% to 0.65% of all tuberculosis cases and 5% to 24% of female genital tuberculosis cases. It typically affects women of reproductive age, often presenting with symptoms like abnormal bleeding, infertility, or vaginal discharge.<sup>3,4</sup>

Other causes of granulomatous inflammation include a foreign body reaction to suture material introduced at a previous operative procedure, associated Crohn's disease, previous diathermy, a necrotizing reaction following previous surgery, endometriosis and bacterial tubo-ovarian abscess.<sup>6,8</sup> In few cases no cause could be attributable for the granulomatous inflammation and small cortical granulomas in the ovary are seen called as idiopathic granulomas.<sup>9</sup>

## Conclusion

Granulomatous lesions of the female genital tract although uncommon are one of the leading causes of female infertility. Due to varying clinical presentation, the clinical suspicion is difficult. Elimination of Tuberculosis which is one of the leading cause, is the need of the hour. Clinicopathological correlation, integration with biochemistry investigation (Fluid ADA levels) and microbiology investigations (AFB staining, CBNAAT, QuantiFERON gold) would aid in establishing a definitive diagnosis.

## References

1. B R Ashwini, Sebastian AT. Granulomas of the Female Genital Tract: A Case Series with Review of Literature. *International Journal of Life Sciences, Biotechnology and Pharma Research*. 2024 Jan 14;13(02):415–26.
2. Jindal A, Kapatia G, Rana MK, Goyal LD. Granulomas on cervical Pap smear: “Forget me not.” *CytoJournal* 2023;20:24.
3. Chandna M et al. *Int J Reprod Contracept Obstet Gynecol*. 2016 Aug;5(8):2875-2877.
4. Kesharwani H, Mohammad S, Pathak P. Tuberculosis in the Female Genital Tract. *Cureus*. 2022 Sep 2;14(9):e28708. doi: 10.7759/cureus.28708. PMID: 36204039; PMCID: PMC9527183.
5. Grace GA, Devaleenal DB, Natrajan M. Genital tuberculosis in females. *Indian J Med Res*. 2017;145(4):425-436.
6. Saloni, Rani E. Granulomatous mysteries of the female genital tract: A case series. *International Journal of Clinical Obstetrics and Gynaecology* 2026; 10(1): 94-98.
7. Alwani H, Subhankar S, Rao CM, Dash DP. Role of CBNAAT in extrapulmonary tuberculosis- an ongoing pilot study. *European respiratory journal*. 2019;54(63)
8. Kumari R, Vaishya V, Khanna G, Chauhan M, Sharma JB, Kriplani A. Tuberculosis of the cervix: An uncommon cause of vaginal discharge in a post-menopausal woman.

Natl Med J India. 2018 May-Jun;31(3):149-150. doi: 10.4103/0970-258X.255757. PMID: 31044761.

9. Cruz RP, Duarte MD, Bianchi AR, Casasola MP, Nunes PB, Rodini GP. Pelvic tuberculosis masses mimicking advanced ovarian cancer: case report and literature review. *Journal of Gynecologic Surgery*. 2021 Feb 1;37(1):52-5.
10. Sharma JB, Sharma E, Sharma S, Dharmendra S. Female genital tuberculosis: Revisited. *Indian J Med Res*. 2018 Dec;148(Suppl):S71-S83. doi: 10.4103/ijmr.IJMR\_648\_18. PMID: 30964083; PMCID: PMC6469382.