Journal of Cardiovascular Disease Research
ISSN: 0975-3583,0976-2833 VOL 10, ISSUE 4, 2019

ASSESSMENT OF THE EFFECT OF ADJUVANT PENTOXIFYLLINE THERAPY ON WOUND HEALING OUTCOMES IN PATIENTS UNDERGOING SURGICAL MANAGEMENT OF DIABETIC FOOT ULCERS

[1]Dr. Namgay Bhutia, [2]Dr. Manyala V.L.S Praveena, [3]Dr. Nadar Raju Athinarayanan

[1]Assistant Professor, Department of Pharmacology, Icare Institute of Medical Science and Research, Haldia, West Bengal, India
[2]Assistant Professor, Department of Physiology, Icare Institute of Medical Science & Research, Haldia, West Bengal, India
[3]Assistant Professor, Department of General Surgery, Icare Institute of Medical Sciences & Research, Haldia, West Bengal, India
Corresponding Author
Dr. Nadar Raju Athinarayanan

ABSTRACT

Background: Diabetic foot ulcers (DFUs) are a serious complication of diabetes, associated with delayed healing, infection, amputation, and increased healthcare costs. Impaired microcirculation, chronic inflammation, and poor tissue oxygenation contribute to their persistence. Pentoxifylline, a methylxanthine derivative with hemorheological and anti-inflammatory effects, may enhance tissue perfusion and promote ulcer healing as an adjunctive therapy.

Objectives: To evaluate the effect of adjuvant pentoxifylline therapy on wound healing outcomes in patients undergoing surgical management of diabetic foot ulcers.

Materials and Methods: A prospective comparative study was conducted among 80 patients with diabetic foot ulcers requiring surgical management. Patients were allocated into two groups: Group A (n=40) received standard surgical management along with oral pentoxifylline therapy, whereas Group B (n=40) received standard surgical management alone. Wound healing outcomes were assessed using ulcer size reduction, granulation tissue formation, wound closure rates, and duration of hospitalization over a 12-week follow-up period.

Results: Patients receiving pentoxifylline demonstrated significantly greater reduction in ulcer area (78.4% vs. 61.2%, $p<0.05$), earlier appearance of healthy granulation tissue (14.3 ± 4.2 days vs. 20.1 ± 5.6 days, $p<0.001$), higher complete wound healing rates (72.5% vs. 50.0%, $p=0.039$), and shorter hospital stay (11.6 ± 3.5 days vs. 15.2 ± 4.8 days, $p<0.01$). No serious drug-related adverse events were observed.

Conclusion: Adjunctive pentoxifylline therapy appears to enhance wound healing outcomes following surgical management of diabetic foot ulcers by improving granulation tissue

formation, reducing healing time, and increasing complete wound closure rates. Pentoxifylline may serve as a useful and safe adjunct in the multidisciplinary management of diabetic foot ulcers.

Keywords: Diabetic foot ulcer; Pentoxifylline; Wound healing; Surgical debridement; Granulation tissue; Diabetes mellitus; Ulcer healing outcomes.

INTRODUCTION

Diabetes mellitus is a major global public health concern affecting millions of individuals worldwide. One of its most debilitating complications is diabetic foot ulcer (DFU), which develops due to a complex interplay of peripheral neuropathy, peripheral arterial disease, impaired immunity, and microvascular dysfunction. Diabetic foot ulcers are associated with significant morbidity, recurrent hospital admissions, and increased risk of lower limb amputation. Despite advances in wound care and surgical management, delayed wound healing remains a major therapeutic challenge.[1] The global burden of diabetic foot disease continues to rise in parallel with the increasing prevalence of diabetes. It has been estimated that nearly 19–34% of individuals with diabetes may develop a foot ulcer during their lifetime. Furthermore, diabetic foot ulcers account for a substantial proportion of diabetes-related healthcare costs and are among the leading causes of non-traumatic lower-extremity amputations worldwide.[2] Successful healing of diabetic foot ulcers depends on adequate tissue perfusion, infection control, metabolic optimization, and appropriate wound care. Surgical interventions such as debridement, drainage of abscesses, and minor amputations are frequently required to remove necrotic tissue and establish a healthy wound bed. However, even after successful surgical management, impaired microcirculation and persistent inflammation may delay tissue repair and wound closure.[3] Pentoxifylline is a methylxanthine derivative that improves erythrocyte flexibility, decreases blood viscosity, enhances microvascular blood flow, and exhibits anti-inflammatory properties. These pharmacological effects may improve oxygen delivery to ischemic tissues and promote wound healing. Pentoxifylline has demonstrated beneficial effects in chronic venous ulcers and peripheral vascular disorders, generating interest in its potential role in diabetic wound management[4, 5]. Recent evidence suggests that modulation of microcirculatory dysfunction may contribute significantly to improved healing outcomes in diabetic foot ulcers. Pentoxifylline has been reported to reduce inflammatory cytokine activity, improve endothelial function, and enhance tissue perfusion, all of which are important components of the wound healing cascade.

These mechanisms provide a biological rationale for its use as an adjunct to conventional surgical treatment in patients with diabetic foot ulcers [6,7].

Although several studies have explored pharmacological strategies for enhancing diabetic wound healing, evidence regarding the effectiveness of pentoxifylline in surgically managed diabetic foot ulcers remains limited. The present study was therefore undertaken to assess the effect of adjuvant pentoxifylline therapy on wound healing outcomes in patients undergoing surgical management of diabetic foot ulcers.

MATERIALS AND METHODS

Study Design & Participants: This prospective comparative observational study was conducted in collaboration of Department of General Surgery with department of Pharmacology in a tertiary care teaching hospital, West Bengal, India, over a period of 18 months. A total of 80 patients with diabetic foot ulcers requiring surgical intervention were enrolled after obtaining written informed consent. Patients were allocated into two groups: Group A (n=40) received standard surgical management along with oral pentoxifylline therapy (400 mg three times daily), while Group B (n=40) received standard surgical management alone.

Treatment Protocol: Surgical management included debridement, incision and drainage of abscesses, and minor amputations whenever indicated. In addition, all patients received standard diabetic foot care, including glycemic control, culture-guided antibiotic therapy, off-loading measures, wound dressing, and regular clinical assessment. Baseline demographic and clinical variables including age, gender, duration of diabetes, HbA1c levels, ulcer duration, Wagner grade, and presence of peripheral neuropathy were recorded.

Outcome Assessment and Follow-up: Patients were followed for a period of 12 weeks. Wound healing outcomes were assessed in terms of percentage reduction in ulcer area, time to appearance of healthy granulation tissue, complete wound healing rate, duration of hospital stay, requirement of repeat surgical procedures, and treatment-related adverse events. Complete wound healing was defined as complete epithelialization of the ulcer without discharge or requirement of further dressing.

Inclusion Criteria

- Patients aged ≥18 years with type 1 or type 2 diabetes mellitus.
- Patients with Wagner Grade I–III diabetic foot ulcers requiring surgical management.
- Patients who provided written informed consent.

- Patients available for follow-up during the study period.

Exclusion Criteria

- Wagner Grade IV or V diabetic foot ulcers.
- Critical limb ischemia requiring vascular intervention.
- Known hypersensitivity to pentoxifylline.
- Severe hepatic or renal impairment.
- Patients on immunosuppressive therapy.
- Active malignancy or severe systemic infection.

Statistical Analysis: Data were analyzed using Statistical Package for Social Sciences (SPSS) version 26.0. Continuous variables were expressed as mean ± standard deviation (SD), while categorical variables were presented as frequencies and percentages. Comparisons between the two study groups were performed using the independent Student's t-test and Chi-square test or Fisher's exact test. A p-value of less than 0.05 was considered statistically significant.

RESULTS

Eighty patients undergoing surgical management for diabetic foot ulcers were analyzed in the present study. The baseline demographic and clinical characteristics were comparable between the two groups. No statistically significant differences were observed with respect to age, duration of diabetes, glycemic control, or prevalence of peripheral neuropathy ($p>0.05$).

Table 1: Baseline Demographic and Clinical Characteristics of the Study Participants

Variable	Group A (Pentoxifylline) (n=40)	Group B (Control) (n=40)	p-value
Age (years)	57.8 ± 9.4	58.6 ± 10.1	0.714
Male, n (%)	28 (70.0)	26 (65.0)	-
Duration of Diabetes (years)	10.4 ± 4.8	9.9 ± 5.1	0.651
HbA1c (%)	8.6 ± 1.2	8.8 ± 1.3	0.481
Peripheral Neuropathy, n (%)	24 (60.0)	22 (55.0)	0.648

Both groups demonstrated similar ulcer characteristics at baseline. There were no significant differences in ulcer duration, ulcer size, or Wagner grading distribution, indicating homogeneity between the study groups before treatment.

Table 2: Ulcer Characteristics at Baseline

Variable	Group A (n=40)	Group B (n=40)	p-value
Ulcer Duration (weeks)	5.8 ± 2.3	6.1 ± 2.6	0.592
Ulcer Area (cm^2)	8.7 ± 3.5	8.4 ± 3.2	0.689
Wagner Grade I, n (%)	12 (30.0)	13 (32.5)	0.810
Wagner Grade II, n (%)	18 (45.0)	17 (42.5)	
Wagner Grade III, n (%)	10 (25.0)	10 (25.0)	

Patients receiving adjuvant pentoxifylline therapy showed significantly greater reduction in ulcer area, earlier appearance of healthy granulation tissue, higher complete wound healing rates, and shorter hospital stay compared to the control group. These findings suggest a beneficial effect of pentoxifylline on wound healing outcomes.

Table 3: Comparison of Wound Healing Outcomes

Outcome Variable	Group A (n=40)	Group B (n=40)	p-value
Reduction in Ulcer Area (%)	78.4 ± 18.2	61.2 ± 20.4	0.001*
Time to Healthy Granulation Tissue (days)	14.3 ± 4.2	20.1 ± 5.6	<0.001*
Complete Wound Healing, n (%)	29 (72.5)	20 (50.0)	-
Hospital Stay (days)	11.6 ± 3.5	15.2 ± 4.8	0.002*

***Statistically significant**

Although the differences were not statistically significant, patients in the pentoxifylline group demonstrated lower rates of repeat debridement, recurrent wound infection, and minor amputations. Adverse effects associated with pentoxifylline were mild and did not necessitate treatment discontinuation.

Table 4: Follow-up Outcomes and Complications

Variable	Group A (n=40)	Group B (n=40)	p-value
Repeat Debridement Required, n (%)	5 (12.5)	11 (27.5)	>0.05
Minor Amputation During Follow-up, n (%)	2 (5.0)	5 (12.5)	
Wound Infection Recurrence, n (%)	4 (10.0)	9 (22.5)	
Drug-related Adverse Events, n (%)	3 (7.5)	0	

Patients receiving adjuvant pentoxifylline therapy demonstrated significantly earlier appearance of healthy granulation tissue compared to the control group (14.3 ± 4.2 days vs. 20.1 ± 5.6 days), indicating enhanced wound healing and tissue repair.

Figure 1: Comparison of Time to Appearance of Healthy Granulation Tissue between Study Groups

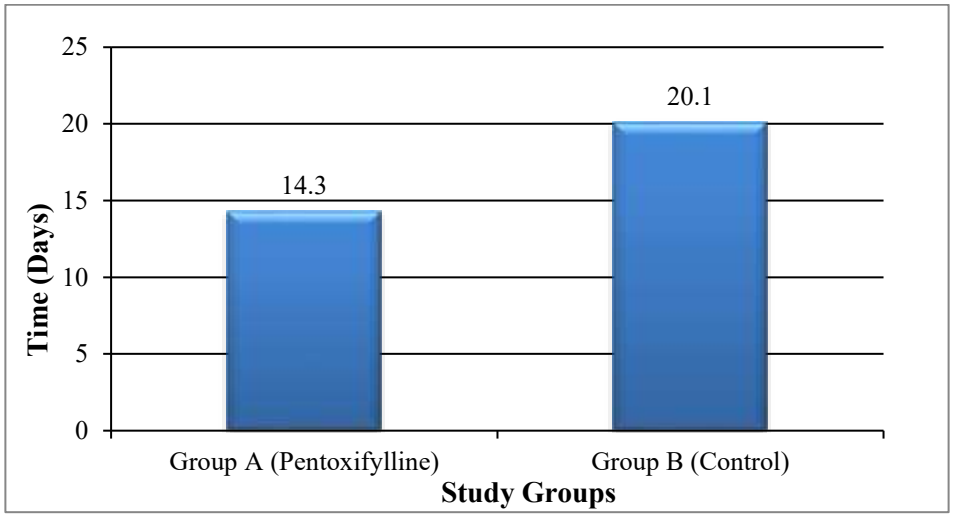

Figure 2: Complete Wound Healing According to Wagner Grade

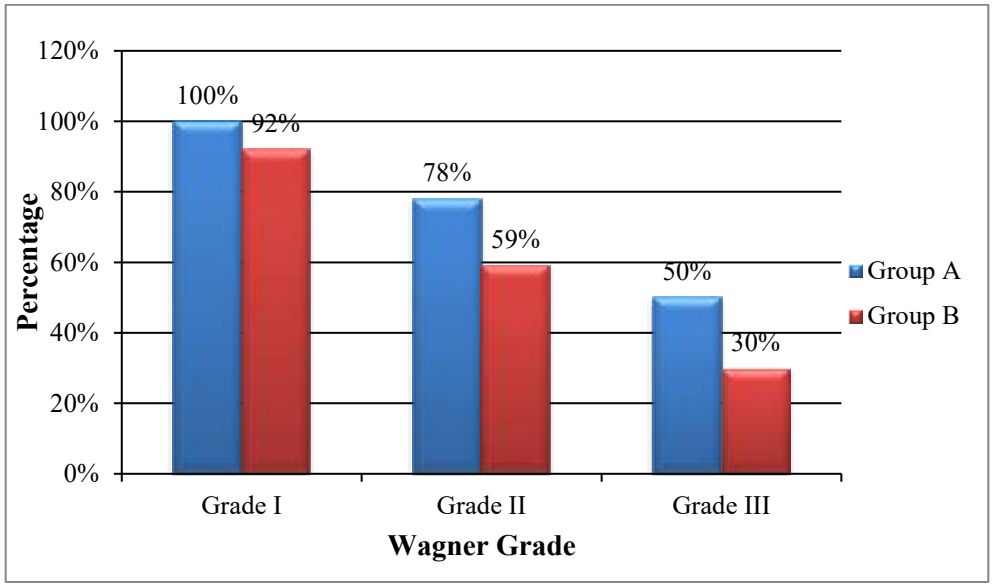

Patients treated with pentoxifylline showed higher complete wound healing rates across all Wagner grades compared to the control group. The improvement was more pronounced in Grade II and Grade III ulcers, indicating a beneficial effect of pentoxifylline on wound healing outcomes.

DISCUSSION

Delayed wound healing in diabetic foot ulcers is multifactorial and is largely attributed to impaired microcirculation, endothelial dysfunction, persistent inflammation, and reduced tissue oxygenation. Pentoxifylline improves erythrocyte deformability, reduces blood viscosity, and

enhances microvascular blood flow, thereby facilitating oxygen and nutrient delivery to ischemic tissues. The significantly faster appearance of healthy granulation tissue observed in the present study may be explained by these beneficial rheological and microcirculatory effects. Similar mechanisms have been highlighted in contemporary diabetic wound management literature.[8]

In the present study, the percentage reduction in ulcer area was significantly greater in the pentoxifylline group compared to the control group. Reduction in wound size is widely regarded as an important indicator of subsequent wound healing and successful ulcer closure. Improved tissue perfusion and modulation of inflammatory pathways may contribute to accelerated wound contraction and epithelialization. Previous investigations evaluating adjunctive therapies for diabetic foot ulcers have similarly reported that interventions targeting microvascular dysfunction can improve healing outcomes and reduce ulcer persistence.[9]

A notable observation in this study was the significantly higher complete wound healing rate among patients receiving pentoxifylline therapy. This finding supports the hypothesis that optimization of local tissue perfusion can substantially influence wound repair. The International Working Group on the Diabetic Foot emphasizes the importance of improving vascular supply and addressing factors that impair tissue healing as key components of successful ulcer management.[10] The present findings are therefore consistent with current evidence-based approaches for diabetic foot care.

Hospital stay was significantly shorter in the pentoxifylline-treated group. Prolonged hospitalization in diabetic foot patients contributes substantially to healthcare expenditure and negatively affects quality of life. Earlier wound stabilization and improved healing may explain the reduced duration of admission observed in the present study. Similar observations have been reported in studies evaluating multidisciplinary strategies for diabetic foot management, where enhanced healing translated into reduced healthcare utilization and better patient outcomes.[11]

Although lower rates of repeat debridement, recurrent infection, and minor amputations were observed in the pentoxifylline group, these differences did not reach statistical significance. Nevertheless, the trend toward improved clinical outcomes suggests a potential protective effect of pentoxifylline. Larger multicenter studies with longer follow-up periods may provide further evidence regarding its role in reducing diabetes-related lower extremity complications.[12]

The safety profile of pentoxifylline was satisfactory in the present study. Only a small proportion of patients experienced mild adverse effects, and none required discontinuation of therapy. This

finding is consistent with previous evidence indicating that adjunctive therapies used in diabetic foot ulcer management are generally well tolerated and may contribute to improved wound healing outcomes.[13,14]

The strengths of the present study include prospective data collection, uniform surgical management protocols, and systematic follow-up of wound healing outcomes. However, certain limitations should be acknowledged. The study was conducted at a single center with a relatively small sample size, which may limit generalizability. In addition, longer follow-up would be useful to evaluate ulcer recurrence and long-term limb preservation outcomes. Nevertheless, the present findings add to the growing body of evidence suggesting a potential role for pentoxifylline in diabetic foot ulcer management.

CONCLUSION

Adjunctive pentoxifylline therapy significantly improved wound healing outcomes in patients undergoing surgical management of diabetic foot ulcers. Patients receiving pentoxifylline demonstrated greater reduction in ulcer area, earlier granulation tissue formation, higher complete wound healing rates, and shorter hospital stay compared with standard treatment alone. The therapy was well tolerated and associated with minimal adverse effects. Incorporation of pentoxifylline into the multidisciplinary treatment approach for diabetic foot ulcers may enhance healing and improve clinical outcomes. Further large-scale randomized studies are warranted to validate these findings and establish definitive treatment recommendations.

REFERENCES

1. Armstrong DG, Boulton AJM, Bus SA. Diabetic Foot Ulcers and Their Recurrence. N Engl J Med. 2017 Jun 15;376(24):2367-2375. doi: 10.1056/NEJMra1615439.
2. Zhang P, Lu J, Jing Y, Tang S, Zhu D, Bi Y. Global epidemiology of diabetic foot ulceration: a systematic review and meta-analysis. Ann Med. 2017 Mar;49(2):106-116. doi: 10.1080/07853890.2016.1231932.
3. Schaper NC, van Netten JJ, Apelqvist J, Bus SA, Hinchliffe RJ, Lipsky BA; IWGDF Editorial Board. Practical Guidelines on the prevention and management of diabetic foot disease (IWGDF 2019 update). Diabetes Metab Res Rev. 2020 Mar;36 Suppl 1:e3266. doi: 10.1002/dmrr.3266.
4. Okonkwo UA, DiPietro LA. Diabetes and Wound Angiogenesis. Int J Mol Sci. 2017 Jul 3;18(7):1419. doi: 10.3390/ijms18071419.

5. Everett E, Mathioudakis N. Update on management of diabetic foot ulcers. Ann N Y Acad Sci. 2018 Jan;1411(1):153-165. doi: 10.1111/nyas.13569.
6. Bus SA, Sacco ICN, Monteiro-Soares M, Raspovic A, Paton J, Rasmussen A, Lavery LA, van Netten JJ. Guidelines on the prevention of foot ulcers in persons with diabetes (IWGDF 2023 update). Diabetes Metab Res Rev. 2024 Mar;40(3):e3651. doi: 10.1002/dmrr.3651.
7. Pouget C, Dunyach-Remy C, Pantel A, Boutet-Dubois A, Schuldiner S, Sotto A, Lavigne JP, Loubet P. Alternative Approaches for the Management of Diabetic Foot Ulcers. Front Microbiol. 2021 Oct 5;12:747618. doi: 10.3389/fmicb.2021.747618.
8. Mponponsuo K, Sibbald RG, Somayaji R. A Comprehensive Review of the Pathogenesis, Diagnosis, and Management of Diabetic Foot Infections. Adv Skin Wound Care. 2021 Nov 1;34(11):574-581. doi: 10.1097/01.ASW.0000791876.10485.d4.
9. Soyoye DO, Abiodun OO, Ikem RT, Kolawole BA, Akintomide AO. Diabetes and peripheral artery disease: A review. World J Diabetes. 2021 Jun 15;12(6):827-838. doi: 10.4239/wjd.v12.i6.827.
10. Schneider C, Stratman S, Kirsner RS. Lower Extremity Ulcers. Med Clin North Am. 2021 Jul;105(4):663-679. doi: 10.1016/j.mcna.2021.04.006.
11. Urso B, Ghias M, John A, Khachemoune A. Neuropathic ulcers: a focused review. Int J Dermatol. 2021 Oct;60(10):e383-e389. doi: 10.1111/ijd.15362.
12. Lazzarini PA, Pacella RE, Armstrong DG, van Netten JJ. Diabetes-related lower-extremity complications are a leading cause of the global burden of disability. Diabet Med. 2018 May 23. doi: 10.1111/dme.13680.
13. Elraiyah T, Tsapas A, Prutsky G, Domecq JP, Hasan R, Firwana B, Nabhan M, Prokop L, Hingorani A, Claus PL, Steinkraus LW, Murad MH. A systematic review and meta-analysis of adjunctive therapies in diabetic foot ulcers. J Vasc Surg. 2016 Feb;63(2 Suppl):46S-58S.e1-2. doi: 10.1016/j.jvs.2015.10.007.
14. Dawi J, Tumanyan K, Tomas K, Misakyan Y, Gargaloyan A, Gonzalez E, Hammi M, Tomas S, Venketaraman V. Diabetic Foot Ulcers: Pathophysiology, Immune Dysregulation, and Emerging Therapeutic Strategies. Biomedicines. 2025 Apr 29;13(5):1076. doi: 10.3390/biomedicines13051076.