

Ruptured right sinus of Valsalva into main pulmonary artery

Prashant N. Mohite, Manoj K. Rohit¹, Shyam K. Thingnam

Departments of Cardiothoracic and Vascular Surgery, ¹Cardiology, Post Graduation Institute of Medical Education and Research, Chandigarh, India

Address for correspondence: Mr. Prashant N. Mohite, Room: 006, Parkwood House, Harefield Hospital, Middlesex, UB9 6JH. E-mail: drprashantis@rediffmail.com

ABSTRACT

A young adult who presented with congestive heart failure was found to have ruptured aneurysm of right sinus of Valsalva. The aneurysm was opening into the main pulmonary artery, which was demonstrated well by transthoracic and transesophageal echocardiography and confirmed by cardiac catheterization. Aneurysm was repaired followed by aortic valve replacement.

Key words: Ruptured sinus of Valsalva aneurysm, sinus of Valsalva aneurysm, pulmonary artery

INTRODUCTION

Sinus of Valsalva is a rare congenital anomaly. If unruptured, the aneurysm remains asymptomatic, while ruptured sinus of Valsalva presents as heart failure and other variable features depending upon the chamber in which the aneurysm ruptures.

CASE REPORT

A 30-year-old opium addict truck driver developed progressive breathlessness on exertion, palpitations and swelling over legs since 3 months and revealed raised jugular venous pulse, hepatomegaly, ascites, left parasternal heave and systolo-diastolic machinery murmur on examination. Echocardiography showed the aneurysm arising from the right sinus of Valsalva rupturing into the pulmonary artery [Figure 1] with severe aortic regurgitation. Trans-esophageal echocardiography confirmed the ruptured right sinus aneurysm [Figure 2

and Video 1]. Cardiac catheterization showed step-up of oxygen saturation from right ventricle outlet (57%) to main pulmonary artery (88%), suggestive of significant left-to-right shunt above the level of pulmonary valve. Aortic cine-angiography clearly showed the dye from aorta entering into the aneurysm of right sinus and shunted thereafter into the main pulmonary artery [Figure 3].

The patient was stabilized on medical therapy with intravenous Furosemide and Enalapril for 2 weeks. He was then taken for surgery electively and approached through median sternotomy. Aorta and pulmonary arteries were opened after putting patient on cardiopulmonary bypass. An aneurysm was seen arising from the right sinus of Valsalva and a probe could be passed from right sinus into the pulmonary artery through the aneurysmal sac. Polytetrafluoroethylene (PTFE) patch closure of communication between ruptured sinus and the main pulmonary artery was performed, following which pericardial patch augmentation of pulmonary artery was done. Aortic valve was replaced with 23-mm St. Jude prosthesis and the dilated segment of aortic root was plicated. The patient was relieved of the symptoms of heart failure within 3 weeks of operation, and echocardiography at the 1-year follow-up showed absence of shunt and aortic incompetence.

Access this article online	
Quick Response Code:	Website: www.jcdronline.com
	DOI: 10.4103/0975-3583.95368

Video available at www.jcdronline.com

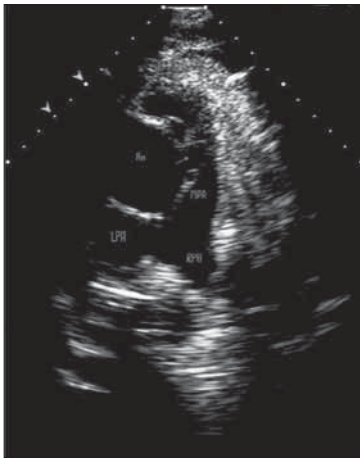

Figure 1: Trans-thoracic echo showing connection between aorta and pulmonary artery (Ao: Aorta; MPA: Main pulmonary artery; LPA: Left pulmonary artery; Arrow - ruptured right sinus)

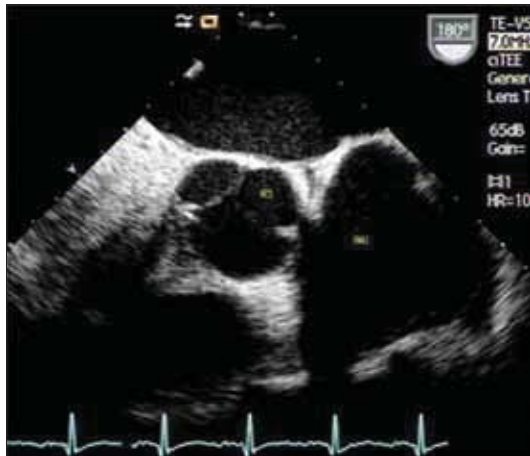

Figure 2: Trans-esophageal echo showing RCS aneurysm (RCS: Right coronary sinus; ANU: Aneurysm of sinus)

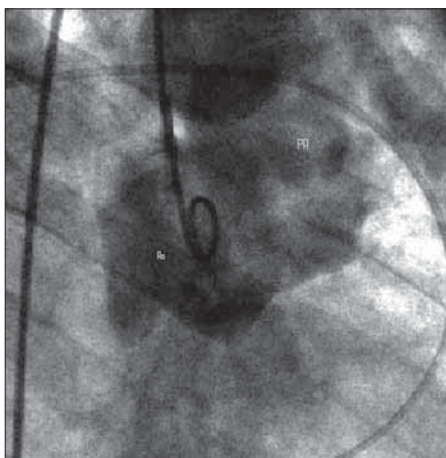


Figure 3: Aortic cineangiography showing aorta, aneurysm and pulmonary artery (Ao: Aorta; PA: Pulmonary artery)

DISCUSSION

Aneurysm of sinus of Valsalva is a rare entity. Congenital

variety is due the failure of the fusion between the aortic media and the heart at the level of the annulus fibrosus of the aortic valve.^[1] The acquired variety of sinus of Valsalva aneurysm is seen in connective tissue disorders like Marfan's syndrome, Behcet's disease or aortic valve endocarditis and, rarely, chest trauma. The unruptured aneurysm is usually silent but may produce symptoms due to right ventricular outflow tract obstruction or become the source of emboli. It can rupture into any cardiac chamber, commonly the right ventricle or right atrium. Cases have been reported with rupture into the left ventricle, the interventricular septum, the pulmonary artery and the pericardial space. Rupture into right side of heart causes left-to-right shunting of blood while rupture into left side causes picture similar to aortic regurgitation, both culminating in heart failure. In the present case, the aneurysm of right sinus had ruptured into the pulmonary artery. About eight such cases have been reported in the literature to the best of our knowledge, but like the present case, were not demonstrated with echocardiographic illustrations. Heilman KJ *et al.*, were the first to report ruptured sinus of Valsalva aneurysm into pulmonary artery.^[2] Scagliotti *et al.*, have reported left sinus of Valsalva aneurysm with aortopulmonary tunnel and stressed upon differentiating ruptured sinus of Valsalva from coronary artery fistula to pulmonary artery.^[3]

The two-dimensional echocardiography is a first choice of investigation, which demonstrates the location, structure and relations of aneurysm of Valsalva sinus and gives precise information about the magnitude of shunt in case of ruptured aneurysm.^[4] Trans-esophageal echocardiography may be used for more detailed diagnosis of anatomy, point of rupture and shunt blood flow. Coronary angiography is useful to detect associated coronary anomalies and level and quantification of shunt. The patient can be treated symptomatically for heart failure, but surgery remains the gold standard for the treatment of ruptured sinus of Valsalva. Unlike other chambers of heart, the rupture into pulmonary artery requires repair of both aorta as well as pulmonary artery in view of preserving the integrity and prevention of stenosis or incompetence of pulmonary artery.

ACKNOWLEDGMENT

Authors are not funded by any external source.

REFERENCES

1. Edwards JE, Burchell HB. The pathological anatomy of the deficiencies between the aortic root and the heart including aortic sinus aneurysms.

Thorax 1957;12:125-39.

2. Heilman KJ 3rd, Groves BM, Campbell D, Blount SG Jr. Rupture of left sinus of Valsalva aneurysm into the pulmonary artery. J Am Coll Cardiol 1985;5:1005-7.
3. Scagliotti D, Fisher EA, Deal BJ, Gordon D, Chomka EV, Brundage BH. Congenital aneurysm of sinus of valsalva with an aortopulmonary tunnel. J Am Coll Cardiol 1986;7:443-5.
4. Meier JH, Seward JB, Miller FA Jr, Oh JK, Enriquez-Sarano M. Aneurysms in the left ventricular outflow tract: Clinical presentation, causes,

and echocardiographic features. J Am Soc Echocardiogr 1998; 11:729-45.

How to cite this article: Mohite PN, Rohit MK, Thingnam SK. Ruptured right sinus of Valsalva into main pulmonary artery. J Cardiovasc Dis Res 2012;3:132-4.

Source of Support: Nil, **Conflict of Interest:** None declared.

Announcement

iPhone App



A free application to browse and search the journal's content is now available for iPhone/iPad. The application provides "Table of Contents" of the latest issues, which are stored on the device for future offline browsing. Internet connection is required to access the back issues and search facility. The application is Compatible with iPhone, iPod touch, and iPad and Requires iOS 3.1 or later. The application can be downloaded from <http://itunes.apple.com/us/app/medknow-journals/id458064375?ls=1&mt=8>. For suggestions and comments do write back to us.