



## Clinical case report based study

## A special case of Wellens' syndrome

Alimujiang Abulaiti\*, Renaguli Aini, Hiarong Xu, Zejun Song

Cardiology Department, Hospital of Armed Police Force of Xinjiang, No 669 South Nanchang Road, Urumqi, Xinjiang, China

## ARTICLE INFO

## Article history:

Received 4 September 2012

Accepted 7 November 2012

Available online 27 February 2013

## Keywords:

Electrocardiography

Wellens syndrome

Coronary artery spasm

## ABSTRACT

Wellens' syndrome is a pattern of electrocardiographic T-wave changes associated with critical stenosis of proximal left anterior descending artery (LAD). T-waves abnormalities were found in precordial leads, especially in V<sub>2</sub>–V<sub>3</sub> during pain-free periods, and ECG obtained during episodes of pain demonstrates upright T-waves with possible elevated or isoelectric ST segments. Early recognition and appropriate intervention carries significant diagnostic and prognostic value. We reported a case of Wellens' syndrome with different etiology and prognosis. Although the ECG showed typical T-wave changes in V<sub>2</sub>–V<sub>5</sub> leads, patient's coronary angiography revealed moderate stenosis in proximal LAD, and coronary artery spasm was suggested. Unlike the classic Wellens' syndrome, which needs aggressive coronary intervention, our patient fared well with conservative medical therapy (diltiazem and nitrates) and showed favorable prognosis.

Copyright © 2013, SciBioMed.Org, Published by Reed Elsevier India Pvt. Ltd. All rights reserved.

## 1. Introduction

In 1982, Wellens et al described a characteristic ECG pattern of T-waves in the precordial leads that were associated with a critical stenosis (>90%) of the proximal left anterior descending (LAD) coronary artery.<sup>1</sup> Syndrome criteria include T-wave changes in precordial leads plus a history of anginal chest pain without marked serum marker abnormalities and Q-waves. If left untreated, most of the patients will develop into extensive anterior infarction, even death. However, as our case illustrated, there might be other causes of these distinctive ECG changes. Spasm-related angina sometimes shows similar ECG changes, and calcium channel blockers and long-acting nitrates, not the  $\beta$ -blockers and coronary interventions, are the mainstream of the therapy.

## 2. Case report

A 47-year-old male with previous history of poorly controlled hypertension and diabetes, presented with intermittent heart pain for 2 months. His pain had occurred mostly in the morning and at night, associated with diaphoresis, persisting up to 20–30 min, radiating to scapulas and relieving spontaneously. He had a 20-pack-year smoking history, and his physical examination was normal. Laboratory tests: complete blood cell count, electrolytes, and renal functions are normal. Cardiac enzymes: CPK 266 U/L, CPK-MB 27 U/L, cTnT 0.23 ng/ml, blood sugar 292 mg/dl, TG

190 mg/dl, TC 154 mg/dl, LDL-C 76.5 mg/dl. Initial ECG: Sinus rhythm and inverted T-wave in V<sub>2</sub>–V<sub>5</sub> leads [Fig. 1]. He was diagnosed as "Acute coronary syndrome, Wellens' syndrome, hypertension, and type 2 diabetes," and given dual anti-platelet (oral aspirin and clopidogrel), anti-thrombosis (subcutaneous low-molecular-weight heparin), blood pressure (fusinopril), and blood sugar control (subcutaneous insulin), and oral statin (zocor) therapy. At 7 am next morning, his pain recurred again, and ECG revealed ST elevation in V<sub>1</sub>–V<sub>4</sub> leads [Fig. 2]. The pain relieved 2-min later with 0.5 mg sublingual nitroglycerin, and ST returned to normal [Fig. 3]; emergency cardiac biomarkers were negative. He was transferred to catheter lab immediately. Coronary angiography showed moderate stenosis (50%) in proximal LAD [Fig. 4]. Coronary spasm was considered; oral nitrates and diltiazem were added. He was stable for 10 days, and ECG at discharge showed sinus rhythm with upward T-waves in V<sub>1</sub>–V<sub>4</sub> leads. He has been in constant follow-up and not experienced angina again.

## 3. Discussions

Wellens' syndrome is characterized by symmetric T-wave inversion or biphasic T-wave in the precordial leads, typically caused by a critical stenosis in the proximal LAD (>90%). These patients are at high risk for the development of extensive myocardial infarction of the anterior wall and require immediate coronary angiography and revascularization therapies such as percutaneous coronary intervention (PCI) or coronary artery bypass grafting (CABG).<sup>1,2</sup>

\* Corresponding author.

E-mail address: [almj924@tom.com](mailto:almj924@tom.com) (A. Abulaiti).



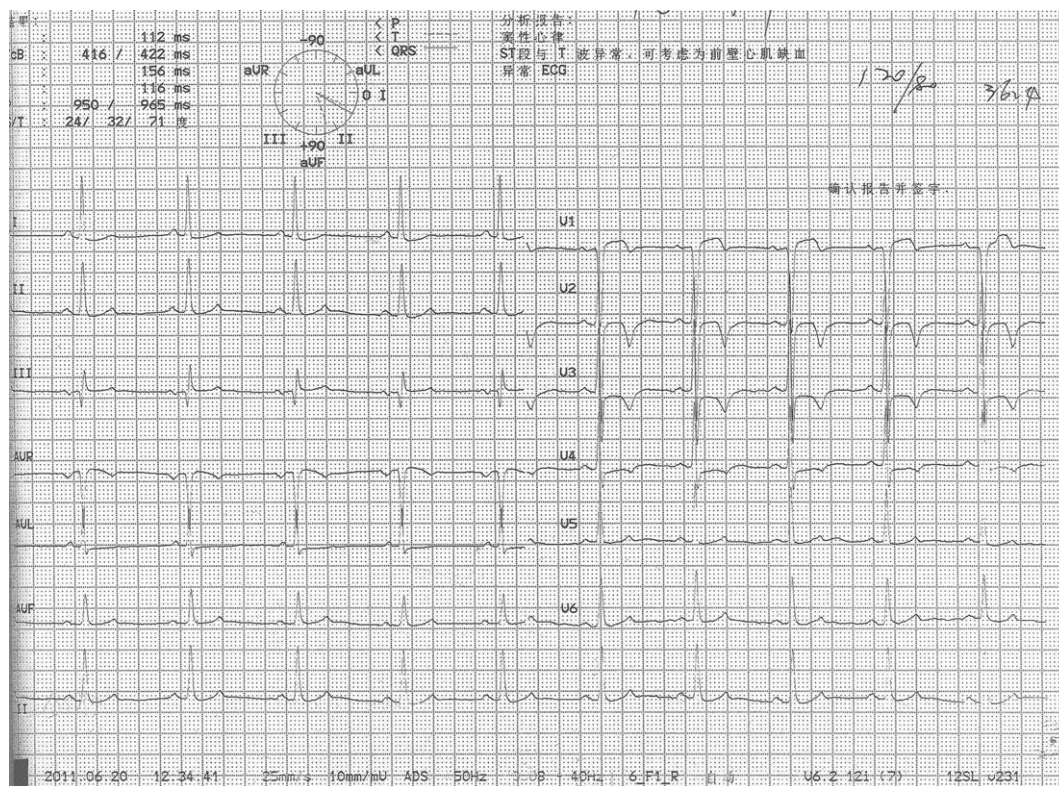


Fig. 1. Initial ECG tracing (pain-free period).

Wellens' syndrome is diagnosed based on the classic T-wave findings seen on an ECG taken when the patient is pain-free. These T-wave changes represent stunning and reperfusion of the

myocardium.<sup>3</sup> Complete or near-complete occlusion of LAD causes severe myocardial ischemia and angina. When coronary flow is restored, reperfusion injury related repolarization abnormalities

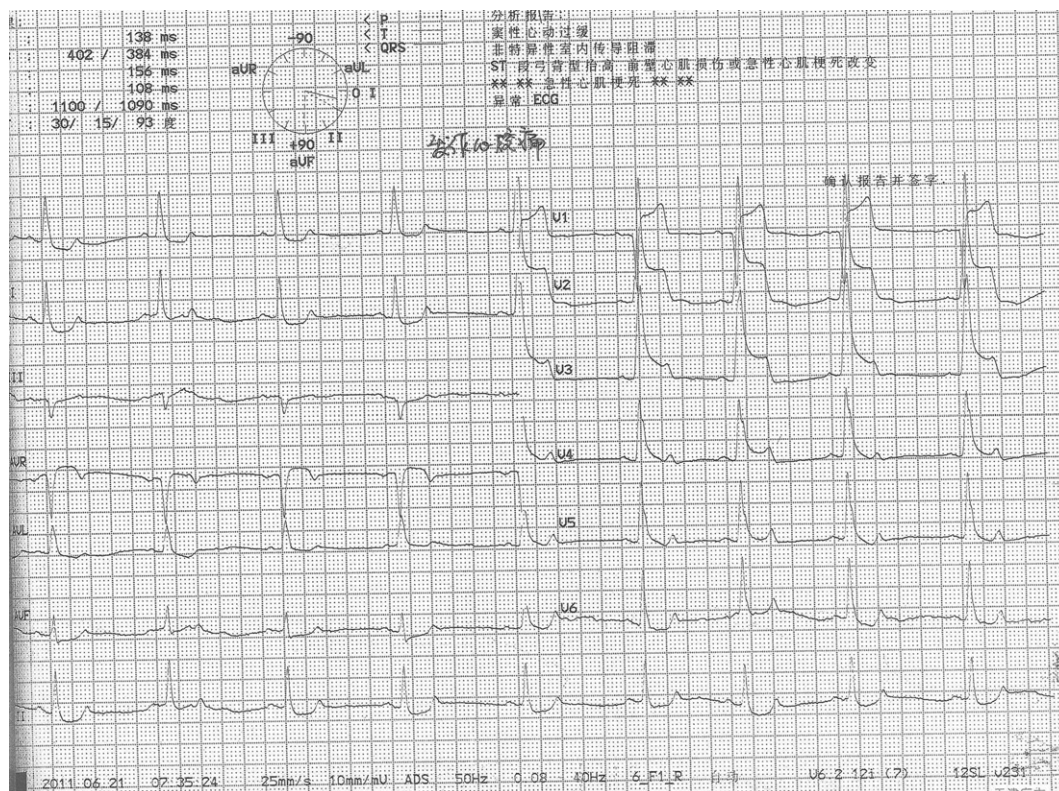


Fig. 2. ECG when chest pain recurred.



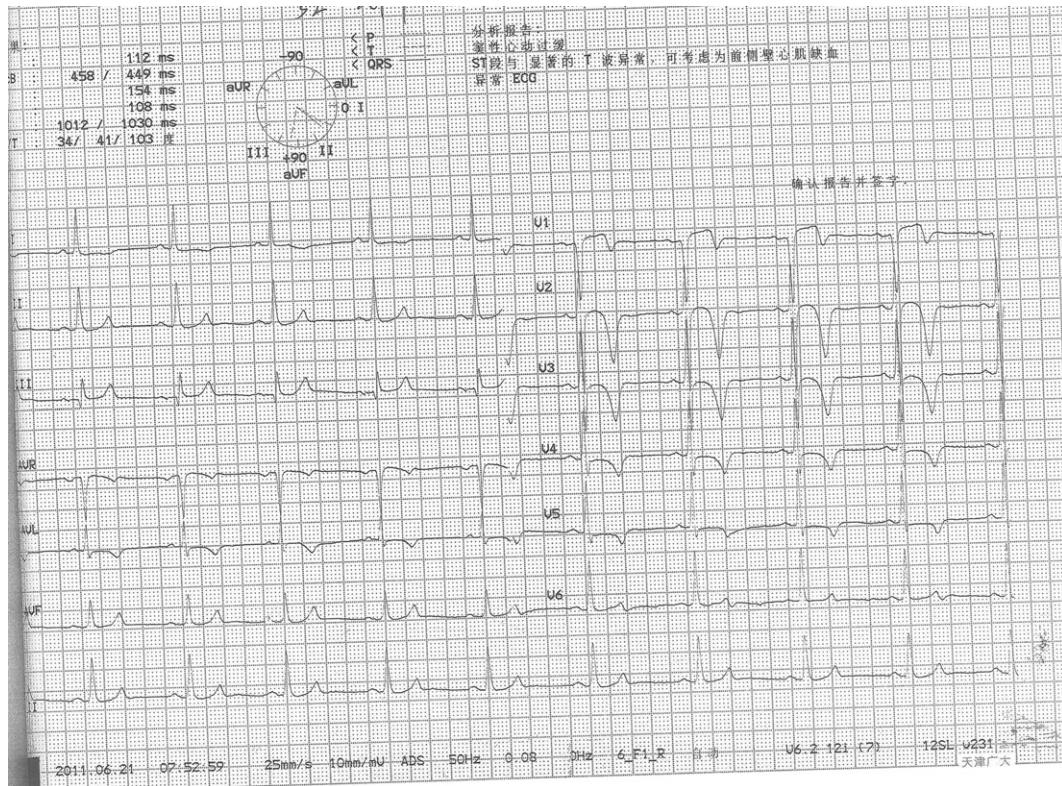


Fig. 3. ECG after the pain was relieved.

will be seen in precordial leads with inverted or biphasic T-waves. Absolute recovering of stunned myocardium results in normalized T-waves. Not only severe stenosis, any cause of coronary flow interruption, including spasm, could cause characteristic T-wave changes.<sup>4,5</sup>

Coronary artery spasm can be diagnosed if anginal attacks disappear quickly upon administration of nitroglycerin and if any 1 of the 5 criteria is met: 1) attacks appear at rest, particularly between night and early morning; 2) marked diurnal variation in exercise tolerance is observed (in particular, reduction of exercise capacity in the early morning); 3) attacks are accompanied by ST-segment elevation on electrocardiogram; 4) attacks are induced

by hyperventilation; and 5) attacks are suppressed by calcium channel blockers but not by  $\beta$ -blockers.<sup>6</sup>

Both coronary artery stenosis and spasm are the causes of angina, but sometimes, those two could come hand in hand and will make matters complicated. In our case, both LAD stenosis and spasm have been observed. But, the coronary spasm was not suspected until we finished the coronary angiography. Treatment of the patient was slightly different from classic stenosis or spasm alone. Although ECG pattern of classic Wellens' syndrome was seen in this case,  $\beta$ -blockers, widely used anti-angina agents in acute coronary events, were contradicted and unless patients not controlled by medications alone, PCI or CABG was not indicated.

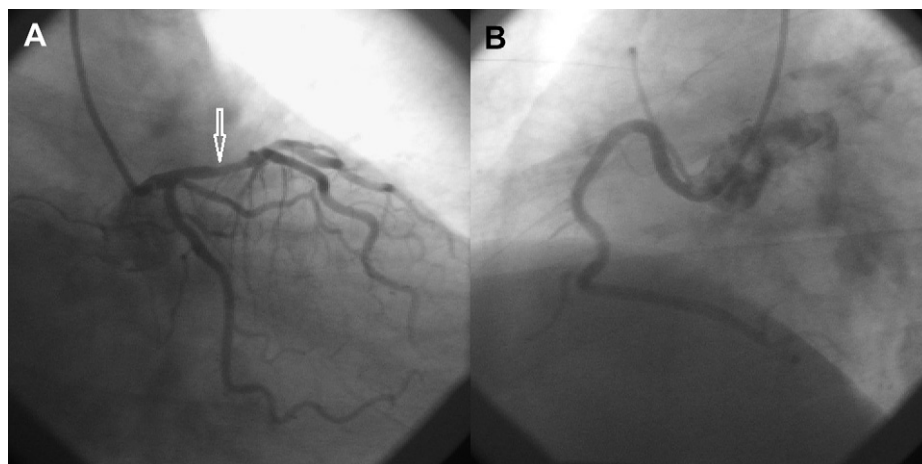


Fig. 4. A: coronary angiography (left coronary artery). Arrow indicates stenosis in LAD, B: coronary angiography (right coronary artery).

It is of great importance to recognize the ECG pattern of Wellens' syndrome and manage these patients accordingly. Our case demonstrates that the presentations of this syndrome may have some deviations from the traditional definition. We noticed that similar reports have been in publication before.<sup>4,5,7</sup> Kukla et al<sup>7</sup> described a patient with acute coronary syndrome and pseudo-Wellens' syndrome caused by coronary artery spasm. The patient reported by them was similar to our case. But, we believe, our case is the first in English literature, and the diagnosis was confirmed by coronary angiography.

### Conflicts of Interest

All authors have none to declare.

### References

1. De Zwaan C, Bar FW, Wellens HJ. Characteristic electrocardiographic pattern indicating a critical stenosis high in left anterior descending coronary artery in patients admitted because of impending myocardial infarction. *Am Heart J*. 1982;103:730–736.
2. De Zwaan C, Bar FW, Janssen JH, et al. Angiographic and clinical characteristics of patients with unstable angina showing an ECG pattern indicating critical narrowing of the proximal LAD coronary artery. *Am Heart J*. 1989;117:657–665.
3. Dhawan SS. Pseudo-Wellens' syndrome after crack cocaine use. *Can J Cardiol*. 2008;24:404.
4. Nisbet B, Zlupko G. Repeat Wellen's syndrome: case report of critical proximal left anterior descending artery restenosis. *J Emerg Med*. 2010;39:305–308.
5. Langston W, Pollack M. Pseudo-Wellens syndrome in cocaine user. *Am J Emerg Med*. 2006;24:122–123.
6. Yasue H, Nakagawa H, Itoh T, Harada E, Mizuno Y. Coronary artery spasm-clinical features, diagnosis, pathogenesis, and treatment. *J Cardiol*. 2008;51:2–17.
7. Kukla P, Korpak-Wysocka R, Dragan J, et al. Pseudo-Wellens syndrome in a patient with vasospastic angina. *Kardiol Pol*. 2011;69:79–81.