



## Clinical case report based study

## Coarctation of the aorta associated with Dandy–Walker variant

Li Zhou<sup>a,\*</sup>, George K. Lui<sup>b,c</sup>, Rajesh Shenoy<sup>b</sup>, Cynthia C. Taub<sup>c</sup><sup>a</sup> Section of Cardiology, Department of Medicine, University of Illinois at Chicago, Chicago, IL 60612, USA<sup>b</sup> Division of Pediatric Cardiology, Children's Hospital at Montefiore, Albert Einstein College of Medicine, Bronx, NY 10461, USA<sup>c</sup> Division of Cardiology, Department of Medicine, Montefiore Medical Center, Albert Einstein College of Medicine, Bronx, NY 10461, USA

## ARTICLE INFO

## Article history:

Received 18 January 2013

Accepted 30 June 2013

Available online 20 August 2013

## Keywords:

Coarctation of the aorta

Dandy–Walker variant

Hypertension

Surgical repair

Endovascular stent

## ABSTRACT

This article reports a rare case of coarctation of the aorta associated with Dandy–Walker variant in a 17-year-old girl. Differential diagnoses of coarctation of the aorta and Dandy–Walker variant are extensively discussed. In addition, standard surgical treatment of coarctation as well as new approaches such as endovascular stenting are described in detail to provide therapeutic insights into her management. Although surgical or endovascular repair of coarctation results in significant improvement of systemic hypertension and is associated with better survival, cardiovascular complications are still very common. Thus, long-term follow-up after repair is required, and high-quality imaging studies such as echocardiography, CT and MRI are warranted.

Copyright © 2013, SciBioMed.Org, Published by Reed Elsevier India Pvt. Ltd. All rights reserved.

## 1. Introduction

Coarctation of the aorta is characterized by a narrowing or constriction of the lumen of the aorta, most commonly distal to the origin of the left subclavian artery near the insertion of the ligamentum arteriosum.<sup>1</sup> It is approximately three times more common in males than females.<sup>2</sup> Clinical manifestations depend on the site and extent of the obstruction. Most patients are asymptomatic. Hypertension, discrepant blood pressure and pulses in the upper and lower extremities, and heart murmur are important findings on physical examination. Natural history of untreated aortic coarctation is poor. The life expectancy without operation is 35 years on average, with 50% of patients who die by the age of 32 years, 75% by the age of 46 years and 90% by the age of 58 years.<sup>3</sup> The usual cause of death in patients with unrepaired aortic coarctation are congestive heart failure (25.5%), aortic rupture (21%), bacterial endocarditis (18%) or intracranial hemorrhage (11.5%).<sup>3</sup> After surgical repair of aortic coarctation became available, survival has dramatically improved and the number of patients who reach adulthood is steadily increasing. Estimated survival analysis by Cohen et al revealed 91% of patients alive at 10, 84% at 20, 72% at 30 years after surgical repair.<sup>4</sup> The most common cause of late death was coronary artery disease, followed by sudden death, heart failure, cerebrovascular accident and ruptured aortic aneurysm.<sup>4–6</sup>

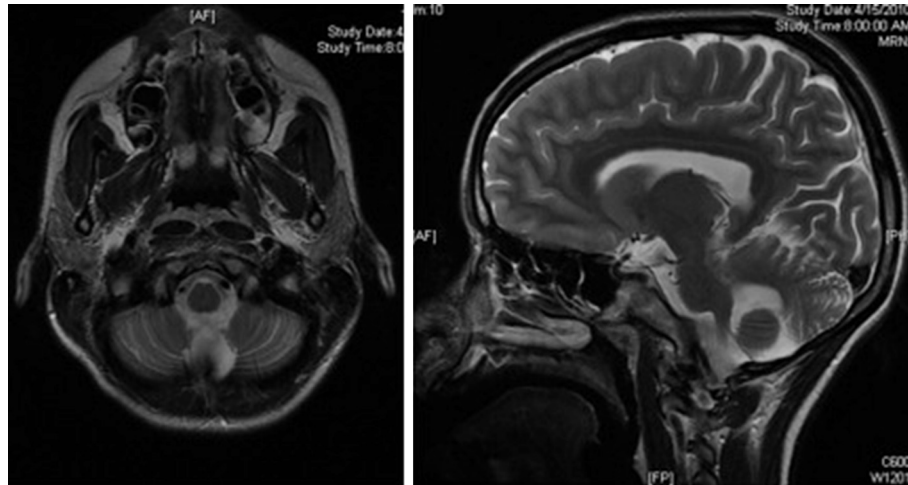
Coarctation of the aorta occurs in approximately 5–8% of patients with congenital heart disease<sup>7</sup> and is particularly frequent in patients with Turner syndrome. Coarctation of the aorta and its associated cardiac anomaly are occasionally seen in Dandy–Walker complex, a congenital disorder characterized by cystic anomalies of the posterior fossa.<sup>8,9</sup> The severity of Dandy–Walker complex is based on the size of the posterior fossa, the presence of cystic dilatation of the fourth ventricle, and the degree of vermian hypoplasia. Dandy–Walker malformation is a well-known entity featured by the presence of a large posterior fossa cyst that is continuous with the fourth ventricle, and partial or complete absence of the vermis. On the other hand, the Dandy–Walker variant is a less severe anomaly characterized by a normal-sized posterior fossa with a small cyst that communicates with the fourth ventricle and mildly hypoplastic vermis. Sasaki-Adams et al studied 24 pediatric patients with the Dandy–Walker variant (10 male and 14 female) and discovered that cardiovascular abnormalities are the most frequently associated anomaly. 10 of 24 patients (41.7%) have either patent ductus arteriosus, ventricular septal defect, atrial septal defect, transposition, hypoplastic right heart, or pulmonary artery stenosis.<sup>10</sup>

## 2. Case report

A 17-year-old girl from the Dominican Republic was referred for further evaluation of hypertension. The patient was nonverbal and had developmental delay. She was diagnosed with the

\* Corresponding author.

E-mail addresses: [zhouli@uic.edu](mailto:zhouli@uic.edu), [zhouli\\_pumc@hotmail.com](mailto:zhouli_pumc@hotmail.com) (L. Zhou).



**Fig. 1.** Axial (left) and sagittal (right) MRI images demonstrate hypoplastic inferior cerebellar vermis and midline communication between the fourth ventricle and cisterna magna, consistent with Dandy–Walker variant.

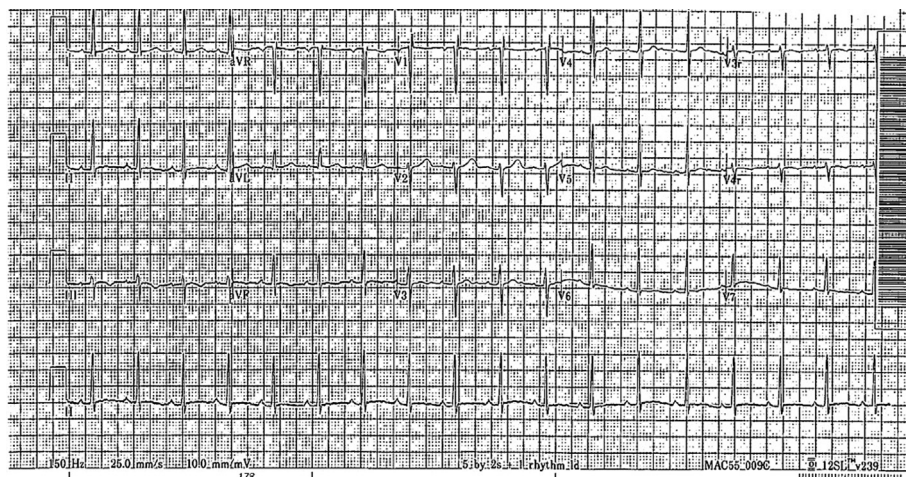
Dandy–Walker complex at age of 13, but was never previously evaluated by a neurologist. She was on risperidone 0.5 mg every night for behavioral outbursts and was brought in by her mother to pediatric neurology clinic for irritability. A magnetic resonance imaging (MRI) of brain with contrast was done (Fig. 1), showing hypoplastic inferior cerebellar vermis, and midline communicating between the fourth ventricle and cisterna magna, consistent with the Dandy–Walker variant. The posterior fossa was overall normal in size. The cerebellar hemispheres were normal. The anatomy of the brain stem was normal. There was a component of white matter volume loss posteriorly, left greater than right, which probably was secondary to a congenital vascular insult.

She was found to have an elevated blood pressure by the neurologist and was thus referred to cardiology for further evaluation and management of hypertension. On physical examination, her blood pressure was 165/89 in the left arm and 127/70 in the right leg. Other vital signs were stable. On cardiovascular examination, a grade 2/6 systolic ejection murmur was appreciated at the left sternal border. A continuous murmur was noted over her back. The femoral pulses and distal pedal pulses were not easily palpated. A 15-lead electrocardiogram was shown in Fig. 2. There was no evidence of atrial enlargement or ventricular hypertrophy. A

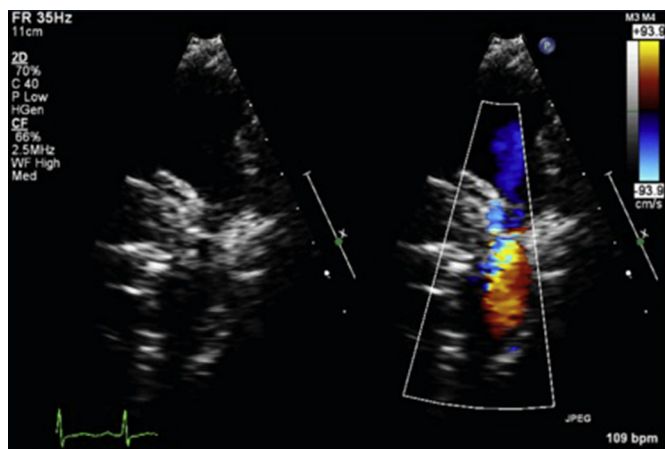
transthoracic echocardiogram revealed normal left ventricle systolic function without significant left ventricular hypertrophy or intracardiac shunts. The aortic valve appeared trileaflet. A severe coarctation was noted just beyond the origin of the left subclavian artery (Fig. 3). There was continuous antegrade flow across the descending aorta with a Doppler pattern suggestive of severe coarctation (Fig. 4).<sup>11</sup> Cardiac MRI revealed a 3 mm focal narrowing of the proximal descending thoracic aorta distal to the origin of the left subclavian artery (Fig. 5).

The patient was thus diagnosed with coarctation of the aorta and underwent successful surgical repair, which consisted of resection of the coarctation segment and interposition of a #16 Hemashied® graft.

After the surgical repair, the patient had significant post-operative hypertension, for which she was placed on an intravenous drip, and then oral amlodipine. Her systolic blood pressure improved quickly into the 110 s. She was discharged home on amlodipine 5 mg daily for her blood pressure. On her first post-operative office visit, she was normotensive on oral amlodipine, with no gradient in blood pressure between the upper and lower extremities. She was followed-up regularly in the cardiology clinic after the operation and had a repeat transthoracic echocardiogram



**Fig. 2.** 15-lead electrocardiogram showed normal sinus rhythm, normal axis, normal PR and QTc intervals, without atrial enlargement or left ventricular hypertrophy.

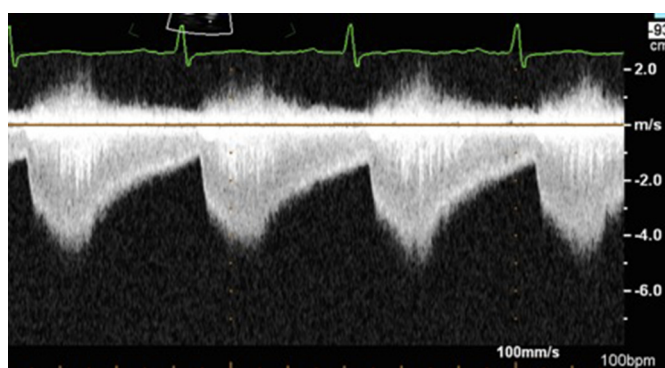


**Fig. 3.** Color Doppler image of the severe coarctation of the aorta revealed significant turbulence in the descending aorta.

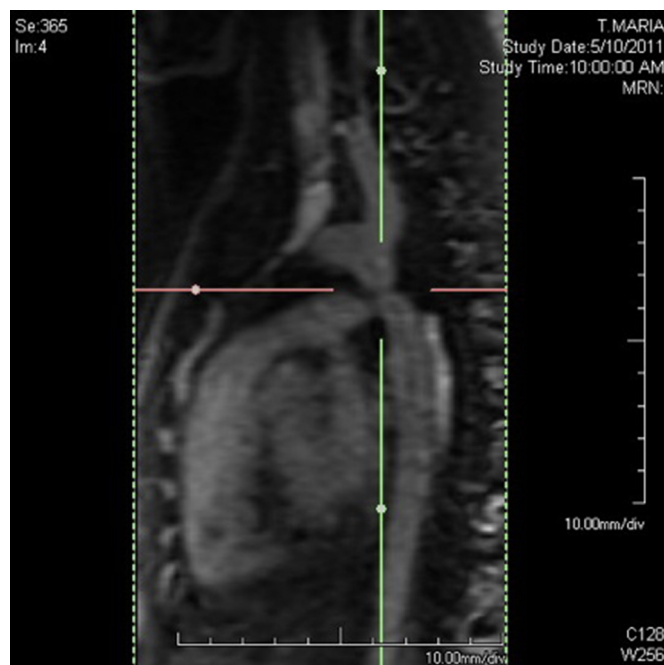
one year later. The peak flow velocity at the descending thoracic aorta returned back to normal on the continuous-wave Doppler (Fig. 6).

### 3. Discussion

Differential diagnoses of coarctation of the aorta include aortic stenosis, thoracic aortic aneurysms (TAA) and hypertrophic cardiomyopathy (HCM). Aortic stenosis is commonly seen in patients with congenital bicuspid aortic valve or acquired rheumatic or calcific aortic valve disease. It is usually detected in older adults. Most patients present with chest pain, exertional syncope or symptoms of heart failure. On physical examination, a high-pitched, mid-systolic crescendo-decrescendo murmur at right upper sternal border radiating to carotids is appreciated. Significant obstruction often causes concentric hypertrophy of the left ventricle and dilated ascending aorta. Diagnosis is beset made by echocardiography. On the other hand, the common causes of TAA are Marfan syndrome, aortic dissection, bicuspid aortic valve, hypertension, atherosclerosis, trauma, or aortitis secondary to Takayasu's, giant cell, or syphilis. Imaging studies such as echocardiography, contrast-enhanced computed tomography (CT), and MRI are helpful in making the definitive diagnosis. Occasionally, HCM is on the list of differential diagnoses as well. This disease is characterized by asymmetric left ventricle hypertrophy, typically of a nondilated chamber, without obvious cause, such as hypertension and aortic stenosis, resulting in subaortic outflow obstruction.



**Fig. 4.** Continuous-wave Doppler image across the severe coarctation of the aorta showed prominent "diastolic tail". A peak systolic velocity was measured at 4.4 m/sec.



**Fig. 5.** Cardiac MRI revealed a very short segment of focal narrowing of the proximal descending thoracic aorta distal to the origin of the left subclavian artery. The aorta in this region is measured as the following: 12 mm proximal to the narrowing, 3 mm at the level of the narrowing, and 15 mm distally.

Many patients are asymptomatic or mildly symptomatic. However, the first clinical manifestation can be catastrophic such as sudden cardiac death in children or young adults during or after physical exertion. A systolic crescendo-decrescendo murmur is often appreciated at left lower sternal border, increasing with Valsalva maneuver or standing. The mainstay of diagnosis of HCM remains to be echocardiogram.

Differential diagnoses for Dandy–Walker variant are mega cisterna magna, arachnoid cyst and vermian-cerebellar hypoplasia besides Dandy–Walker malformation, a much severer disorder characterized by a large posterior fossa cyst and partial or complete absence of the vermis. The common feature of the above mentioned disorders is a cystic malformation of the posterior fossa. Mega cisterna magna can either be asymmetric or manifest apparent mass effect, simulating the appearance of an arachnoid cyst. In the latter case, ventriculography or cisternography may be needed to demonstrate communication of the cystic mass with the subarachnoid space. In contrast, vermian-cerebellar hypoplasia describes congenital malformations with a normal-sized posterior fossa, varying degrees of vermian and cerebellar hypoplasia, and a prominent retrocerebellar cerebrospinal fluid space that communicates freely with the fourth ventricle. Due to the location of the malformations in this spectrum of disorders, MRI is the most sensitive and specific assessment tool to detect the subtle morphologic abnormalities and differentiate the diagnoses.

Surgical repair for coarctation of the aorta is the mainstay of therapeutic strategy. Different surgical techniques have been developed aiming to remove the narrowed segment and to establish unobstructed continuity between the distal aortic arch and the descending aorta. In 1945, Crafoord and Nylin first described resection with end-to-end anastomosis (EEA) to successfully repair coarctation of the aorta.<sup>12</sup> In 1966, subclavian flap aortoplasty (SFA) was introduced to correct more complex anatomical variants.<sup>13</sup> Surgical repair reduces the occurrence of subsequent hypertension.<sup>14,15</sup> But at least 20% of patients are hypertensive by adolescence,



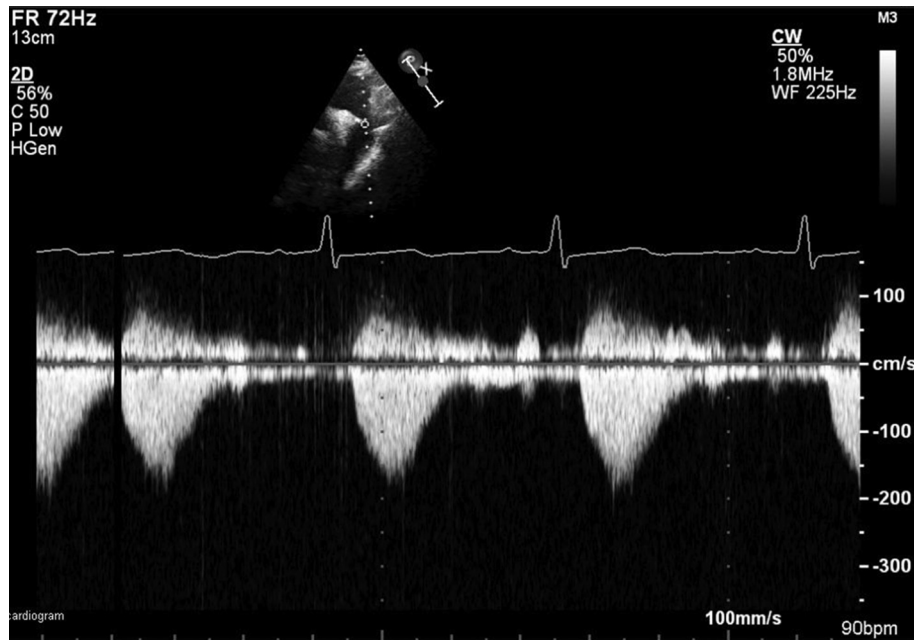


Fig. 6. Post-operative continuous-wave Doppler across the descending thoracic aorta recorded a normal peak flow velocity (<2 m/sec).

despite effective early surgical intervention.<sup>16</sup> Subsequent hypertension appears to be multifactorial due to a variety of factors, including residual or recurrent of coarctation, endothelial dysfunction, altered aortic arch morphology, aortic stiffness, altered baroreceptor reflexes, increased ventricular stiffness, and neurohumoral dysfunction.<sup>17–20</sup> The risk factors also include an older age at the time of repair and higher blood pressure before the time of repair.<sup>15,21,22</sup>

After repair of coarctation, paradoxical hypertension frequently occurs immediately post-operatively. Nitroprusside has often been used to control blood pressure in this setting.<sup>23</sup> Because hypertension after coarctation repair is often associated with elevations in catecholamines, esmolol, a short-acting beta-blocking agent, is effective in controlling blood pressure and its dose is significantly associated with percent reduction in systolic blood pressure.<sup>24</sup> Nicardipine, a dihydropyridine calcium channel antagonist, which reduces mean arterial blood pressure (MAP) with no significant changes in mean heart rate, represents another effective agent for treatment of paradoxical hypertension in children with coarctation of the aorta.<sup>23,25,26</sup> Intravenous nicardipine has been shown to be as effective as nitroprusside in treating post-operative hypertension.<sup>23</sup>

Although treatment for coarctation of the aorta is usually surgical, percutaneous catheter balloon with stent dilatation is now an alternative option for many patients. Thanopoulos et al showed that in adult patients with coarctation of the aorta, treatment with endovascular stents is a safe and effective alternative to surgical repair.<sup>27</sup> Carr compared the results of endovascular therapy (angioplasty and stenting) with surgical repair of coarctation in the adult.<sup>28</sup> It was shown that the immediate improvement in hypertension and the morbidity were similar across all groups. Surgical therapy was associated with a very low risk of restenosis (mean 2%) and recurrence, whereas endovascular therapy had a much higher incidence of restenosis (mean 11–21%) and the need for repeat intervention as the majority of aortic coarctation patients are young (mean age from 7 to 30).<sup>28</sup>

Even though surgical or endovascular repair of coarctation results in significant improvement of systemic hypertension and is associated with better survival, cardiovascular complications are still the most common causes of late death in patients with repaired coarctation of the aorta.<sup>4</sup> Thus, long-term follow-up for

surveillance of recoarctation, aortic aneurysm formation, aortic dissection, bicuspid aortic valve, endocarditis, premature coronary atherosclerosis, cerebrovascular accidents and hypertension is required, and also warrants high-quality imaging studies such as echocardiography, CT and MRI in the follow-up<sup>29</sup> in addition to rest and exercise blood pressures.<sup>4,30,31</sup>

### Conflicts of interest

All authors have none to declare.

### References

1. Fauci AS, Braunwald E, Kasper DL, et al. *Harrison's Principles of Internal Medicine*. The McGraw-Hill Companies, Inc.; 2008:1469.
2. Jenkins NP, Ward C. Coarctation of the aorta: natural history and outcome after surgical treatment. *QJM*. 1999;92:365–371.
3. Campbell M. Natural history of coarctation of the aorta. *Br Heart J*. 1970;32:633–640.
4. Cohen M, Fuster V, Steele PM, Driscoll D, McGoon DC. Coarctation of the aorta. Long-term follow-up and prediction of outcome after surgical correction. *Circulation*. 1989;80:840–845.
5. Toro-Salazar OH, Steinberger J, Thomas W, Rocchini AP, Carpenter B, Moller JH. Long-term follow-up of patients after coarctation of the aorta repair. *Am J Cardiol*. 2002;89:541–547.
6. Verheugt CL, Uiterwaal CS, Grobbee DE, Mulder BJ. Long-term prognosis of congenital heart defects: a systematic review. *Int J Cardiol*. 2008;131:25–32.
7. Hoffman JL, Kaplan S. The incidence of congenital heart disease. *J Am Coll Cardiol*. 2002;39:1890–1900.
8. Benda CE. The Dandy-Walker syndrome or the so-called atresia of the foramen Magendie. *J Neuropathol Exp Neurol*. 1954;13:14–29.
9. Akgul A, Babaroglu S, Bahar I, Bokesoy I, Birincioglu L, Cobanoglu A. An unusual combination: aortic arch coarctation associated with Dandy-Walker variant. *Int J Cardiol*. 2006;113:258–260.
10. Sasaki-Adams D, Elbabaa SK, Jewells V, Carter L, Campbell JW, Ritter AM. The Dandy-Walker variant: a case series of 24 pediatric patients and evaluation of associated anomalies, incidence of hydrocephalus, and developmental outcomes. *J Neurosurg Pediatr*. 2008;2:194–199.
11. Tan JL, Babu-Narayan SV, Henein MY, Mullen M, Li W. Doppler echocardiographic profile and indexes in the evaluation of aortic coarctation in patients before and after stenting. *J Am Coll Cardiol*. 2005;46:1045–1053.
12. Crafoord C, Nylin G. Congenital coarctation of the aorta and its surgical treatment. *J Thorac Surg*. 1945;14:347–361.
13. Waldhausen JA, Nahrwold DL. Repair of coarctation of the aorta with a sub-clavian flap. *J Thorac Cardiovasc Surg*. 1966;51:532–533.
14. Daniels SR. Repair of coarctation of the aorta and hypertension: does age matter? *Lancet*. 2001;358:89.

15. de Divitiis M, Pilla C, Kattenhorn M, et al. Vascular dysfunction after repair of coarctation of the aorta: impact of early surgery. *Circulation*. 2001;104:1165–1170.
16. O'Sullivan JJ, Derrick G, Darnell R. Prevalence of hypertension in children after early repair of coarctation of the aorta: a cohort study using casual and 24 hour blood pressure measurement. *Heart*. 2002;88:163–166.
17. Beekman RH, Katz BP, Moorehead-Steffens C, Rocchini AP. Altered baroreceptor function in children with systolic hypertension after coarctation repair. *Am J Cardiol*. 1983;52:112–117.
18. Ou P, Celermajer DS, Jolivet O, et al. Increased central aortic stiffness and left ventricular mass in normotensive young subjects after successful coarctation repair. *Am Heart J*. 2008;155:187–193.
19. Senzaki H, Iwamoto Y, Ishido H, et al. Ventricular-vascular stiffening in patients with repaired coarctation of aorta: integrated pathophysiology of hypertension. *Circulation*. 2008;118:S191–S198.
20. Tanous D, Benson LN, Horlick EM. Coarctation of the aorta: evaluation and management. *Curr Opin Cardiol*. 2009;24:509–515.
21. Daniels SR, James FW, Loggie JM, Kaplan S. Correlates of resting and maximal exercise systolic blood pressure after repair of coarctation of the aorta: a multivariable analysis. *Am Heart J*. 1987;113:349–353.
22. Brouwer RM, Erasmus ME, Ebels T, Eijgelaar A. Influence of age on survival, late hypertension, and recoarctation in elective aortic coarctation repair. Including long-term results after elective aortic coarctation repair with a follow-up from 25 to 44 years. *J Thorac Cardiovasc Surg*. 1994;108:525–531.
23. Halpern NA, Goldberg M, Neely C, et al. Postoperative hypertension: a multi-center, prospective, randomized comparison between intravenous nicardipine and sodium nitroprusside. *Crit Care Med*. 1992;20:1637–1643.
24. Wiest DB, Garner SS, Uber WE, Sade RM. Esmolol for the management of pediatric hypertension after cardiac operations. *J Thorac Cardiovasc Surg*. 1998;115:890–897.
25. Nakagawa TA, Sartori SC, Morris A, Schneider DS. Intravenous nicardipine for treatment of postcoarctectomy hypertension in children. *Pediatr Cardiol*. 2004;25:26–30.
26. Tobias JD. Nicardipine to control mean arterial pressure after cardi thoracic surgery in infants and children. *Am J Ther*. 2001;8:3–6.
27. Thanopoulos BV, Eleftherakis N, Tzanos K, Skoularigis I, Triposkiadis F. Stent implantation for adult aortic coarctation. *J Am Coll Cardiol*. 2008;52:1815–1816.
28. Carr JA. The results of catheter-based therapy compared with surgical repair of adult aortic coarctation. *J Am Coll Cardiol*. 2006;47:1101–1107.
29. Vriend JW, Mulder BJ. Late complications in patients after repair of aortic coarctation: implications for management. *Int J Cardiol*. 2005;101:399–406.
30. Bouchart F, Dubar A, Tabley A, et al. Coarctation of the aorta in adults: surgical results and long-term follow-up. *Ann Thorac Surg*. 2000;70:1483–1488 discussion 1488–1489.
31. Hauser M, Kuehn A, Wilson N. Abnormal responses for blood pressure in children and adults with surgically corrected aortic coarctation. *Cardiol Young*. 2000;10:353–357.