

Journal of Cardiovascular Disease Research

An Official Publication of SciBiolMed.Org (A publishing division of Phcog.Net)

"Our mission, Your Outstanding Research Work"

Volume 7, Issue 1, Jan-Mar, 2016

About Journal

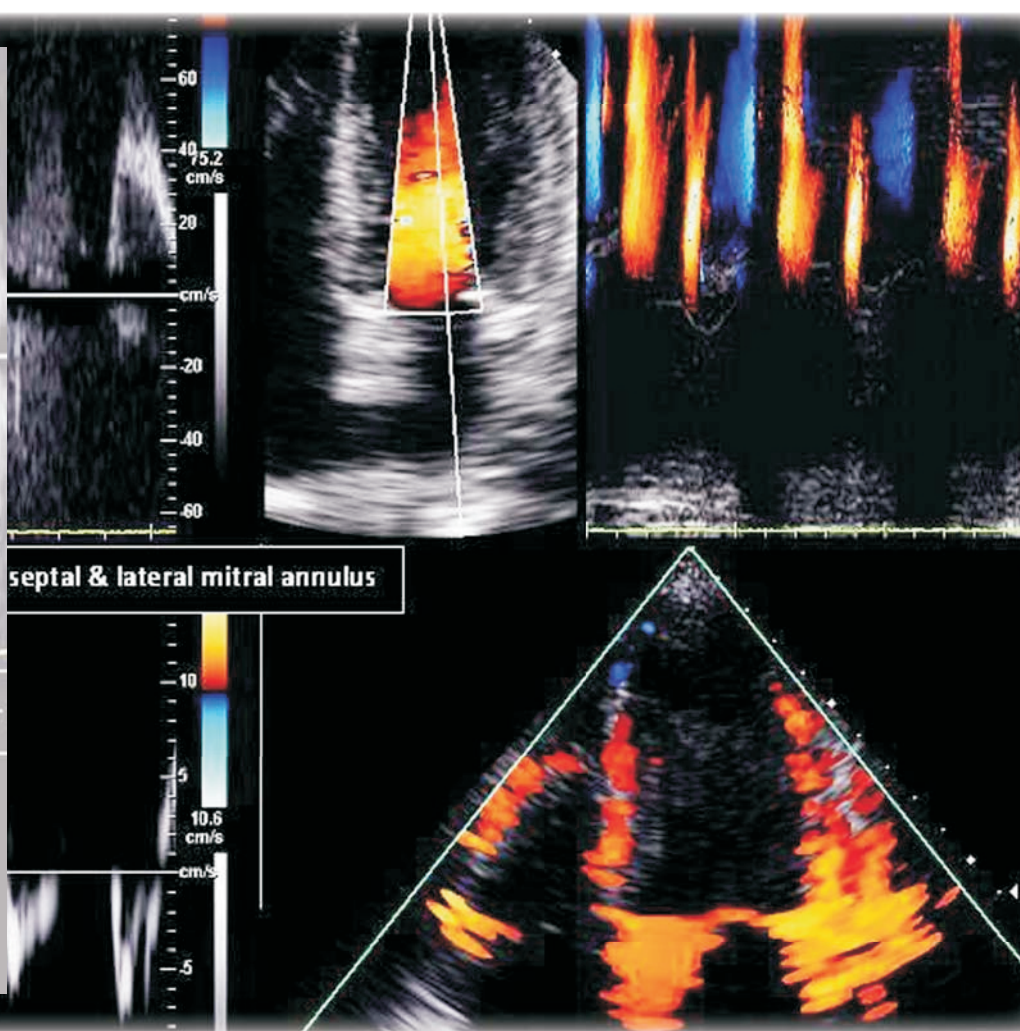
Journal of Cardiovascular Disease Research (J Cardiovasc. Dis. Res.)

[www.jcdronline.org]

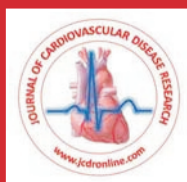[ISSN: Print -0975-3583, Online - 0976-2833]

An official publication of SciBiolMed.Org (www.scibiolmed.org);

it is a double-blind peer-reviewed, open access international circulating professional journal led by a group of research scientists, vascular disease experts and cardiologists coming from North America, Asia and Europe etc.



Indexed and Abstracted in : The journal is indexed with Caspur, Chemical Abstracts, CNKI (China National Knowledge Infrastructure), DOAJ, EBSCO Publishing's Electronic Databases, Expanded Academic ASAP, Genamics JournalSeek, Google Scholar, Health & Wellness Research Center, Health Reference Center Academic, Hinari, Index Copernicus, MANTIS, OpenJGate, PrimoCentral, ProQuest, Scimago Journal Ranking, SCOLAR, SCOPUS, SIIC databases, Summon by Serial Solutions and Ulrich's International Periodical Directory



JCDR - Providing Cutting Edge Research information on Cardiovascular Diseases

Senior International Editor: Dr. Dayi Hu
Editor : Dr. Peng Zhou

Manuscript

Hand Made Covered Coronary Stent Seals type 3 Coronary Perforation—A Life Saving Procedure When Ready to use Covered Stents are Unavailable

Venkatesh Tekur Krishnamurthy

Department of Cardiology, Apollo Hospital, Bannerghatta Road, Bangalore, Karnataka state, INDIA.

ABSTRACT

Coronary perforations are classified as type 1-extra luminal crater, type 2-myocardial or pericardial blushing, and type 3-contrast streaming or cavity spilling. Type 3 coronary perforations are associated with high mortality. Treatment modalities of Type 3 coronary perforations include prolonged balloon inflation, pericardiocentesis for cardiac tamponade, coronary artery bypass surgery, and micro coil embolization. A new technique, widely practised, consists of deploying one or more ready to use covered coronary stents to seal the perforation. This has reduced the need for emergency Coronary artery bypass surgery. The author describes here a case of coronary perforation Type 3 occurring unexpectedly after deploying a drug eluting stent across a simple mid left anterior descending artery lesion combined with a situation of non-availability of ready-to-use covered coronary stent in the catheterisation laboratory. A innovative technique of making by hand a covered coronary stent using readily available coronary balloon to cover an appropriately sized coronary stent is described. This handmade covered stent was deployed to seal the coronary perforation successfully and was life saving.

Key words: Hand Made Covered Coronary Stent, Coronary Perforation, Non-ST-Elevation Myocardial Infarction.

Key messages: Hand made covered coronary stent effectively seals Type 3 coronary perforation when ready- to- use covered coronary stents are not available, and, is life saving.

Correspondence:

Venkatesh Tekur Krishnamurthy, Department of Cardiology, Apollo Hospital, Bannerghatta Road, Bangalore 560076, Karnataka State, INDIA.

Phone no: +91 98440 75579

Submission Date: 30-9-2015; Revised date: 20-10-2015;

Accepted Date: 28-10-2015

E-mail: venkateshtekur@yahoo.com

DOI : 10.5530/jcdr.2016.1.12

INTRODUCTION

Type 3 coronary perforations are rare and are usually associated with complex lesions with high short and long-term major adverse cardiac event rates. They are recognized as serious complication after percutaneous coronary interventions, and, are associated with high morbidity and mortality.¹

Type 3 coronary perforation is defined by Ellis criteria as a perforation resulting in extravasation of blood through a frank perforation (≥ 1 mm), or spilling into an anatomic cavity.² Type 3 coronary perforation is the most serious form of perforation and is associated with the highest mortality rates ranging from 7% to 44% of cases.³ It is also associated with very high rates of cardiac tamponade (approximately 40%) and the need for emergency Coronary Artery Bypass Graft Surgery.⁴ Various modalities of treatment include prolonged balloon inflation, covered coronary stent implantation so as to seal the coronary perforation, pericardiocentesis for cardiac tamponade, micro coil embolisation, and coronary artery bypass surgery. Often a combination of these techniques is required to achieve adequate haemostasis. Newer techniques such as covered coronary stent deployment have decreased the need for emergency coronary artery bypass grafting.⁵

The Author here describes a case where a ready to use covered coronary stent was not available on the shelf of the cardiac catheterisation laboratory when a life threatening Type 3 coronary perforation occurred unexpectedly after coronary stent deployment. A coronary stent was covered with the outer covering of a low compliant coronary balloon, within about three to four minutes. This handmade covered coronary stent was deployed to effectively seal the coronary perforation and was life saving.

CASE HISTORY

A 58 year diabetic male presented with chest pain, significant ST-segment depression in anterior chest leads and elevated cardiac troponin suggestive of Non-ST Elevation Myocardial Infarction (NSTEMI). After preliminary investigations, patient had a coronary angiogram which showed single vessel coronary artery disease. There was significant concentric, non-calcified plaque with 90% stenosis in mid left anterior descending artery. After one drug eluting stent deployment to a seemingly simple mid left anterior descending lesion, coronary perforation type 3 occurred. A covered coronary stent was not available in the catheterisation laboratory immediately to seal the perforation. (Figure 1 Left). A covered coronary stent was then handmade in the catheterisation laboratory within three to four minutes by covering a 3.0×23 mm coronary stent with a 3×20 mm low compliant high burst pressure balloon. This system was prepared in the catheterization laboratory as follows:

The outer covering of a 3.0×20 mm low compliant high burst pressure balloon was carefully dissected out with a surgical blade. The outer covering of the balloon was then slipped over a 3.0×23 mm XIENCE V coronary stent and firmly hand crimped (Figure 2).

This handmade covered coronary stent system was successfully deployed across the Type 3 coronary perforation with complete sealing of the Type 3 coronary perforation with excellent result. (Figure 1 Right). Dual antiplatelet therapy with enteric-coated aspirin 150 mg and ticagrelor 90 mg BID was continued in this patient. The patient made an uneventful recovery and remained hemodynamically stable at the time of discharge from the hospital. He continues to be followed up regularly in the outpatient cardiology department. His follow-up echocardiograms and exercise tolerance tests from past 9 months show no abnormalities. He remains asymptomatic and hemodynamically stable to this day.

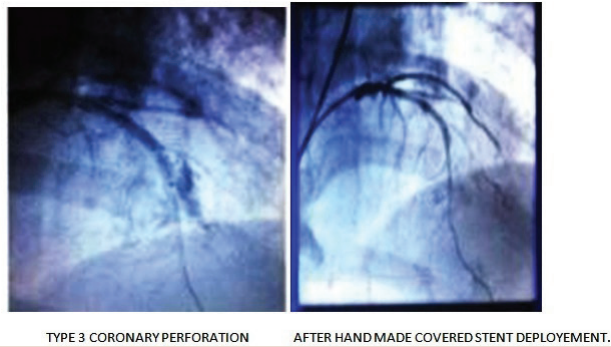
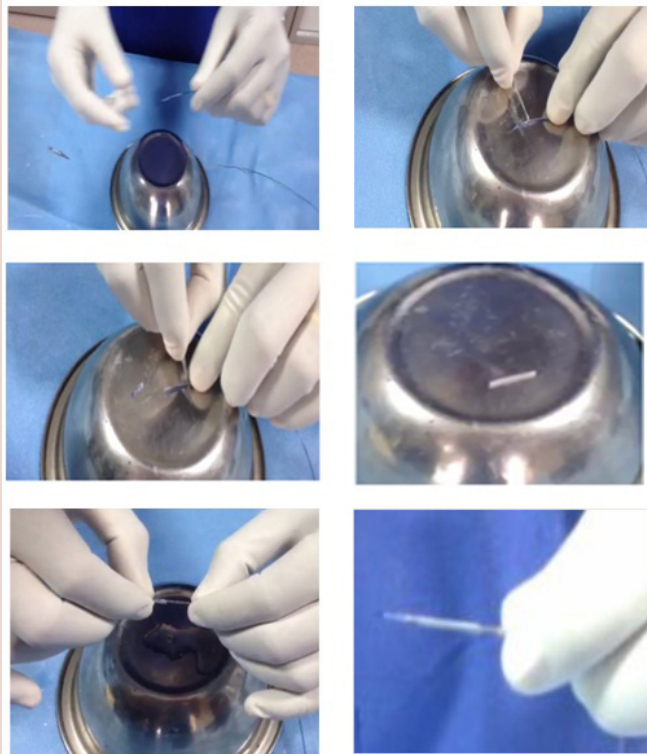


Figure 1: Left Side Image Shows Type 3 Coronary Perforation after initial Stent Deployment. Right Side Image Shows Final Result After Deployment of hand made Covered Coronary Stent to seal the Perforation



PREPERATION BY HAND OF COVERED CORONARY STENT

Figure 2: Steps in Preparing hand made Covered Coronary Stent

DISCUSSION

Type 3 coronary perforation is a feared and dramatic complication of PCI with poor immediate outcomes and very high mortality rates. It remains a rare event with an incidence of 0.23%. The predictors of Type 3 coronary perforation are complex coronary lesions, and the use of rotablation and IVUS. Various methods of treatment are available, but prolonged balloon inflation and covered coronary stent implantation are successful in a reasonable proportion of patients. Despite improvements in the treatment of grade III coronary perforation, rates of Myocardial Infarction and mortality are high.¹

However, the incidence of Type 3 coronary perforation appears to be increasing because of higher rates of PCI in complex patients and complex lesion subgroups.⁶ In a study by Rasha Al-Lamee, MA, *et al*, following perforation, immediate treatment and success rates, respectively, were: prolonged balloon inflation 58.9%, 54.5%; covered stent implantation 46.4%, 84.6%; coronary artery bypass graft surgery and surgical repair 16.0%, 44.4%; and coil embolization 1.8%, 100% 1. Multiple methods were required in 39.3%. In many centres across the world, coronary perforations are treated by covered stent implantation which are available e.g JO STENT GraftMaster [Abbot vascular Inc.], and other types. In a case report published by Bahadır Şarlı *et al*, a Type 3 coronary perforation occurred after deploying a bare metal stent to a completely occluded Right coronary artery during Primary PCI. A similar technique was used to seal the Type 3 perforation with two hand made covered stents. The patient later died due to non cardiovascular causes.⁷ The long term efficacy of such a procedure remained unknown.

An interventional cardiologist must be prepared for this iatrogenic event. Despite treatment measures, this complication is still associated with poor adverse outcomes and there remains a need for improved technology to treat this dreaded complication. In this case, a covered coronary stent was hand made in the catheterisation laboratory within three to four minutes by covering a 3.0×23 mm coronary stent with a 3.0×20 mm low compliant high burst pressure balloon as described in detail in this article. This system was successfully deployed across the Type 3 coronary perforation with excellent angiographic and clinical outcomes and saved the patients life. Continued follow-up demonstrated no adverse events in the patient proving it's safety. Hand made covered coronary stent effectively seals Type 3 coronary perforation when ready-to-use covered coronary stents are not available, and, is life saving.

CONCLUSION

Hand made covered coronary stent effectively seals Type 3 coronary perforation when ready-to-use covered coronary stents are not available, and, is life saving.

ACKNOWLEDGEMENT

Mr Samuel Sakhariya Chief Manager, Apollo Hospital Cath Lab.

REFERENCES

1. Al-Lamee R MA, Ielasi A MD; Azeem Latib MD, Cosmo Godino MD, Massimo F, Marco M MD. J Am Coll Cardiol Interv. 2011;4(1):87-95.
2. Ellis SG, Ajluni S, Arnold AZ. Increased coronary perforation in the new device era. Incidence, classification, management, and outcome. Circulation. 1994;90(6):2725-30.
3. Javadi A, Buch AN, Satler LF. Management and outcomes of coronary artery perforation during percutaneous coronary intervention. Am J Cardiol. 2006; 98(7):911-4.
4. Shimony A, Zahger D, Van Straten M. Incidence, risk factors, management and outcomes of coronary artery perforation during percutaneous coronary intervention. Am J Cardiol. 2009;104(12):1674-7.
5. Reinecke H, Fetsch T, Roeder N. Emergency coronary artery bypass grafting after failed coronary angioplasty: what has changed in a decade?. Ann Thorac Surg. 2000;70(6):1997-2003.
6. Gunning MG, Williams IL, Jewitt DE, Shah AM, Wainwright RJ, Thomas MR. Coronary artery perforation during percutaneous intervention: incidence and outcome. Heart. 2002;88(5):495-8.
7. Bahadır S, Ahmet OB, Hayrettin S, Serkan K, Yasemin D. Hüseyin Arınc Successful Treatment of Coronary Artery Perforation with Hand-Made Covered Stent. Erciyes Med J. 2013;35(3):164-6.