

A colossal atrial myxoma

Atoosheh Rohani, Vahid Akbari¹

Yasuj University of Medical Science, ¹Sajjad Hospital, Yasuj, Iran

Address for correspondence: Dr. Atoosheh Rohani, Aboozar 10, Number 26, Iran City, Yasuj, Zip Code: 7591948334, Iran. E-mail: atooshe.rohani@gmail.com

ABSTRACT

Atrial myxomas are the most common benign primary tumor of the heart. These cardiac growths can masquerade as mitral stenosis and infective endocarditis. A 35-year-old man presented with complaints of nonspecific symptoms. Echocardiogram revealed a large atrial myxoma occupying the left atrium. Excision revealed a 14 × 8 × 6 cm³ tumor attached to a 4 × 3 × 2 cm³ stalk of septal tissue. We describe a giant left atrial myxoma. We were not able to find another myxoma as big as this one in the literature, so we are reporting it.

Key words: Hypesthesia, myxomas, vertigo

DOI: 10.4103/0975-3583.70923

INTRODUCTION

The first description of a primary intracardiac tumor was in 1559, located in the left ventricle.^[1] Atrial myxomas are the most common benign primary tumor of the heart and occur in as many as 3 in 1000 patients.^[2] Most cases of atrial myxoma are sporadic, and the exact etiology is unknown. Myxomas account for 40–50% of primary cardiac tumors. Approximately 90% are solitary and pedunculated, and 75–85% occurs in the left atrial cavity.^[3,4] Because of nonspecific symptoms, early diagnosis may be a challenge. We present the case of a 35-year-old man with a large atrial myxoma, who presented with complaints of nonspecific symptoms and who was found to have a grade 2/6 systolic murmur.

CASE REPORT

A 35-year-old man was referred to our cardiology clinic due to his nonspecific symptoms such as atypical chest pain, numbness in his left hand, palpitation, and dizziness (not positional). He did not complain of any constitutional symptoms. He did not have any previous medical problem; there was no history of peripheral or pulmonary embolization. The patient had no prior history of heart murmurs, syncope, and shortness of breath.

Findings on physical examination were: normal sinus

rhythm, at the rate of 84 per minute and blood pressure 124/84mmHg. Jugular venous pressure was normal, and basilar pulmonary rales was heard. On heart auscultation, there was a loud S₁, a grade 2/6 holosystolic high-pitched murmur at the apex with radiation to the left axilla. There was also an early diastolic sound, now we know it was tumor plop. The remainder of the physical examination was unremarkable.

Laboratory data included a normal hemogram, urinalysis, and electrolytes. Erythrocyte sedimentation rate (ESR) and C-reactive protein levels were elevated.

Liver function and coagulation tests were normal. Chest roentgenogram showed mild cardiomegaly, electrocardiogram was abnormal due to left axis deviation, left atrial enlargement, and PR interval was 240 ms.

Two-dimensional echocardiography was done and a huge mobile LA mass with a stalk that protrude in LV during systole was appeared, it caused severe eccentric jet of MR [Figure 1]. Then, patient underwent transesophageal echocardiography [Figure 2].

It revealed a huge mass was attached to interatrial septum and severe MR. Patient was referred to a cardiac surgeon. An emergency operation was performed after the diagnosis. The left atrium was incised along the interatrial groove to

find a huge myxoma occupying most of the left atrium, with a part of it incarcerated into the left ventricle. Its stalk was attached to the inferior edge of the fossa ovalis. A part of the atrial septum, where the stalk of the myxoma was attached, was excised along with the huge myxoma. The atrial septal defect was closed with a pericardial patch. A yellowish gelatinous mass with a lobulated surface was removed. Prolapsed of a tumor through the mitral valve resulted in the destruction of the annulus. Mitral valve was repaired (by ring annuloplasty).

Histologic findings

Its size was $14 \times 8 \times 6 \text{ cm}^3$ and weight was 458 g [Figures 3 and 4]. Microscopic examination showed stellate-shaped in a vascular myxoid stroma. The cells are polygonal with scant eosinophilic cytoplasm.

Tumor necrosis is present. Immunohistochemical expression showed of interleukin-6, but had no abnormal DNA content.

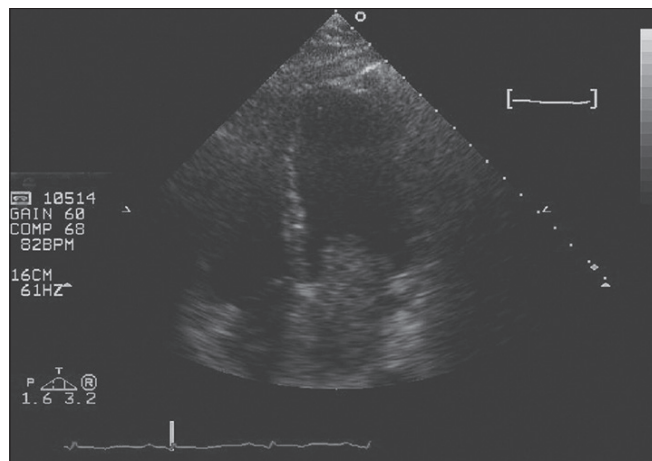


Figure 1: Large LA myxoma

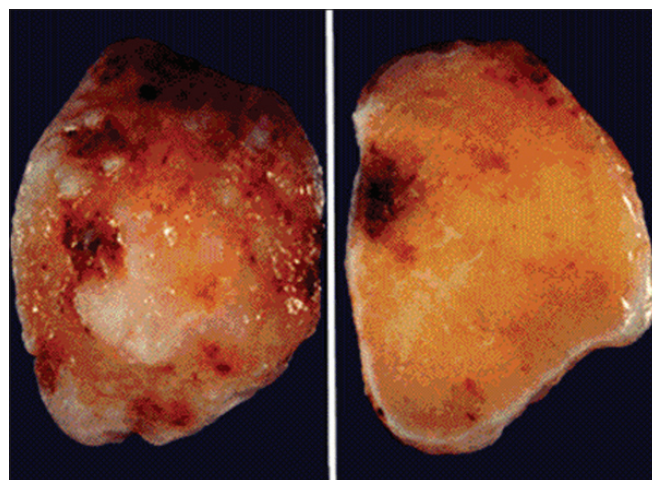


Figure 3: Yellowish mass excised

DISCUSSION

Prior to 1951, the diagnosis of intracardiac tumors was made only at postmortem examination; in that year the diagnosis of a left atrial tumor was confirmed by angiocardiology.^[5] Chest radiograph may reveal left atrial enlargement and signs of pulmonary hypertension and congestion. Transthoracic two-dimensional echocardiography and if necessary the transesophageal approach can be used to determine the location, size, shape, point of attachment, and motion characteristics of a myxoma. The latter investigation is particularly helpful for precise delineation of tumor size, number, and attachments. Our patient failed to present with the common symptoms associated with atrial myxoma including dyspnea, orthopnea, peripheral embolism, or syncope. Above clinical manifestations can occur separately or simultaneously, and can be either symptomatic or asymptomatic depending on the extent of the tumor growth, and we think that our patient's tumor must be slow growth because of patient was oligosymptomatic, with recent initiation of palpitation and mild precordialgia. In addition, an obstruction of the mitral valve outflow by the tumor is often related to the patient's posture, and because our patient's job was bus driver and he was in upright posture all of the time, he did not have dyspnea. In this study, we found a case that was difficult to diagnose, due to the small amount of signs and symptoms.

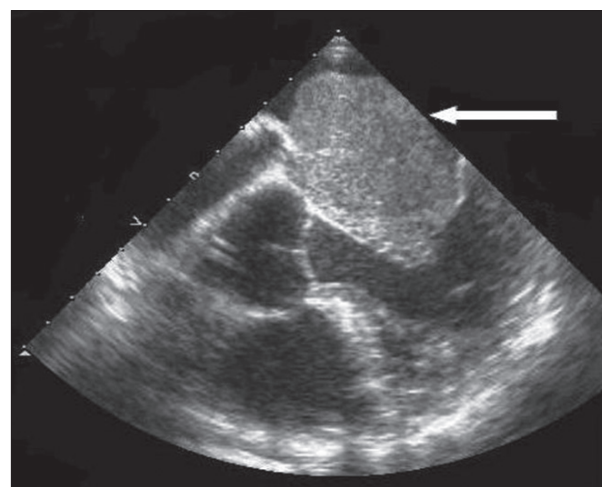


Figure 2: Transesophageal echo

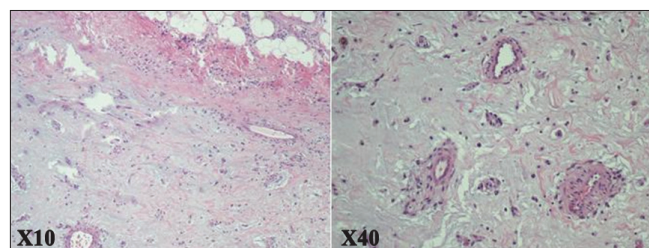


Figure 4: Histological section of atrial myxoma

The patient underwent surgery (without complications) and an anatomic-pathological study confirmed that it was myxoma.

CONCLUSION

This patient did not present with the common symptoms associated with an atrial myxoma. Although atrial myxomas are usually benign or asymptomatic, there is the possibility of diastolic embolization,^[2,3] conduction alterations and disturbances,^[4] and lethal valve obstructions occurring.^[6] Since surgical excision has been reported to alleviate symptoms associated with cardiac myxomas, early identification and removal are preferable. We recommend echocardiogram in the workup of atypical chest pain and vertigo of unknown etiology; we hope to facilitate earlier identification of these intracardiac growths.

REFERENCES

1. Wilcox BR, Carter JM. Left ventricular myxoma: Case report of successful removal. *Ann Surg* 1971;173:131-4.
2. Hicks KA, Kovach JA, Frishberg DP, Wiley TM, Gurczak PB, Vernalis MN. Echocardiographic evaluation of papillary fibroelastoma: A case report and review of the literature. *J Am Soc Echocardiogr* 1996;9:353-60.
3. Bjessmo S, Ivert T. Cardiac myxoma: 40 years' experience in 63 patients. *Ann Thorac Surg* 1997;63:697-700.
4. Centofanti P, Di Rosa E, Deorsola L, Dato GM, Patanè F, La Torre M, *et al*. Primary cardiac tumors: Early and late results of surgical treatment in 91 patients. *Ann Thorac Surg* 1999;68:1236-41.
5. Goldberg HP, Glenn F, Dotter CT, Steinberg I. Myxoma of the left atrium: Diagnosis made during life with operative and post-mortem findings. *Circulation* 1952;6:762-7.
6. Salcedo EE, Cohen GI, White RD, Davison MB. Cardiac tumors: Diagnosis and management. *Curr Probl Cardiol* 1992;17:73-137.

Source of Support: Nil, Conflict of Interest: None declared.

Advertisement



CENTRE FOR GLOBAL
HEALTH RESEARCH

Do you wish to contribute to better medical statistics in India?

We seek physicians [MBBS/Diploma/MD/MS/DNB] in any specialty (medical/surgical) to join our unique "Million death study" (MDS) which provides mortality statistics for India. You will be one of 400 skilled physicians, who will be coding the causes of deaths across India. The MDS is run by the CGHR India Foundation; New Delhi (www.cghr.org) affiliated with the St. Michael's Hospital at University of Toronto and St John's Research Institute in Bangalore (www.sjri.res.in) for the Office of the Registrar General of India, Government of

India. The study will improve knowledge of causes of deaths in India.

Empanelled physicians will be responsible for web-based review and coding of mortality reports. Requirements include (i) fluency in any Indian language/s, (ii) ability to use computers, (iii) secure access to high-speed internet for 8-15 hours of work per week (working hours are flexible), and (iv) 3-5 days training (TA/DA reimbursed) including assessment of your coding ability since we only want the best coding physicians.

For your consequent contribution, the payment is based on the records coded with partial reimbursement of internet usage cost. Those who complete a full year of service at high quality will receive a certificate from SJRI/CGHR.

Interested physicians may apply through <http://www.surveymonkey.com/s/CGHRdoctors> by 31 October 2010 (extended deadline date) but only qualified applicants will be asked to apply further. For more details about our research, please visit www.cghr.org/publications.htm. Should you have further questions, email cghrbglr@smh.ca. For more details about us, please visit <http://www.cghr.org/mds>.



CENTRE FOR GLOBAL HEALTH RESEARCH
Li Ka Shing Knowledge Institute, Keenan Research Centre
70 Richmond Street East, Suite 202A
Toronto, Ontario M5C 1N8, Canada
Tel: +1 416.864.6042 Fax: +1 416.864.5256
www.cghr.org

